

## Chest Wall Distant Metastases of Thyroid Carcinoma

### Tiroid Kanserinin Göğüs Duvarına Uzak Metastazları

Yekta Altemur KARAMUSTAFAOĞLU, Yener YÖRÜK, Güngör ANGIN,<sup>1</sup> Taner TARLADAÇALIŞIR, Rüstem MAMMEDOV

Department of Thoracic Surgery, Medical Faculty of Trakya University, Edirne;

<sup>1</sup>Department of Thoracic Surgery, Selimiye State Hospital, Edirne

Submitted / Başvuru tarihi: 09.10.2008 Accepted / Kabul tarihi: 12.11.2008

**Objectives:** Carcinoma of the thyroid gland is the most common malignancy of the endocrine system although the annual incidence of thyroid cancer varies considerably in different registries, ranging from 2-4 per 100,000 individuals. The purpose of this study was to review clinical characteristics of the patients with chest wall metastasis originating from thyroid cancer.

**Patients and Methods:** Between December 2000 and November 2007, four patients with thyroid cancer were diagnosed with chest wall mass at our hospital. There were one male (25%) and three females (75%) with a mean age of 58 years (range 47-70 years). All patients were admitted with chest pain and swelling in invading chest wall. Their clinical characteristics were analyzed retrospectively. The tumor was resected together with chest wall in all patients. Incidence of chest wall metastasis from papillary thyroid cancer was three patients and one patient from medullary thyroid cancer. The chest wall distant metastasis was synchronous in two patients and metachronous in two patients. Large defects were reconstructed with appropriate tissues, the material used was polytetrafluoroethylene (PTFE) mesh in two patients. Radioiodine ablation therapy was carried out in three patients, except for one medullary carcinoma patient.

**Results:** Two papillary carcinoma patients died in five and 36 months, medullary carcinoma patient died in 24 months due to distant metastasis resulting from thyroid cancer. One patient is alive and well after five years following surgery.

**Conclusion:** The surgical removal of distant metastases from differentiated thyroid carcinoma (papillary and follicular) offers the best chance for prolonged survival and improved quality of life.

**Key words:** Thyroid neoplasm; thoracic wall; neoplasm metastasis.

**Amaç:** Tiroid bezi kanseri endokrin sistem kanserleri içinde en sık görülen maligniteler olmasına rağmen, tiroid kanserinin yıllık sıklığı bölgeden bölgeye önemli ölçüde, 100 000'de 2-4 arasında değişmektedir. Bu çalışmanın amacı, tiroid bezin kanserinden kaynaklanan göğüs duvarı metastazı olan hastaların klinik karakteristiklerini incelemektir.

**Hastalar ve Yöntemler:** Aralık 2000 - Kasım 2007 tarihleri arasında, dört hastaya tiroid kanserinin göğüs duvarına metastazı tanısı konuldu. Olguların biri erkek (%25), üçü kadın (%75), ortalama yaşları 58 (dağılım 47-70) idi. Tüm hastalar göğüs duvarında ağrı ve şişlik ile başvurular. Tüm hastalarda tümör ile birlikte göğüs duvarı rezeksiyonu uygulandı. Olguların klinik özellikleri retrospektif olarak analiz edildi. Göğüs duvarına metastaz bir olguda medüller tiroid karsinomu ve üç olguda ise papiller tiroid karsinomu nedeniyleydi. Göğüs duvarı metastazları iki olguda senkron iken iki olguda metakron metastazdı. Göğüs duvarı rezeksiyonundan sonra oluşan geniş defektler iki olguda çevre dokuların yardımı ile kapatılırken iki olguda politetrafloroetilen (PTFE) greft ile kapatıldı. Medüller tiroid kanserli olgu hariç, diğer üç olguda cerrahi tedavinin devamında radyoyot ablasyon tedavisi uygulandı.

**Bulgular:** İki papiller tiroid kanseri olgusu beşinci ve 36. aylarda, medüller tiroid kanseri olan bir hasta 24. ayda tiroid kanserinin uzak metastazı nedeni ile öldü. Bir hasta ise cerrahiden sonra beşinci yılında halen sağ ve sağlıklıdır.

**Sonuç:** Differansiye tiroid kanserlerinde (papiller ve foliküler) uzak metastazların kaldırılması sağkalımın uzaması ve hayat kalitesinin artırılması nedeniyle önerilmektedir.

**Anahtar sözcükler:** Tiroid neoplazmi; göğüs duvarı; neoplazm metastazı.

Although carcinoma of the thyroid gland is an uncommon disorder, it is the most common malignancy of the endocrine system.<sup>[1]</sup> The annual incidence of thyroid cancer varies considerably in different registries, ranging from 2-4 per 100,000 individuals. Differentiated tumors (papillary or follicular) are highly treatable and usually curable. Poorly differentiated tumors (medullary or anaplastic) are less common, are aggressive, metastasize early, and have a poorer prognosis. Bone is the second most frequent site of metastasis resulting from thyroid cancer. Many studies have investigated clinical features and prognostic factors of distant metastasis stemming from thyroid cancer. The purpose of this study was to review clinical characteristics of the patients with chest wall metastasis originating from thyroid cancer.

### PATIENTS AND METHODS

Between December 2000 and November 2007, four patients with thyroid cancer were diagnosed with chest wall tumors at our hospital. Their clinical characteristics were analyzed retrospectively. There were one male (25%) and three females (75%) with a mean age of 58 years (range 47-70 years). All patients were admitted with chest pain and swelling in invading chest wall. Near-total or total thyroidectomy had been performed in two patients 10 years and 20 years before, respectively. Preoperative evaluation included physical examination, hematological and biochemical investigation, chest X ray, electrocardiogram (ECG), computerized tomography (CT) of the chest and abdomen, and bone scan were performed. Scanning showed no distant metastasis except of chest wall. Thorax CT and bone scan revealed chest wall mass including costal invasion (left lateral 4th rib in one patient, left anterior 5, 6th ribs in one patient, right posterior 8th rib in one patient and manubrium sterni with clavicle in one patient).

### RESULTS

The tumor was resected together with the chest wall, affected ribs, immediately above and below the healthy rib as well as 4 cm of the surrounding healthy tissue including any attached structures (Fig. 1). The resection included three ribs in

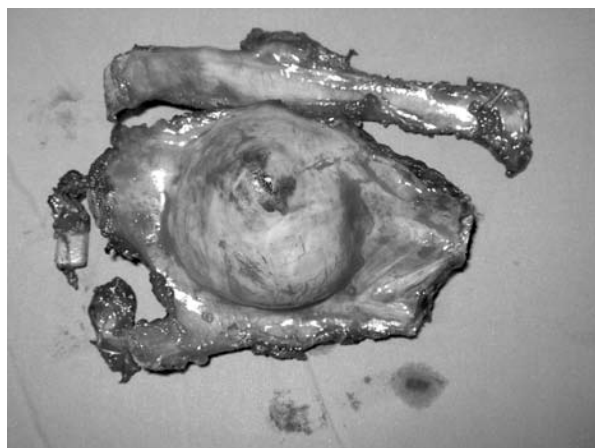


Fig. 1. Resection of chest wall with tumor tissue.

two patients, one rib in one patient, partial manubrium sterni and the head of clavicle in one patient. No macroscopic tumor tissue was left after resection and pathology margins were disease-free in all four patients. Histopathological examination of the chest wall resection materials revealed papillary thyroid cancer in three patients and medullary thyroid cancer in one patient. One patient underwent complementary thyroidectomy during chest wall surgery due to pathology revealing metastatic carcinoma of the thyroid. Large defects were reconstructed with appropriate tissues, the material used was polytetrafluoroethylene (PTFE) mesh in two patients (Fig. 2, Table 1).

Radioiodine ablation therapy was carried out in three patients, except for one medullary carcinoma patient. One synchronous papillary



Fig. 2. Large defect reconstructed with polytetrafluoroethylene (PTFE) mesh.

**Table 1. Resection, reconstruction and adjuvant therapy**

No	Age	Gender	Localization	Interval	Pathological examination
1	47	Female	Left lateral portion of 4th rib	After 10 years	Papillary carcinoma
2	65	Female	Manubrium sterni and clavicle	After 20 years	Papillary carcinoma
3	50	Male	Left anterior chondrium of the 5, 6th ribs	Synchronous	Papillary carcinoma
4	70	Female	Right posterior portion of the 8th rib	Synchronous	Medullary carcinoma

carcinoma patient had undergone total thyroidectomy in another center. One synchronous papillary carcinoma patient had undergone total thyroidectomy before radioablation therapy and complementary thyroidectomy was performed in one metachronous patient. There were no early or late mortality related to either resection or reconstruction of the chest wall. All patients recovered uneventfully. Two papillary carcinoma patients died in five and 36 months, medullary carcinoma patient died in 24 months after adjuvant therapy for distant metastasis resulting from thyroid cancer. One patient is alive and well after five years of follow-up.

### DISCUSSION

The thyroid cancer presenting with distant metastases in the chest wall is uncommon and when present, is usually found in flat bones. Papillary or follicular thyroid carcinomas are highly treatable and usually curable tumors. Medullary or anaplastic thyroid carcinoma are much less common, are aggressive, metastasize early, and have poorer prognosis. The incidence of this malignancy has been increasing over the last decade.<sup>[2]</sup> Diffuse, intense immunostaining for vascular endothelial growth factor in patients with papillary cancer has been associated with a high rate of local recurrence and distant metastases.<sup>[3]</sup> If the tumor clinically appears to be malignant, particularly if it is malign frozen section examination, a primary radical resection should be performed, surgical resection must include not only the affected bone but also at least one uninvolved rib and intercostal bundle above and below the tumor mass, together with a wide portion of any adjacent involved tissue.<sup>[4]</sup> Chest wall resection should not be compromised and limited unless the patients will be incapable of tolerating the procedure. Large defects should

be reconstructed with appropriate tissues, but the respiratory mechanism should also be preserved and functional limitations minimized. The materials used by chest wall reconstruction are polypropylene (Marlex) or polytetrafluoroethylene (PTFE) mesh.<sup>[4]</sup> Generally, small and posterior defects of the chest wall do not require reconstruction. Papillary carcinoma of the thyroid rarely manifests itself as a distant metastatic lesion, and, when present, is usually found in flat bones. Do et al.<sup>[5]</sup> reported 0.4% (13 of 3,154 patients) incidence of bone metastasis from papillary thyroid cancer. Survival rates between the synchronous and metachronous metastasis groups were not significantly different, and the number of metastasis sites did not affect survival.<sup>[5]</sup> A synchronous metastasis to the bone and soft tissue is very rare so far. Haq and Harmer<sup>[6]</sup> reported 24% incidence of bone metastasis for differentiated thyroid carcinoma.<sup>[6]</sup> Despite sternal metastasis, chest wall metastases are very rare.<sup>[7-9]</sup> Studies have shown that a postoperative course of therapeutic (ablative) doses of radioiodine results in a decreased recurrence rate among high-risk patients with papillary and follicular carcinomas.<sup>[7,10]</sup> So complementary total thyroidectomy must be applied if not performed prior to radioablation in metachronous metastatic patients. The median follow-up of living patients was 3.9 years (0.3-48) with a 10-year cause-specific survival rate of 31% with distant metastasis.<sup>[6]</sup>

In conclusion, the surgical removal of distant metastasis from differentiated thyroid carcinoma (papillary and follicular) offers the best chance for prolonged survival and improved quality of life. Furthermore, the surgical removal of a resectable skeletal metastasis can be a valuable complement to radioiodine therapy. Radioactive iodine therapy is not used to treat anaplastic

(undifferentiated) and medullary thyroid carcinomas because cancer types of cancer do not take up iodine.

### REFERENCES

1. Hundahl SA, Fleming ID, Fremgen AM, Menck HR. A National Cancer Data Base report on 53,856 cases of thyroid carcinoma treated in the U.S., 1985-1995. *Cancer* 1998;83:2638-48.
2. Tennvall J, Biörklund A, Möller T, Ranstam J, Akerman M. Is the EORTC prognostic index of thyroid cancer valid in differentiated thyroid carcinoma? Retrospective multivariate analysis of differentiated thyroid carcinoma with long follow-up. *Cancer* 1986;57:1405-14.
3. Lennard CM, Patel A, Wilson J, Reinhardt B, Tuman C, Fenton C, et al. Intensity of vascular endothelial growth factor expression is associated with increased risk of recurrence and decreased disease-free survival in papillary thyroid cancer. *Surgery* 2001;129:552-8.
4. Grosfeld JL, Rescorla FJ, West KW, Vane DW, DeRosa GP, Provisor AJ, et al. Chest wall resection and reconstruction for malignant conditions in childhood. *J Pediatr Surg* 1988;23:667-73.
5. Do MY, Rhee Y, Kim DJ, Kim CS, Nam KH, Ahn CW, et al. Clinical features of bone metastases resulting from thyroid cancer: a review of 28 patients over a 20-year period. *Endocr J* 2005;52:701-7.
6. Haq M, Harmer C. Differentiated thyroid carcinoma with distant metastases at presentation: prognostic factors and outcome. *Clin Endocrinol (Oxf)* 2005;63:87-93.
7. Mishra A, Mishra SK, Agarwal A, Agarwal G, Agarwal SK. Surgical treatment of sternal metastases from thyroid carcinoma: report of two cases. *Surg Today* 2001;31:799-802.
8. Haraguchi S, Yamashita Y, Yamashita K, Hioki M, Matsumoto K, Shimizu K. Sternal resection for metastasis from thyroid carcinoma and reconstruction with the sandwiched Marlex and stainless steel mesh. *Jpn J Thorac Cardiovasc Surg* 2004;52:209-12.
9. Meyer A, Behrend M. Partial resection of the sternum for osseous metastasis of differentiated thyroid cancer: case report. *Anticancer Res* 2005;25(6C):4389-92.
10. Mazzaferri EL, Jhiang SM. Long-term impact of initial surgical and medical therapy on papillary and follicular thyroid cancer. *Am J Med* 1994;97:418-28.