

## How Reliable is the Safe Zone of Hardinge Approach for Superior Gluteal Nerve?

*Hardinge Yaklaşımındaki Safe Zone Superior Gluteal Sinir İçin Ne Kadar Güvenilir?*

Murat BÜLBÜL, Semih AYANOĞLU, Kahraman ÖZTÜRK, Yunus İMREN,  
Cem ESENYEL, Rıdvan YEŞİLTEPE, Hakan GÜRBÜZ

*Department of Orthopedics and Traumatology, Vakıf Gureba Training and Research Hospital, İstanbul*

**Submitted / Başvuru tarihi:** 22.09.2008 **Accepted / Kabul tarihi:** 20.10.2008

**Objectives:** Anterolateral Hardinge approach is one of the most common approaches used for total hip arthroplasty. Superior gluteal nerve is the main motor nerve of abductor mechanism of gluteus medius and tensor fascia lata muscles, where the injury to this nerve manifests itself as Trendelenburg's sign. In order to prevent the occurrence of this sign, a concept was developed called as "safe zone", where no superior gluteal nerve exists. Our aim was to evaluate the reliability of the concept of safe zone as previously described by many authors in Hardinge approach.

**Patients and Methods:** Nineteen hips of 10 fresh cadavers were evaluated in this study. We measured the distance between 1/3 anterior of greater trochanter of femur and superior gluteal nerve.

**Results:** We detected the distance between 1/3 anterior of greater trochanter of femur and superior gluteal nerve to be 4.4 cm. The mean value of distance we observed in our study was smaller than that reported in literature by various authors.

**Conclusion:** We have detected that in cases where total hip arthroplasty will be performed through Hardinge incision, the area defined as safe zone was shorter than that described by various authors as 5 cm. We concluded that safe zone concept of 5 cm should not be relied on in cases where Hardinge approach is used.

**Key words:** Hardinge approach; safe zone; M. gluteus medius; superior gluteal nerve.

**Amaç:** Anterolateral Hardinge yaklaşımı kalça artroplastisinde en sık kullanılan yaklaşımlardan biridir. Superior gluteal sinir, gluteus medius ve tensor fasya lata'nın abduktör mekanizmasının esas motor siniridir. Bu sinirin hasarlanması durumunda Trendelenburg belirtisi saptanmaktadır. Trendelenburg belirtisine maruz kalınmaması için "safe zone" denen kavram geliştirilmiştir. Safe zone diye adlandırılan bölgenin içinde superior gluteal sinir yoktur. Hardinge yaklaşımında çeşitli yazarlarca tariflenen safe zone kavramının güvenilirliğini değerlendirmeyi amaçladık.

**Hastalar ve Yöntemler:** Çalışmamızı 10 taze kadavranın 19 kalçasında yaptık. Trokanter major'un (1/3 ön tarafındaki noktadan) superior gluteal sinire olan uzaklıklarını değerlendirdik.

**Bulgular:** Trochanter major'ün 1/3 ön bölümüyle superior gluteal sinir arasındaki mesafeyi ortalama 4.4 mm olarak tespit ettik. Çalışmamızda bulduğumuz ortalama değer, daha önce değişik yazarlarca bildirilen değerlerden daha küçük olarak bulundu.

**Sonuç:** Hardinge insizyonu ile total kalça artroplastisi yapılacak olgularda, safe zone olarak tanımlanan alanın çeşitli yazarlarca bildirilen 5 cm'nin altında olduğunu tespit ettik. Bu yaklaşımın kullanıldığı olgularda 5 cm'lik safe zone kavramına çok fazla güvenmememiz gerektiği sonucuna vardık.

**Anahtar sözcükler:** Hardinge yaklaşımı; safe zone; M. gluteus medius; superior gluteal sinir.

Anterolateral approach was described by Watson-Jones in 1936. McFarland and Osborn modified the direct lateral approach in 1954. Finally revised by Hardinge in 1982, this approach is now considered as one of the most commonly used techniques in total hip arthroplasty cases.

In his description of approach, Hardinge stated that proximal margin could extend from the anterior one third of greater trochanter to its above 5 cm, and he named the area between them as safe zone.<sup>[1-3]</sup>

In our study, we aimed to investigate the degree of reliability of the so-described safe zone, as also acknowledged by various authors.

### PATIENTS AND METHODS

Nineteen hips of 10 fresh adult cadavers were incised through Hardinge approach. Anterior one third of greater trochanter was determined, and it was followed in both proximal and distal directions to terminate as splitting of muscle attachment site. In deep layer at proximal portion, superior gluteal nerve (SGN) was localized. Then, the distance from the described point on the greater trochanter to the SGN was measured.

### RESULTS

All cadavers were dissected by same team of researchers. Superior gluteal nerve was identified carefully (Fig. 1). The described distance was detected to be 39-70 mm, where the mean value was calculated as 4.4 cm (Table 1).

### DISCUSSION

Direct lateral approach of Hardinge K. is one of the most commonly used techniques for total hip arthroplasty.<sup>[1,3,4]</sup> The major complication that might occur in this approach is injury of SGN. The association between the injury to this nerve and the type of incision was assessed by many authors.<sup>[5-9]</sup>

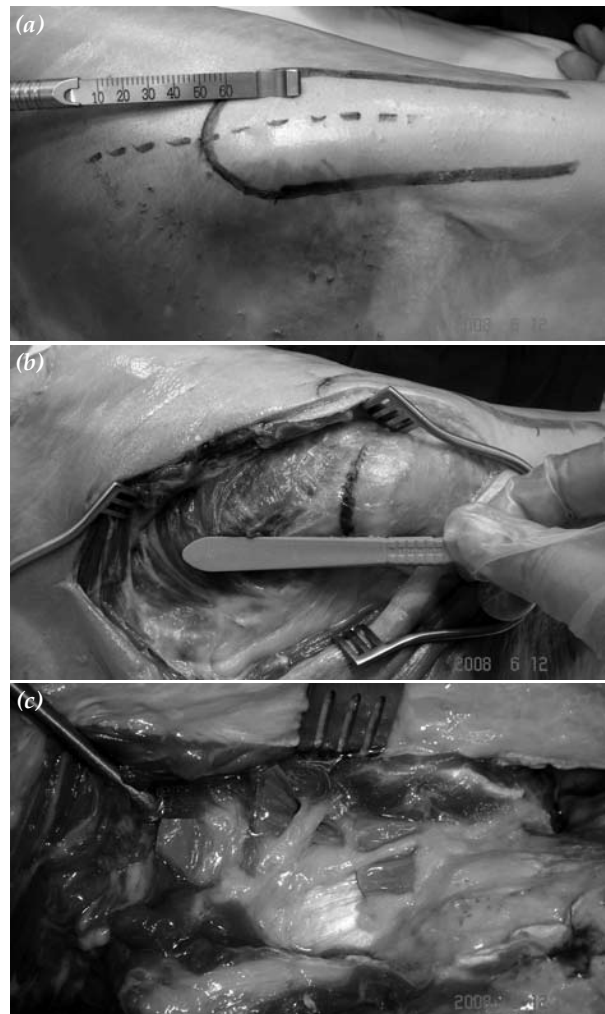


Fig. 1. (a) The relation between trochanter major and Hardinge incision. (b) Relation between tissue, subtissue and subfacial, and estimated localization of superior gluteal nerve. (c) Superior gluteal nerve branches.

The roots of SGN arise from L4, L5, and S1 of sacral plexus and are distributed to the pelvis. It extends from greater sciatic foramen onto the piriformis muscle. Superior gluteal nerve passes between gluteus medius and gluteus minimus laterally and gives its superior and inferior branches. The branching and distribution of motor functions of SGN was described by Jacobs and Buxton<sup>[2]</sup> in 1989. Superior gluteal

Table 1. The distance from described point on greater trochanter to superior gluteal nerve

|              |    |    |    |    |    |    |    |    |    |    |    |    |    |    |    |    |    |    |    |
|--------------|----|----|----|----|----|----|----|----|----|----|----|----|----|----|----|----|----|----|----|
| Cadaver #    | 1  | 2  | 3  | 4  | 5  | 6  | 7  | 8  | 9  | 10 | 11 | 12 | 13 | 14 | 15 | 16 | 17 | 18 | 19 |
| SGS distance | 50 | 48 | 42 | 44 | 46 | 45 | 42 | 43 | 40 | 39 | 42 | 43 | 42 | 44 | 40 | 40 | 41 | 42 | 70 |

nerve terminates on the middle third of gluteus medius. It is the so-called safe zone up to where this nerve terminates. In order to protect this nerve, Hardinge defined "safe zone" and recommended not to extend the incision beyond this zone.<sup>[1,2]</sup> The fact that how long the safe zone courses from trochanter major was investigated by many authors, and reported to be between 3 to 7.2 cm.<sup>[3,10-13]</sup> Today, the most reasonably accepted value for this distance is 5 cm, as described by Ramesh et al.<sup>[3]</sup> in their study. Both Eksioglu et al.<sup>[13]</sup> and Comstock et al,<sup>[14]</sup> in their cadaver studies, demonstrated that height might influence safe zone and that 5 cm above greater trochanter might not always be safe zone. In our study, we concluded that the distance of 4.4 cm above greater trochanter could be considered as safe zone. Cadaver study performed by Khan and Knowles<sup>[15]</sup> reported that branching pattern and anatomic position of SGN, and height might play an important role in intraoperative SGN injuries.

In conclusion, it should be kept in mind that the area described as safe zone in cases undergoing total hip arthroplasty through Hardinge approach may be shorter than that described as 5 cm.

## REFERENCES

1. Hardinge K. The direct lateral approach to the hip. *J Bone Joint Surg [Br]* 1982;64:17-9.
2. Jacobs LG, Buxton RA. The course of the superior gluteal nerve in the lateral approach to the hip. *J Bone Joint Surg [Am]* 1989;71:1239-43.
3. Ramesh M, O'Byrne JM, McCarthy N, Jarvis A, Mahalingham K, Cashman WF. Damage to the superior gluteal nerve after the Hardinge approach to the hip. *J Bone Joint Surg [Br]* 1996;78:903-6.
4. Engh CA Jr, McAuley JP, Engh C Sr. Surgical approaches for revision total hip replacement surgery: the anterior trochanteric slide and the extended conventional osteotomy. *Instr Course Lect* 1999;48:3-8.
5. Siebenrock KA, Rösler KM, Gonzalez E, Ganz R. Intraoperative electromyography of the superior gluteal nerve during lateral approach to the hip for arthroplasty: a prospective study of 12 patients. *J Arthroplasty* 2000;15:867-70.
6. Nercessian OA, Macaulay W, Stinchfield FE. Peripheral neuropathies following total hip arthroplasty. *J Arthroplasty* 1994;9:645-51.
7. Simmons C Jr, Izant TH, Rothman RH, Booth RE Jr, Balderston RA. Femoral neuropathy following total hip arthroplasty. Anatomic study, case reports, and literature review. *J Arthroplasty* 1991;6 Suppl:S57-66.
8. Weale AE, Newman P, Ferguson IT, Bannister GC. Nerve injury after posterior and direct lateral approaches for hip replacement: a clinical and electrophysiological study. *J Bone Joint Surg [Br]* 1996;78:899-902.
9. Kenny P, O'Brien CP, Synnott K, Walsh MG. Damage to the superior gluteal nerve after two different approaches to the hip. *J Bone Joint Surg [Br]* 1999;81:979-81.
10. Baker AS, Bitounis VC. Abductor function after total hip replacement. An electromyographic and clinical review. *J Bone Joint Surg [Br]* 1989;71:47-50.
11. Bos JC, Stoekart R, Klooswijk AI, van Linge B, Bahadoer R. The surgical anatomy of the superior gluteal nerve and anatomical radiologic bases of the direct lateral approach to the hip. *Surg Radiol Anat* 1994;16:253-8.
12. Foster DE, Hunter JR. The direct lateral approach to the hip for arthroplasty. Advantages and complications. *Orthopedics* 1987;10:274-80.
13. Eksioglu F, Uslu M, Gudemez E, Atik OS, Tekdemir I. Reliability of the safe area for the superior gluteal nerve. *Clin Orthop Relat Res* 2003;(412):111-6.
14. Comstock C, Imrie S, Goodman SB. A clinical and radiographic study of the "safe area" using the direct lateral approach for total hip arthroplasty. *J Arthroplasty* 1994;9:527-31.
15. Khan T, Knowles D. Damage to the superior gluteal nerve during the direct lateral approach to the hip: a cadaveric study. *J Arthroplasty* 2007;22:1198-200.