

Need For Clinical Research in Cartilage Tympanoplasty

Kıkırdak Timpanoplastide Klinik Araştırma İhtiyacı

Mirko TOS

*Emeritus professor from ENT Department Gentofte Hospital, University of Copenhagen, Denmark
Professor of Otolaryngology, University of Maribor, Maribor, Slovenia*

Objectives: The goal of this paper is to stimulate the clinical research in cartilage tympanoplasty, and to point out the possibility and need of clinical research. Furthermore, several research projects of clinical research will be elaborated for each method. For this aim, methods and the results of almost all published studies on cartilage tympanoplasty techniques with palisades, stripes and slices were analyzed.

Design: Out of the 23 well-defined cartilage tympanoplasty methods, classified in six groups, the clinical research in the oldest group, consisting of six different methods with palisades, stripes and slices, will be described and analyzed.

Patients and Methods: The six tympanoplasty methods with cartilage –(i) the underlay palisade method of Heermann, (ii) the on-lay palisade method, (iii) the method of broad palisades, (iv) the method of underlay stripes, (v) the method of on-lay stripes, (vi) the Dornhoffer mosaic cartilage tympanoplasty– are briefly described and illustrated. All published anatomical and functional results of surgery, achieved with each of the six methods, are described and analyzed.

Results: The clinical research on cartilage tympanoplasty with palisades, stripes and slices have been very scanty. The anatomical results are good and there have been few re-operations after cartilage tympanoplasty.

Conclusion: New clinical studies on cartilage tympanoplasty should be started and some of the proposed methods of comparison can be used.

Key Words: *Biomedical research; cartilage; tympanoplasty/ methods.*

Amaç: Bu yazının amacı kıkırdak timpanoplasti konusunda klinik araştırmaları teşvik etmek ve gereksinim duyulan olası araştırma alanlarına işaret etmektir. Ayrıca, her bir metot için klinik araştırma açısından çeşitli araştırma projeleri önerilecektir. Bu amaçla, palizad, çubuk ve dilimlerinin kullanıldığı kıkırdak timpanoplasti teknikleri konusunda yayınlanmış hemen hemen tüm çalışmaların metot ve sonuçları analiz edildi.

Tasarı: Net olarak tanımlanmış 23 kıkırdak timpanoplasti metodu altı grupta sınıflandırılmıştır. Bu gruplar içinde, kıkırdak palizad, çubuk ve dilimlerinin kullanıldığı altı farklı metottan oluşan en eski gruptaki klinik araştırmalar anlatılacak ve analiz edilecektir.

Hastalar ve Yöntemler: Kıkırdakın kullanıldığı altı timpanoplasti metodu –(i) Heermann'ın underlay palizad metodu, (ii) on-lay palizad metodu, (iii) geniş palizad metodu, (iv) underlay çubuk metodu, (v) on-lay çubuk metodu, (vi) Dornhoffer'ın mozaik kıkırdak timpanoplastisi– kısaca tanımlandı ve şekillerle anlatıldı. Altı metodon her birinin yayınlanmış bütün cerrahi, anatomik ve fonksiyonel sonuçları anlatıldı ve analiz edildi.

Bulgular: Palizad, çubuk ve dilimlerinin kullanıldığı kıkırdak timpanoplasti konusundaki klinik çalışmalar çok azdır. Anatomik sonuçlar iyidir ve kıkırdak timpanoplasti sonrası çok az bir tekrar ameliyat gereksinimi olmuştur.

Sonuç: Kıkırdak timpanoplasti konusunda yeni klinik çalışmalar başlatılmalıdır ve burada önerilen bazı karşılaştırma metotları kullanılabilir.

Anahtar Sözcükler: *Biyomedikal çalışma; kartilaj; timpanoplasti/yöntem.*

The goal of this paper is to analyze the existing clinical research in cartilage palisade tympanoplasty methods and propose the necessary new clinical studies on results achieved in cartilage palisade tympanoplasty, compared to results achieved after reconstruction of the eardrum with thin fascia or thin perichondrium. Only few such studies have been performed.

The most common problem in otology is poor tubal function, leading during the childhood, in connection to upper respiratory cleft infections to recurrent or chronic secretory otitis media, with retraction and subsequent atrophy of the eardrum. The atrophic and thin eardrum can at any time, in connection to a banal acute otitis media perforate, with poorer chance of spontaneous closure of the perforation than in a non-atrophic eardrum, resulting in a permanent perforation, grossly called sequelae to chronic (non-cholesteatomatous) otitis media. Tubal function may become normal in about 2/3 of cases or remain abnormal in about 1/3 of cases.

In another group of children and adults the retraction of the eardrum may progress, become fixated to the ossicles and to medial wall of the middle ear with poor self-cleaning of the retraction, leading to infection within the retraction, proliferation of the epithelial cones and formation of the cholesteatoma.^[1,2] Tubal function will most often remain poor in about 2/3 of the patients with cholesteatoma.

After surgery of cholesteatoma or other non-cholesteatomatous chronic middle ear conditions, with reconstruction of the eardrum with full-thickness, or half-thickness cartilage grafts, it will be rigid and will be able to prevent postoperative retraction, as shown in several studies,^[3,4] but the rigidity and the thickness of the graft may reduce the postoperative hearing. Experimental studies^[5-7] have shown that a thick and rigid graft is stable, but it has a poorer sound transmission, compared to a thin cartilage graft, or fascia graft, or perichondrium graft.

Thus, the further goal of the clinical studies is to compare the hearing results of cartilage

grafts with various vibrations in relation to the thickness, to the placement of the graft, and in relation to the bony annulus and in relation to the fixation of the cartilage graft to the surroundings.

CARTILAGE TYMPANOPLASTY METHODS AND CLINICAL RESEARCH

Reconstruction of the eardrum with the cartilage grafts, harvested from the tragus or the concha, called cartilage tympanoplasty, has during the last 15 years, become increasingly popular and several new cartilage tympanoplasty methods have been published. Until now 23 various cartilage tympanoplasty methods have been used and published. Recently, the present author has published^[3,4] the first classification based on the 23 different cartilage tympanoplasty methods, dividing them in six main groups.

The cartilage methods belonging to the palisade group will be shortly illustrated, and the clinical outcome of the surgery presented and discussed.

Cartilage tympanoplasty with palisades, stripes and slices

Characteristic for this group is the reconstruction of the eardrum by several pieces of full thickness cartilage, covered by the perichondrium on the ear canal side. This group includes six well-defined methods:^[3,4]

1. Cartilage palisades in underlay technique

This method is the oldest cartilage tympanoplasty, started by Heermann in the early sixties.^[8,9] In the beginning one or two palisades are placed onlay, and they were covered by the fascia. Later six to eight $1/2$ -3 mm broad, full thickness palisades are placed in underlay technique close to each other.^[10] Heermann^[10] placed the anterior palisade under the bony annulus and the inferior ends of the remaining palisades onto the bony annulus (Fig.1). This method is solid, but the vibration of the palisades may be restricted, comparing to the modification (Fig. 2) the present author has used.^[3]

Results: Even though Heermann has been involved with cartilage tympanoplasty for nearly 40 years, he has never published any results of surgery.

The first results on cartilage tympanoplasty were published by Amedee et al.,^[11] in 1989 on 52 ears with perforations, achieving a 100% eardrum closure, at 107 days (range 7-762 days) after surgery. Postoperative mean hearing at 500-2000 Hz, was at 3½ months after surgery good in 18 cases with intact ossicular chain, with a mean PTA of 20 dB before, and 4 dB after operation.

Pere^[12] found in 18 ears 100% closure of the perforation and a postoperative hearing within 10 dB in 15 ears.

In our study^[13] of 32 children with one-stage transcanal surgery for sinus cholesteatoma and entire tensa cholesteatoma at an average of 37 months after surgery (range 3-63 months) all patients had intact and reconstructed eardrum, but two patients had small retractions behind the interposed incus. During the observation period four children underwent re-operation: one because of closure of a small perforation, two because of suspected, but disproved

cholesteatoma and one for conductive hearing loss. Preoperative pure tone average hearing of 0-20 dB was found in 25%, primary after surgery in 66%, and in 75% late after surgery.

Comparison between underlay palisade method and fascia grafting: During the same period, 32 children with similar cholesteatomas were operated by the same surgeon, but instead of cartilage the eardrum was reconstructed with fascia.^[14] In the fascia group there were significantly ($p < 0.01$; χ^2 test) more retractions (12 or 36%) at the re-evaluation.

At the follow-up the mean absolute hearing was 22 dB in the fascia group and 18 dB in the palisade group.^[14]

Comparing functional results and tympanometry: The late functional results were better in the palisade group (71% success).^[15-17] This was particularly the case in ears with an abnormal tympanogram, in which a functional success was achieved in 68% in the palisade group, in contrast to 29% in the fascia group. In the palisade group the mean hearing gain of 11.5 dB was significantly better than in the fascia group with a gain of 4.9 dB.

We could conclude that the anatomical results are good after reconstruction with cartilage palisades, they are better than with fascia.

We also may conclude that hearing results after eardrum reconstruction using cartilage palisades are better than after fascia, despite comparable tympanometric findings.

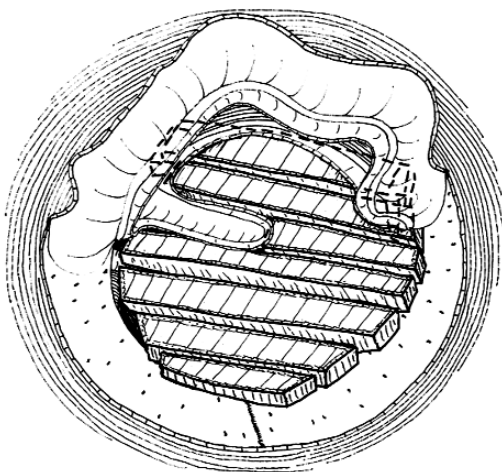


Fig. 1- Underlay cartilage palisade tympanoplasty in a total perforation. The anterior palisade is placed under the bony annulus. The inferior edges of other palisades are placed onto the bony annulus (the Hermann technique), but under the fibrous annulus. At its superior end, the architrave is indicated by the dashed lines.

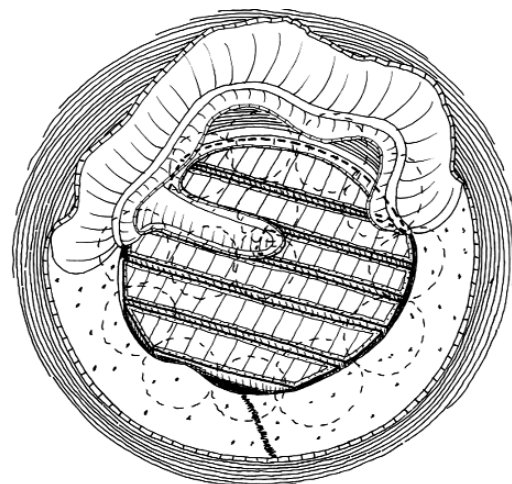


Fig. 2- The palisades are placed at the level of the bony annulus (the present author technique).

Cartilage palisade tympanoplasty seems to provide better functional results especially in ears with a poor tubal function, which is a common situation after cholesteatoma surgery.

Several other comparisons of series with total perforation and intact ossicular chain, with poor tubal function have to be compared to similar series with normal tubal function. Furthermore, the placement of palisades onto the bony annulus (Fig. 1) or at the level of the bony annulus (Fig. 2) could be interesting.

Late results: No late results with a mean observation time of more than five years are published, but they are desired.

Modifications of underlay palisade methods: Some modifications of palisade techniques in relation to covering of the palisades with the perichondrium or with the fascia are described.^[3] Ferekidis et al. placed the palisades under the bony annulus and covered them with the perichondrium.^[18] They achieved in 32 ears with intact ossicular chain a reduction of the mean air bone gap at the frequency of 2000 Hz from 25 dB preoperatively to 12 dB postoperatively.

Wiegand^[19] used the palisades, covered with perichondrium on both sides. Furthermore, he covered the palisades with fascia in total four layers. Among 645 ears, one primary and three

late re-perforations appeared, but hearing results were not published.

2. Cartilage palisades in on-lay technique

After elevation of the ear canal skin and the epithelium of the eardrum remnant, the palisades are placed side by side onto the denuded lamina propria of the eardrum (Figs. 3, 4). The advantage of the on-lay technique is a solid and exact placement of the palisades onto the superior and inferior edges of the eardrum, without any need for support of the palisades in the tympanic cavity. The present author has illustrated various on-lay methods^[3] and often performed on-lay palisade methods in closure of total, subtotal, mid-sized and small perforations, but no results of surgery are published yet.

3. Underlay broad cartilage palisades technique

Bernal-Sprekelsen et al.^[20-22] used 4-5 mm broad, full-thickness palisades in underlay technique (Figs. 5, 6). Usually one broad semi-lunar palisade covers the anterior half of the tympanic cavity, another the posterior half. Small palisades cover the remaining defects. The broad palisades are supported by small rectangular pieces of cartilage placed under the palisades in the hypotympanum or the superior tympanum.

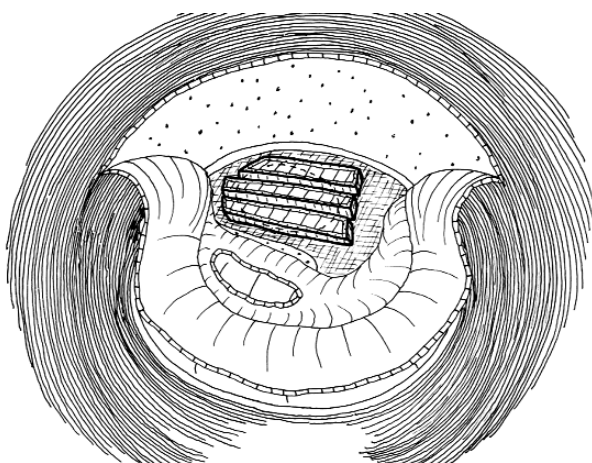


Fig. 3- On-lay palisade technique with elevation of a large anterior skin flap. The ear canal skin flap and the eardrum epithelium at the border of the anterior perforation are elevated. Three half-thickness palisades are placed onto the denuded edges of the lamina propriety.

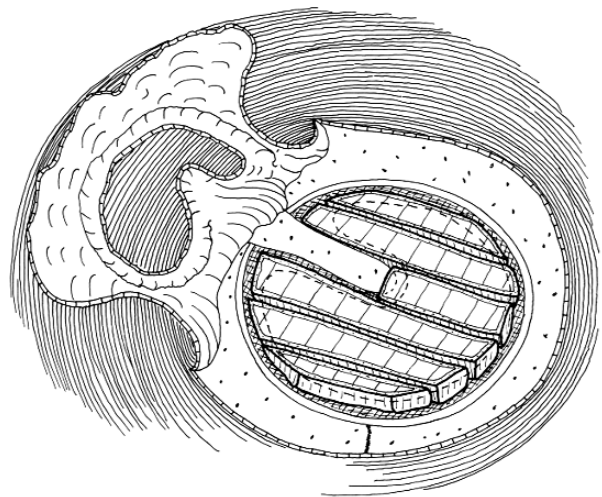


Fig. 4- On-lay palisade technique in a total perforation with elevation of a large skin flap together with the epithelium along the annulus and the eardrum remnant. A malleus flap is elevated up to the short process. The palisades placed onto the edges of the perforation.

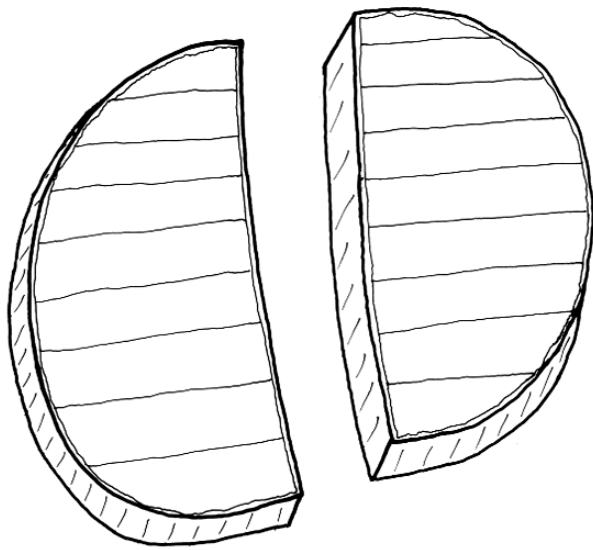


Fig. 5- Two broad semi-lunar cartilage palisades covered on the ear canal side by the perichondrium, to be placed in the anterior and posterior parts of the tympanic cavity.

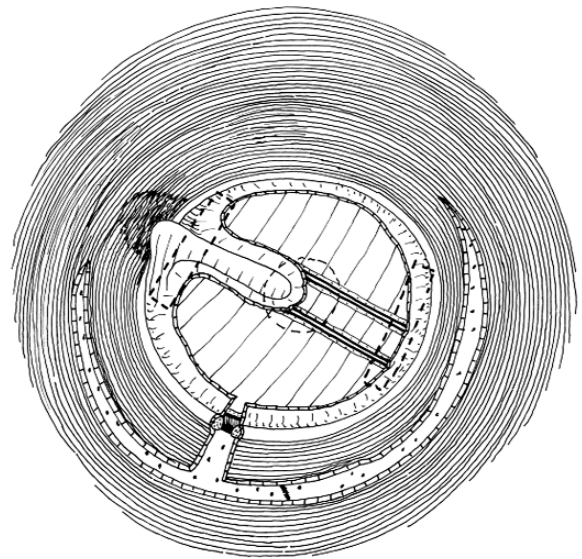


Fig. 6- Two broad palisades cover the anterior and parts of the tympanic cavity and are supported by small pieces of cartilage. The remaining defects are covered by small palisades.

Anatomical results: Among 362 cases with cholesteatoma operated on with 177 canal wall down procedures and 185 canal wall up procedures, during the period between 1992 and 1998, the anatomical results were good: 1.7% re-perforations and 2.5% retractions and 2.2% recurrent cholesteatoma. The mean follow-up was 54 months.

Functional results: The series include PORP and TORP cases only: The mean preoperative PTA-ABG (mean of 500, 1000, 2000 and 4000 Hz) of all 362 cases was before the operation 34.4 dB, at the follow-up 18.1 dB.

The respective data for the PORP series were 28.3/16.8 dB, for the TORP series 40.5/19.5 dB.

Closure of the air bone gap at the follow-up of all 362 cases was within 10 dB in 29.8%, within 20 dB in 62.1%, within 30 dB in 84.1%.

The functional results are good, but the most important results on cases with intact ossicular chain are unfortunately missing.

4. Cartilage stripes in underlay technique

There are substantial differences between the palisade technique and the stripes technique. The

cartilage palisades are cut in a rectangular manner, the cartilage stripes in an oblique manner (Fig. 7a, b). The palisades are placed close to each other, with a small distance between the two

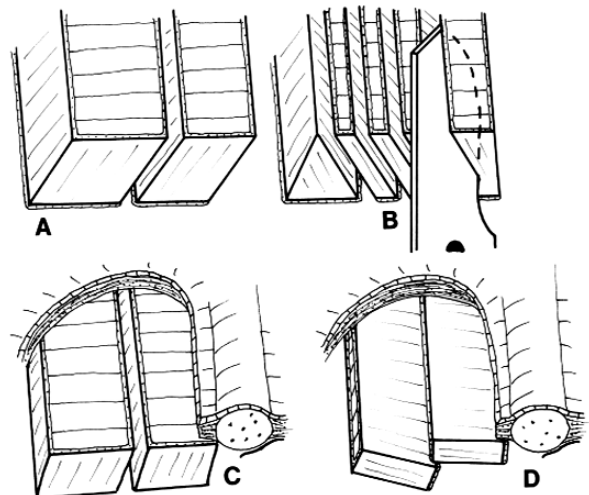


Fig. 7- Characteristics of palisades and stripes. (a) Palisades are cut rectangular to the piece of cartilage as a full thickness graft covered completely by the perichondrium. (b) The stripes are cut oblique, the thickness is half or a third of the thickness of the palisades and the stripes of the perichondrium are small. (c) The palisades are placed close to each other, but still with a small distance to each other. (d) The stripes are placed as tiles of a roof.

neighboring palisades (Fig. 7c). The stripes are placed like the roof tiles (Fig. 7d). The edge of the next stripe is placed onto (or under) the previous stripe (Figs. 8, 9). Neumann^[23] and Neumann et al.^[24,25] was the first to publish the results of this method as a Heermann palisade method, but the present author, for the evident reasons (Fig. 7), separated these two methods. Because of the oblique cutting, the stripes are thinner than the full thickness tragal cartilage palisades (Figs. 8, 9). Cartilage stripes can be placed in the infero-superior or antero-posterior direction (Fig. 10).

Anatomical results: At the mean follow-up of 21 months, of 84 ears 2.4% had a recurrent perforation. The indications for surgery were: cholesteatoma (28 ears), adhesive otitis (22 ears), dry, subtotal perforation (17 ears), chronic mesotympanic otitis (12 ears) and 5 second look operations.

Functional results: Among 84 ears, two ears had a preoperative ear-bone gap of 0-10 dB, at follow-up 25 ears. The respective numbers of ears for the 11-30 dB air-bone group were 48 ears preoperatively and 50 ears at follow-up. For the 31-50 dB group the respective preoperative number was 34 ears, at follow-up nine ears.

Results in 30 ears with intact ossicular chain: The corresponding numbers are for the 0-10 dB

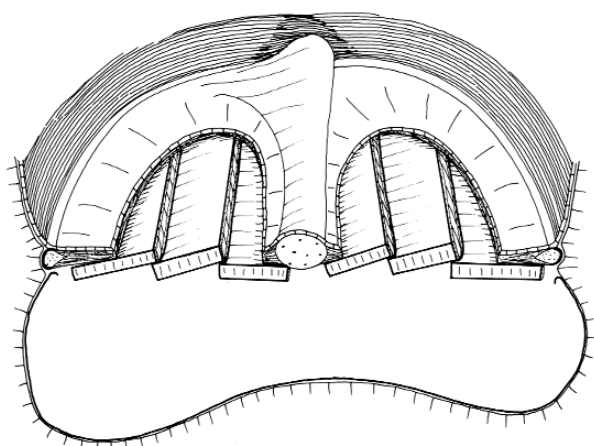


Fig. 8- Side view with some perspective on the superior half of the eardrum in a total perforation closed as underlay grafting with cartilage stripes. The anterior palisade is placed under the anterior border of the perforation. The following stripes are positioned on the edge of the previous stripes- like roof tiles- slightly overlapping each other.

air-bone group one ear preoperatively and 19 ears postoperatively, for the 11-30 dB group 20 ears preoperatively and 10 ears postoperatively, and for the 31-50 dB group nine ears preoperatively and one ear postoperatively.

The results with intact ossicular chain were excellent with 61% of ears within the 0-10 dB air bone gap, at the follow-up, comparing to 9% in 22 ears with tympanoplasty type 2 with interposition, and 17% in 23 ears with TORP in tympanoplasty type 3.

Comparison of cartilage stripes with fascia: Kazikdas et al.^[26] presented an excellent comparison of results, achieved with the underlay cartilage slides method and the underlay fascia method on two comparable series with subtotal perforation and intact ossicular chain.

Anatomical results: Kazikdas et al.^[26] found in 23 ears, with subtotal perforation, closed with cartilage stripes a graft take rate of 96% at mean follow-up of 18.6 months. In the similar series of 28 ears, closed with fascia, the graft take rate was 75%. The only one small perforation in the

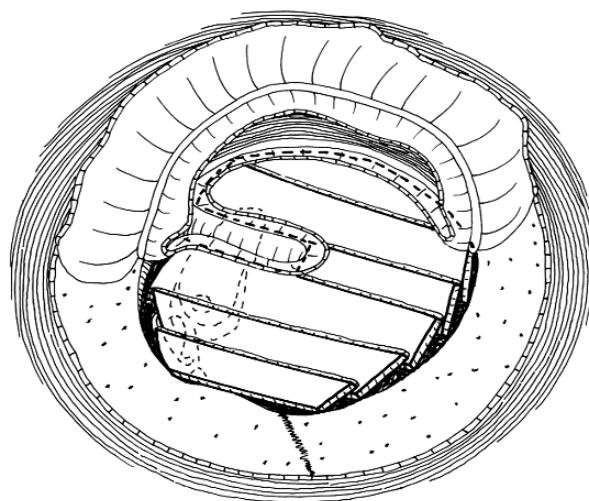


Fig. 9- Cartilage underlay stripe tympanoplasty type 3 in a total perforation and missing stapes. Two tympanomeatal flaps are elevated in a swing-door technique. The tympanic cavity is filled with gelfoam. The missing stapes is replaced with the Kurz TORP columella, placed onto the foot-plate. The anterior stripe is placed under the anterior border of the eardrum, close to the bony annulus. The following two stripes are placed with their edges onto the neighbouring palisades. The posterior stripes are placed onto the head of the columella as the roof tiles.

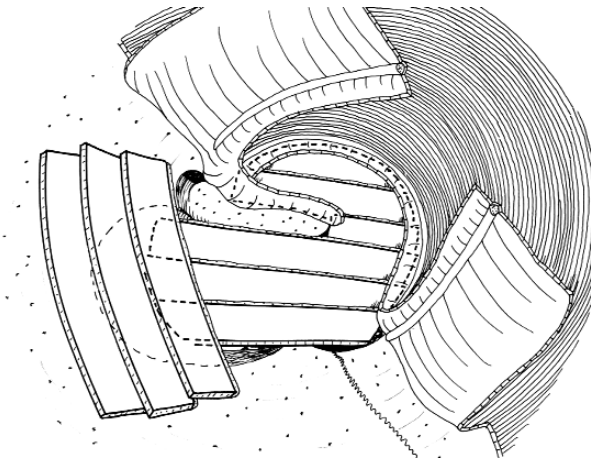


Fig. 10- Reconstruction of the total perforation and bony defects in the attic with cartilage stripes. The total perforation is first covered with anterior cartilage stripes. The long posterior stripes continue up to the bony defect of the attic and are solidly supported by the bone, closing the attic defect. Three cartilage stripes are placed in an oblique anteroposterior direction, and will be totally covered by the two large tympanomeatal flaps.

cartilage group was presumably caused by dislocation of the stripes.

Functional results: In the cartilage group the preoperative PTA was 31.4 ± 10.7 dB, postoperative PTA was 22.4 ± 12.0 dB. In the fascia group the

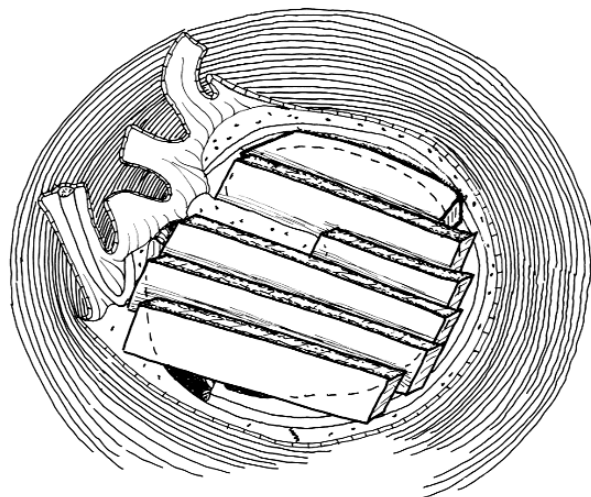


Fig. 11- Closure of a total perforation in on-lay cartilage stripes technique. After elevation of three superior skin flaps^[27] and removal of the epithelium from the eardrum remnant, the first anterior cartilage stripe is placed onto the denuded anterior lamina propria. The edges of the following stripes are placed onto the edges of the previous stripes, like the tiles of a roof.

preoperative PTA was 42.2 ± 14.6 dB, the postoperative PTA was 29.7 ± 17.0 dB. Differences are not significant, but there is a tendency to better hearing in the cartilage group.

5) Cartilage stripes in on-lay technique

After elevation of the epithelial flaps^[27] and the squamous epithelium of the eardrum remnant, the cartilage stripes are placed onto the denuded remnant of the lamina propria of the eardrum remnant (Fig. 11). First the anterior stripe is placed onto the anterior edge of the perforation. The anterior edges of the following stripes are placed as roof tiles onto the previous slides (Fig. 12). The present author has elaborated^[4] and used, with good results, the on-lay method in all sizes of the perforation. The on-lay technique with cartilage stripe is in transcanal approach, a very recommended minimal invasion surgery. However no publication exists on results of this method yet.

6) Dornhoffer mosaic cartilage underlay tympanoplasty

The full thickness slices (or pieces) of tragus or concha cartilage, covered on the ear canal side by the perichondrium, are pieced together, like the pieces of a jigsaw puzzle,^[28,29] to reconstruct a total perforation (Figs. 13, 14). In contrast to the strict Heermann technique, the Dornhoffer mosaic technique is more "liberal", allowing slices of various shapes and sizes. Dornhoffer called this method a modification of Heermann palisade technique,^[29] but the composition of the pieces of the cartilage differs very much from the palisades of Heermann (Figs. 1 to 3), therefore the present author proposed this name, which was accepted by Dornhoffer.

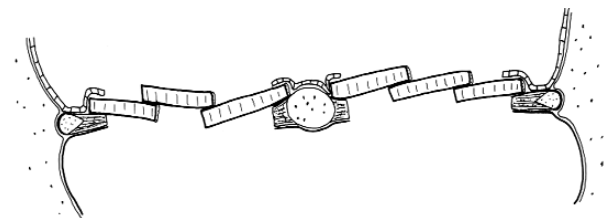


Fig. 12- Side view at the level of the umbo of the on-lay cartilage stripes method. The anterior stripe is placed onto the denuded anterior lamina propria. The following slides are placed like the roof tiles onto the edges of the previous slides.

The Dornhoffer mosaic cartilage tympanoplasty can be applied as an on-lay method as well, by placing the cartilage slices onto the denuded lamina propria of the eardrum remnant, but apparently nobody has tried this method yet.

Results: Dornhoffer performed 1000 cartilage tympanoplasties,^[29] of which 712 had hospital chart available and were included in the study. The general surgical technique was cartilage-perichondrium composite island graft, with implantation of the Dornhoffer graft. In some percentage of ears the Dornhoffer mosaic cartilage underlay tympanoplasty was performed. Unfortunately, the results were reported together without separation of the two different methods.

Anatomical results: At the average follow-up of 2.7 years the re-perforations were found in 2.2%, prosthesis extrusion in 0.5%, revision for conductive hearing loss in 3.3%, postoperative tube insertion in 4.4%.

Functional results of 712 ears: The mean preoperative PTA was 25.7±11.8 dB. The postoperative PTA was 14.1±9.9 dB, representing significant improvement (p<0.05).

Functional results in 226 ears with intact ossicular chain: Preoperative PTA was 16.1±11.0 dB. The postoperative PTA was 11.3±9.2 dB (p<0.05).

Functional results in 252 ears with tympanoplasty type 2 with PORP: The preoperative PTA was 26.7±12.5 dB. The postoperative PTA was 14.5±8.7 dB (p<0.05).

Functional results in 158 ears with tympanoplasty type 3 with TORP: The preoperative PTA was 34.4±11.9 dB. The postoperative PTA was 16.6±10.5 dB (p<0.05).

DISCUSSION

The few clinical studies of the oldest method, the *underlay cartilage palisade method of Heermann*^[8-10] is astonishing. It is also astonishing that the only study on comparison of palisade method with the fascia method by our group^[14-17] started in 1995. There are no long term studies, the longest mean follow is 37 months.^[14]

The *on-lay cartilage palisade method* is a new method without any publication, but illustrated in the book of the present author.^[3] Therefore the results are not published yet.

The *underlay broad palisade method of Bernal-Sprekelsen*^[20-22] are used in connection with canal wall down and canal wall up mastoidectomy and in connection to PORP and TORP. Results in ears with total perforation and with intact ossicular chain are desired.

The *underlay cartilage slides method of Neumann*^[23] is analyzed on 84 ears.^[24,25] In 30 ears with intact ossicular chain the results were very good. Kazikdas et al.^[26] compared underlay cartilage stripes method with the fascia.

The *on-lay cartilage slides method* is new, and is presented in the book of the present author.^[3] The results have to be published.

The results of the *Dornhoffer mosaic cartilage underlay tympanoplasty* is mixed together with the total pars tensa cartilage-perichondrium composite island graft.

Based on the studies of the world literature, we have to conclude that the clinical research on cartilage tympanoplasty with palisades, stripes and slices have been very scanty and should be improved.

Proposal of the methods for clinical research in cartilage tympanoplasty

Even though all of the few known clinical studies on cartilage tympanoplasty with palisades, stripes and slices showed good anatomical results, with few re-perforations, few retractions and few re-operations, we do not know enough about the postoperative hearing. If the postoperative hearing is as good in cartilage tympanoplasty as in tympanoplasty with fascia or perichondrium, then the indications for cartilage tympanoplasty could be widened to the ears with normal tubal function.

Following comparison clinical studies are proposed. They can be divided into several groups:

Group a: Comparison of series *within the same cartilage method* of six described methods with cartilage palisades, stripes and slices.

1. Studies within the same underlay palisade method with the ends of the palisades placed onto the bony annulus (Fig. 1) compared to placement of the palisade ends at the level of the bony annulus (Fig. 2). The size of the perforation, tubal function, and middle ear mucosa are the same. The ossicular chain is normal.

2. Comparison within the same underlay cartilage palisade method with full-thickness palisades and with half-thickness palisades.

3. Comparison within the same on-lay cartilage palisade method with full-thickness palisades and with half-thickness palisades.

Group b: Comparison of the series *with each other* within cartilage group of 6 described methods with cartilage palisades, stripes and slices.

4. Comparison between the underlay (Fig. 2) and the on-lay palisade methods (Fig. 4). The perforation, normal ossicular chain and tubal function are the same in both series.

5. Comparison between tympanoplasty with underlay broad palisades of Sprekelsen (Fig. 6)

and the small palisades of Heermann (Fig. 2). The perforation, tubal function and normal ossicular chain are the same in both series.

6. Comparison between the cartilage underlay stripes (Fig. 8, 9) and the on-lay stripes (Figs. 11, 12). The perforation, tubal function, middle ear mucosa and normal ossicular chain are the same in both series.

7. Comparison between the Dornhoffer mosaic cartilage underlay tympanoplasty (Figs. 13, 14), with the underlay palisade method of Heermann (Figs. 1, 2).

8. Comparison of the Dornhoffer mosaic tympanoplasty with the on-lay cartilage palisades (Figs. 3, 4).

9. Comparison of the Dornhoffer mosaic tympanoplasty with the method of broad palisades of Sprekelsen (Fig. 6).

10. Comparison of the Dornhoffer mosaic tympanoplasty with the method of underlay cartilage slides (Figs. 8, 9).

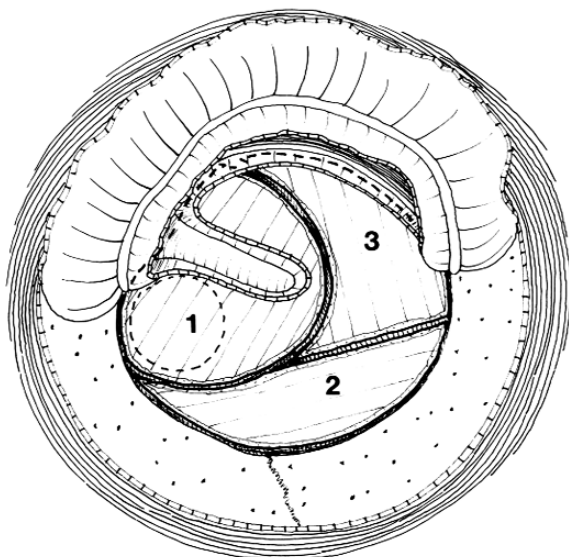


Fig. 13- The Dornhoffer mosaic cartilage underlay tympanoplasty in a total perforation with missing stapes. A TORP is placed onto the footplate, and its head is covered with the first large full thickness piece of cartilage, covered on the ear canal side with the perichondrium. The second cartilage slice covers the posterior-inferior part, and the third slice the anterior-inferior part of the tympanic cavity.^[29]

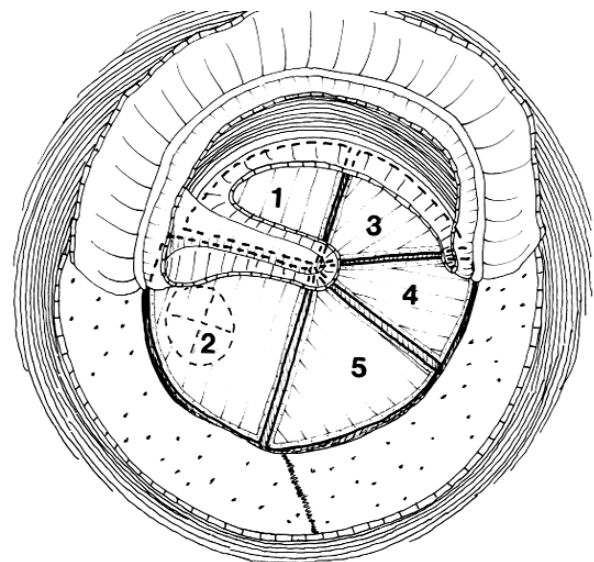


Fig. 14- The Dornhoffer mosaic cartilage underlay tympanoplasty type 3, closing a total perforation and covering a titanium columella. The posterior edge of the first slice is placed under the anterior edge of the malleus handle and covers the anterosuperior quadrant of the tympanic cavity which is filled with the gelfoam balls. The second slice is placed onto the head of the columella and close to the posterior edge of the malleus handle. The third, fourth and fifth slices cover the inferior part of the tympanic cavity.

11. Comparison of the Dornhoffer mosaic tympanoplasty with the method of on-lay cartilage stripes (Figs. 11, 12).

Group c: Comparison of all six described cartilage methods with the tympanoplasty methods of closure the perforation with the fascia or the perichondrium. The perforations, middle ear mucosa, tubal function and intact ossicular chain are identical.

12. Underlay palisades contra tympanoplasty with fascia or perichondrium.

13. On-lay palisades contra fascia or perichondrium.

14. Broad palisades contra fascia or perichondrium.

15. Underlay cartilage stripes contra fascia or perichondrium. One such study is performed by Kazikdas et al.^[26]

16. On-lay cartilage stripes contra fascia or perichondrium.

17. Dornhoffer mosaic cartilage tympanoplasty contra fascia or perichondrium.

Group d: Comparison of all six cartilage tympanoplasty methods of series with normal preoperative tubal function and series with abnormal tubal function.

Group e: Comparison of all six cartilage tympanoplasty methods of series with normal postoperative tubal function and series with abnormal tubal function. Such study is published by Uzun et al.^[15,16]

Group f: Cartilage tympanoplasty after cholesteatoma surgery, after tympanoplasty type 2, or after type 3, after canal wall up or canal wall down mastoidectomy compared to the reconstruction with fascia.

Author note

All figures are included in the book Tos M. *Cartilage Tympanoplasty*, Thieme, Stuttgart, 2008, and are used here, by the permission from the Thieme Comp.

REFERENCES

1. Sudhoff H, Tos M. Pathogenesis of attic cholesteatoma: clinical and immunohistochemical support for combination of retraction theory and proliferation theory. *Am J Otol* 2000;21:786-92.
2. Sudhoff H, Tos M. Pathogenesis of sinus cholesteatoma. *Eur Arch Otorhinolaryngol* 2007;264:1137-43.
3. Tos M. Cartilage tympanoplasty methods. Proposal of a classification. *Otolaryngol Head Neck Surg* 2008. In press.
4. Tos M. *Cartilage tympanoplasty*. Thieme Stuttgart, New York: Thieme Medical Publishers Inc.; 2008. In press.
5. Zahnert T, Bornitz M, Hüttenbrink K-B. Akustische und mechanische Eigenschaften von Trommelfelltransplantaten. *Laryng Rhinol Otol* 1997;76:717-23.
6. Mürbe D, Zahnert T, Bornitz M, Hüttenbrink KB. Acoustic properties of different cartilage reconstruction techniques of the tympanic membrane. *Laryngoscope* 2002;112:1769-76.
7. Hüttenbrink K-B. Biomechanical aspects of middle ear reconstruction. In: Jahnke K, editor. *Middle ear surgery*. New York: Georg Thieme Verlag; 2004. p. 1-51.
8. Heermann J. Erfahrungen mit frei transplantiertem Faszien-Bindegewebe des Musculus temporalis bei Tympanoplastik und Verkleinerung der Radikalhöhle, Knorpelbrücke vom Stapes zum unteren Trommelfellrand. *Z Laryngol Rhinol Otol* 1962;41:141-55.
9. Heermann J. Tympanoplasty with enlargement of the tympanum into the auditory canal for the prevention of adhesions in poor mucosal relations or moderate tubal function. *Z Laryngol Rhinol Otol* 1962;41:235-41.
10. Heermann J. Autograft tragal and conchal palisade cartilage and perichondrium in tympanomastoid reconstruction. *Ear Nose Throat J* 1992;71:344-9.
11. Amedee RG, Mann WJ, Riechelmann H. Cartilage palisade tympanoplasty. *Am J Otol* 1989;10:447-50.
12. Pere P. Erfahrungen mit der Palisadentechnik zum Trommelfellverschluss. *Laryngol Rhinol Otol* 1989;68:569-70.
13. Andersen J, Caye-Thomasen P, Tos M. Cartilage palisade tympanoplasty in sinus and tensa retraction cholesteatoma. *Otol Neurotol* 2002;23:825-31.
14. Andersen J, Caye-Thomasen P, Tos M. A comparison of cartilage palisades and fascia in tympanoplasty after surgery for sinus or tensa retraction cholesteatoma in children. *Otol Neurotol* 2004;25:856-63.
15. Uzun C, Caye-Thomasen P, Andersen J, Tos M. A tympanometric comparison of tympanoplasty with cartilage palisades or fascia after surgery for tensa cholesteatoma in children. *Laryngoscope* 2003;113:1751-7.
16. Uzun C, Caye-Thomasen P, Andersen J, Tos M. Eustachian tube patency and function in tympanoplasty with cartilage palisades or fascia after cholesteatoma surgery. *Otol Neurotol* 2004;25:864-72.
17. Tos M, Uzun C, Caye-Thomasen P, Andersen J. Tympanometry after tympanoplasty with cartilage palisades or fascia after surgery for tensa cholesteatoma in children. In: Lim DJ, Bluestone CD, Casselbrant M, editors. *Proceedings of the 8th*

- International Symposium on recent advances in otitis media. Hamilton, Canada: BC Decker Inc.; 2005. p. 321-2.
18. Ferekidis EA, Nikolopoulos TP, Kandiloros DC, Ferekidou EE, Yiotakis JE, Tsangaroulakis A, et al. Chondrotympanoplasty: a modified technique of cartilage graft tympanoplasty. *Med Sci Monit* 2003;9:CR73-8.
 19. Wiegand H. Knorpelpalisaden und doppelschichtiges Transplantat als Trommelfellersatz. *HNO* 1978; 26:233-6.
 20. Bernal-Sprekelsen M, Tomas Barberan M. Indications, techniques and anatomic results of the tympanoplasty using palisade cartilage. *Acta Otorrinolaringol Esp* 1997;48:279-86.
 21. Bernal-Sprekelsen M, Tomas Barberan M, Romaguera Lliso MD. Preliminary functional results of tympanoplasty with palisade cartilage. *Acta Otorrinolaringol Esp* 1997;48:341-6.
 22. Bernal-Sprekelsen M, Romaguera Lliso MD, Sanz Gonzalo JJ. Cartilage palisades in type III tympanoplasty: anatomic and functional long-term results. *Otol Neurotol* 2003;24:38-42.
 23. Neumann A. Die "Knorpelpalisadentympanoplastik" nach Heermann. *HNO* 1999;47:1074-88.
 24. Neumann A, Hennig A, Schultz-Coulon HJ. Morphologische und funktionelle Ergebnisse der Knorpelpalisadentympanoplastik. *HNO* 2001;50: 935-9.
 25. Neumann A, Schultz-Coulon HJ, Jahnke K. Type III tympanoplasty applying the palisade cartilage technique: a study of 61 cases. *Otol Neurotol* 2003;24:33-7.
 26. Kazikdas KC, Onal K, Boyraz I, Karabulut E. Palisade cartilage tympanoplasty for management of subtotal perforations: a comparison with the temporalis fascia technique. *Eur Arch Otorhinolaryngol* 2007;264:985-9.
 27. Tos M. Stability of myringoplasty based on late results. *ORL J Otorhinolaryngol Relat Spec* 1980; 42:171-81.
 28. Dornhoffer JL. Cartilage tympanoplasty: indications, techniques, and outcomes in a 1,000 patient series. *Laryngoscope* 2003;113:1844-56.
 29. Dornhoffer JL. Cartilage tympanoplasty. *Otolaryngol Clin North Am* 2006;39:1161-76.