

Management of Intracranial Bleeding in Patients With Mechanical Heart Valves: Three Case Reports and a Study of the Literature

*Mekanik Kalp Kapağı Olan Hastalarda İntrakraniyal Kanamaya Yaklaşım:
Üç Olgu Sunumu ve Literatür Çalışması*

Nazmiye Selçuk KAPISIZ, Fahri KAPISIZ, Orhan Veli DOĞAN, Melahat TOKER, Ertan YÜCEL

Department of Cardiovascular Surgery, Ankara Yıldırım Beyazıt Training and Research Hospital, Ankara

Submitted / Başvuru tarihi: 26.12.2006 Accepted / Kabul tarihi: 23.01.2007

In this study, we examined the approach to intracranial bleeding in patients with mechanical heart valves. Three patients with mechanical heart valves and intracranial hemorrhage were included in the study. We discussed the therapeutic approach to these patients and reviewed the literature on the treatment of intracranial bleeding in patients on oral anticoagulation with prosthetic heart valves.

Key Words: intracranial hemorrhage; mechanical heart valves; thromboembolism.

Bu çalışmada mekanik kalp kapağı olan hastalarda gelişen intrakraniyal kanamaya yaklaşım incelendi. İntrakraniyal kanama geçiren mekanik kalp kapaklı üç olgu çalışmaya alındı. Bu hastalara tedavi yaklaşımı tartışıldı ve oral antikoagulan tedavi altındaki prostetik kalp kapaklı hastalarda intrakraniyal kanamanın tedavisi ile ilgili literatür bilgileri gözden geçirildi.

Anahtar Sözcükler: intrakraniyal kanama; mekanik kalp kapağı; tromboembolizm.

Mechanical heart valves are associated with a risk of thromboembolism and anticoagulation is recommended though the latter is associated with a risk for bleeding. Intracranial bleeding is the most dangerous form with more devastating results than other types of bleeding. Management of intracranial hemorrhage is even more difficult in patients with mechanical heart valves, since in those

patients, the clinician must promptly decide whether to withhold or emergently reverse warfarin therapy. Decision making is rather difficult in such cases; a thromboembolic complication risk must be considered after the withdrawal of warfarin and the risk of further intracranial bleeding should be taken into account before recommencing anticoagulation.

The in this study we have taken the intracranial bleeding into account in three patients on oral anticoagulant therapy (OAC) therapy due to their mechanical heart valves.

CASE REPORT

Case 1– A 52-year-old woman was admitted with a sudden onset of numbness in left arm. Aortic and mitral valve replacement was carried out with St. Jude valves seven years ago for aortic insufficiency and mitral stenosis. Mental condition of the patient was well. She had left arm weakness. Cranial computed tomography (CT) disclosed a frontoparietal hematoma. On admission her INR was 7.3. Anticoagulation was reversed by 3 units of fresh frozen plasma and OAC therapy was stopped until the hematoma resorbed by the decision of the neurology department. While echocardiography revealed normal aortic and mitral prosthetic valve functions on admission, after the reversing and cessation of anticoagulation for a week mitral valve thrombosis was detected in the repeat echocardiography. Then the patient was admitted to our cardiovascular intensive care unit. Since the patient still had some weakness and focal convulsions in her left arm, anticoagulation could not be restarted despite the absence of prosthetic mitral valve sound and presence of systolic murmur predominantly in the apex in physical examination. After discussing with the neurology and our cardiovascular team, low dose heparin and inotropic therapy was started, since the patient had mitral valve thrombosis and unresorbed intracranial hematoma at the same time. Heparin therapy was preferred, because follow up with activated coagulation time (ACT) and activated partial thromboplastin time (aPTT) was easy and reversing was possible when needed. One week after this therapy, the progression of mitral valve thrombosis and development of aortic valve thrombosis were detected in echocardiography. The patient had some changes in consciousness and still convulsions in her left arm. Therefore heparin therapy was stopped. Coumadin with INR of 1.8-2 was restarted and was continued until the intracranial hematoma

resorbed. Reoperation for aortic and mitral prosthetic valve thrombosis was postponed since the patient's hemodynamic condition was favorable, and the intracranial hematoma was not resorbed yet. After 6 weeks reoperation was carried out for aortic and mitral valve thrombosis since the intracranial hematoma was found to be resorbed in cranial CT, and the patient had some palpitations due to findings of thrombosis in her echocardiography.

Case 2– A 37-year-old woman was admitted with a sudden onset of right sided weakness and difficulty in speaking. Closed mitral commissurotomy was done in 1971 and mitral valve was replaced with a St. Jude valve in 1997. She had confusion and right sided motor weakness. Babinski was positive on her right side. Cranial CT disclosed a left sided hematoma that causes shifting to the right. Her INR was 6.5. After reversing and cessation of anticoagulation for five days, prosthetic mitral valve sounds disappeared. Echocardiography revealed thrombosis of the prosthetic mitral valve. Heparin was started in addition to the hemodynamic support therapy. Repeat cranial CT revealed no resorption of hematoma. The general condition of the patient got worse and the patient died despite all the medication.

Case 3– A 73-year-old woman was admitted with symptoms and signs of right heart failure. Mitral valve replacement was done with the Omniscience valve in 1998. She was a New York Heart Association Classification (NYHA) Class 3 patient. Echocardiography revealed normal mitral prosthetic valve functions and third degree tricuspid insufficiency of. She was hospitalized for medical treatment. During hospitalization she had a sudden onset of unconsciousness. Cranial CT revealed right sided subacute subdural hematoma. Bilateral Babinski's signs were positive. Her INR was 5.5. Anticoagulation was reversed and stopped. At first, the neurosurgical team considered surgical intervention for the hematoma. Since the general condition of the patient got better and the hematoma resorbed in repeat cranial CT, medical therapy was started. Anticoagulation was

Table 1. Incidence rates of thromboembolism and mortality: effect of valve position and valve type^[1,2]

Valve position	Incidence rates of thromboembolism per 100 patients-years	Incidence rates of mortality per 100 patient-years
Aortic	0.5	4.5
Mitral	0.9	4.6
Both	1.2	4.8
Valve type		
Caged ball (Starr-Edwards)	****	–
Tilting disk (Bjork Shiley, Medtronic Hall, Omnicarbon)	***	–
Bileaflet (St. Jude, Carbomedics, Edwards-Duromedics)	**	–

****: Incidence of thromboembolism is high; *** : Incidence of thromboembolism is intermediate; ** : Incidence of thromboembolism is low.

stopped for three weeks. After resorption of hematoma in repeat cranial CT, anticoagulation was restarted. No thrombosis of prosthetic mitral valve was seen during the cessation of anticoagulation. She was discharged from hospital.

DISCUSSION

The risk of thrombus formation on the valve and rate of subsequent embolism without any antithrombotic treatment is about 10% per year. These patients therefore need to receive life-long oral anticoagulation. Despite this treatment, the overall incidence rate of major thromboembolic complications is still about 1-2 per 100 patient-years. Additionally, these patients have an increased risk of bleeding complications, ranging between 1 and 7 per 100 patient-years.^[1]

Gastrointestinal bleeding and intracranial bleeding were reported to be the most common hemorrhagic complications in warfarin overdose.^[2] Intracranial hemorrhage is the most feared and lethal complication of oral anticoagulation. Most (70%) anticoagulant-related intracranial hemorrhages are intracerebral hematomas (approximately 60% are fatal); the bulk of the remainder are subdural hematomas.^[3]

In patients with prosthetic heart valves and intracranial hemorrhage, the issues of when and how to stop and recommence anticoagulation and how to treat a thromboembolic event in case of a serious intracranial hemorrhage in a patient with prosthetic heart valve are quite controversial. The management of a valvular thrombosis is still more difficult. Patient characteristics that increase the risk of thromboembolism or bleeding need to be identified in order to shorten the duration of cessation of anticoagulation in patients with a high risk of thromboembolism or to recommence anticoagulation in a patient with a high risk of bleeding. Many reports have been published on the risks of thromboembolic and bleeding complications in patients with mechanical heart valves. Thromboembolic risk factors could be classified as factors associated with prosthesis, cardiac diseases, and others. In factors associated with prosthesis, thromboembolism risk depends on the type and place of prosthesis (Table 1). In factors associated with another cardiac disease, atrial fibrillation and left atrial enlargement are very important. In other factors, only age was found to have an increasing effect on thromboembolism. Thromboembolism risk was found to be increased with age, especially after 50 years of age. Hypertension and smoking were also related with an increased thromboembolism risk.^[4]

Table 2. Incidence Rates of valve thrombosis and major and total embolism: effect of antithrombotic treatment^[1]

Anticoagulation	Incidence rates per 100 patient-years (95% confidence intervals)		
	Valve thrombosis	Major embolism	Total embolism#
None	1.8	4.0	8.6
Antiplatelet	1.6	2.2	8.2
Dipyridamole	4.1	5.4	11.2
Aspirin*	1.0	1.4	7.5
Coumadin	0.2	1.0	1.8
Coumadin and antiplatelet	0.1	1.7	3.2

#: This category includes all reported incidences (valve thrombosis, major embolism, and minor embolism; *: Aspirin alone or in combination with dipyridamole or pentoxifylline.

Patient’s age in case 1 and case 3 and the presence of atrial fibrillation in case 2 were found to be thromboembolic risk factors. Age was also a bleeding risk factor in case 1 and 3. The adjustment of patient to anticoagulant therapy was uncertain only in case 2. Intracranial bleeding occurred after taking antiplatelet therapy in addition to anticoagulant therapy in case 1.

It is also necessary to know the effects of other antithrombotic therapies in combination with warfarin on the incidence of thromboembolic and bleeding complications. Valvular thrombosis, major and total embolism were found to be increased four folds in patients taking no therapy. Table 2 gives the effect of antithrombotic treatment on the incidence rates of valvular thrombosis and major and total embolism.^[1] While the addition of antiplatelet therapy to coumadin derivatives appeared to increase the bleeding risk (Table 3), no decrease was seen in the risk for thromboembolism risk.^[1]

Conventional-intensity anticoagulation increases the risk of intracranial hemorrhage 7- to 10-fold, to an absolute rate of nearly 1%/year for many stroke-prone patients.^[4] A level of anticoagulation can be reached in which both thromboembolic and bleeding complications are minimal. i.e. the optimal intensity of OAC. Cannegieter et al.^[4] found this optimum between 2.5 and 4.9 INR for mechanical heart valves. They recommended choosing a target intensity lying in the middle of this range (INR 3.0-4.0).^[3] Lee,^[5] suggested an INR of 2.5 to 3.0.

Intracranial hemorrhage occurring during warfarin therapy may continue to evolve over 24 hours in 50% of the patients, while only 10% of hemorrhages continue to enlarge in the first 24 hours in non-anticoagulated patients. Thus treatment to reverse the coagulopathy should be started as rapidly as possible.^[6] A review of the literature reveals little data regarding the duration of withholding warfarin, subsequent thromboembolic complications, and risk of rebleeding on resumption of warfarin treatment in this sub-

Table 3. Incidence rates of cerebral, major and total bleeding^[1]

Anticoagulation	Incidence rates per 100 patient-years		
	Cerebral bleeding	Major bleeding	Total bleeding*
Antiplatelet	NDA	NDA	0.5
Coumadin	0.5	1.4	1.9
Antiplatelet+Coumadin	NDA	NDA	4.6

NDA: Indicates no data available; *: This category includes all reported incidences (cerebral bleeding, major bleeding, and minor bleeding).

group of patients.^[7] While in some reports discontinuation of anticoagulation for 1 to 2 weeks was reported to have a comparatively low probability of embolic events,^[7-9] in others this relatively safe duration was reported to be longer, for example 4 to 6 weeks.^[6,7] Our first two cases developed valvular thrombosis after about one-week period of OAC discontinuation.

Figure 1 shows the algorithm we recommend in patients with mechanical heart valves who have an episode of intracranial hemorrhage.

Having reversed anticoagulation, it is uncertain when to recommence it. There are no prospective studies in this regard. If the risk of embolism from prosthetic heart valves resulting in major stroke or death is 4% a year and the risk of valvular thrombosis is 1.8% a year, the daily risk can be estimated to be 0.016% $(=(4+1.8)/365)$. Thus stopping anticoagulation for 6 weeks (42 days) is associated with a risk of major stroke or death of 0.67% $(=0.016 \times 42)$, which is not as risky as it is estimated,^[6] and that recurrent bleeding is seen in case of recommencing anticoagulation in the first 6 weeks duration.^[7] First of all, the bleeding should be treated aggressively and the risk

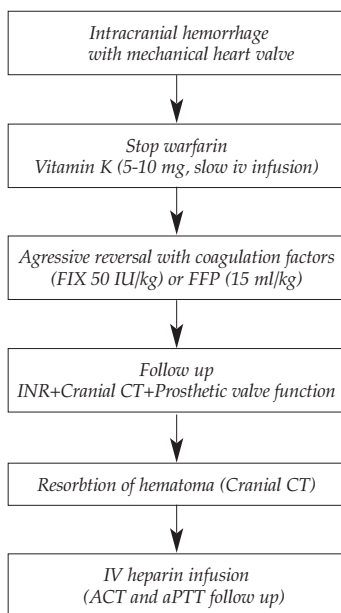


Fig 1. An algorithm for the management of intracranial hemorrhage in patients with mechanical heart valves.

of bleeding versus thromboembolism should be balanced.^[7] Phan et al.^[8] stated that early recurrence of intracranial hemorrhage is exceedingly uncommon. Butler et al.^[10] reports that anticoagulation could be started at low dose with meticulous control in early period. A repeat cranial CT before recommencing anticoagulation is probably advisable to confirm that the bleed is resolving. Whenever anticoagulation is recommenced, either oral warfarin or low molecular weight heparin may be safer than intravenous unfractionated heparin.^[6]

The study of Lazio and Simard^[9] reports that anticoagulation should not be started before postoperative 24 to 48 hours ly in neurosurgical patients. In an animal study, the risk of postoperative bleeding was found to be increased significantly during this period.^[11] Increased hemorrhage in the first 48 hours after an insult can be explained by the principles of basic wound healing and gliosis.^[9] Increased postoperative hemorrhage is seen at the operative site in patients on intravenous heparin in the early postoperative period. They recommend infusion at a rate gradually achieving a therapeutic level rather than a bolus dose.^[12]

In our first two cases, development of valve thrombosis after the first week of reversing and withholding anticoagulation could be explained with age and atrial fibrillation. Trombophilia could be searched in these patients, but it was

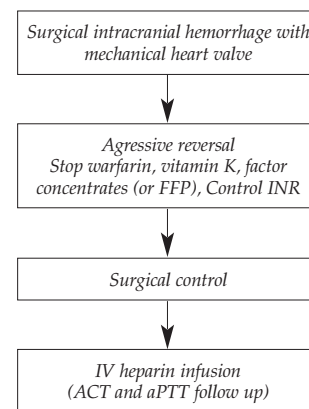


Fig 2. An algorithm for management of surgical intracranial hemorrhage in a patient with mechanical heart valve on oral anticoagulation.

not possible since facilities in our clinic were not sufficient and the socioeconomic levels of our patients were not suitable. Although we did not choose this method, it would have been better in our third case to drain hematoma surgically just after aggressive reversal of anticoagulation, instead of withholding anticoagulation for a long period for resorption of hematoma (Fig. 2). In that way, the thromboembolic event would be less probable, since the duration of the period with no anticoagulation would be short.

Paying attention to some points in the management can result in less thromboembolic and bleeding complications. First of all, patient characteristics that increase the thromboembolic or bleeding risk should be identified and duration of withholding and recommencing anticoagulation should be adjusted according to these risks. Also, optimal intensity of oral anticoagulation should be provided to achieve a stable therapeutic effect. Ensuring adequate reversal of anticoagulation and maintaining complete coagulation is another important issue. This requires aggressive application of the treatment. After maintaining coagulation by controlling INR values, cranial CT should be repeated frequently for the follow up of hematoma. As soon as the arrest of bleeding is certain, low dose intravenous heparin infusion should be started in the early period after the first 48 hours of wound healing. Heparin infusion should be at a rate that is predicted to gradually achieve a therapeutic level for the patient.

In conclusion, the management of intracranial hemorrhage in patients with mechanical heart valves is a complex task that requires skilled and meticulous therapy that should be decided on an individual basis. Further prospective research should be carried out to obtain more confident management protocols.

More important than this is to prevent the occurrence of such complications rather than trying to treat the condition caused by such complications.

REFERENCES

1. Cannegieter SC, Rosendaal FR, Briet E. Thromboembolic and bleeding complications in patients with mechanical heart valve prostheses. *Circulation* 1994;89:635-41.
2. Unverir P, Dağ T, Peynirci H, Demir E, Canbay C, Kaya A, et al. An analysis of bleeding complications related to warfarin in the emergency department. *Turk J Emerg Med* 2006;6:117-21.
3. Hart RG, Boop BS, Anderson DC. Oral anticoagulants and intracranial hemorrhage. Facts and hypotheses. *Stroke* 1995;26:1471-7.
4. Cannegieter SC, Torn M, Rosendaal FR. Oral anticoagulant treatment in patients with mechanical heart valves: how to reduce the risk of thromboembolic and bleeding complications. *J Intern Med* 1999; 245:369-74.
5. Lee LH. Thrombotic and haemorrhagic complications in patients with mechanical heart valve prostheses attending the Singapore General Hospital Anticoagulation Clinic. *Ann Acad Med Singapore* 2000;29:71-4.
6. Crawley F, Bevan D, Wren D. Management of intracranial bleeding associated with anticoagulation: balancing the risk of further bleeding against thromboembolism from prosthetic heart valves. *J Neurol Neurosurg Psychiatry* 2000;69:396-8.
7. Ananthasubramaniam K, Beattie JN, Rosman HS, Jayam V, Borzak S. How safely and for how long can warfarin therapy be withheld in prosthetic heart valve patients hospitalized with a major hemorrhage? *Chest* 2001;119:478-84.
8. Phan TG, Koh M, Wijdicks EF. Safety of discontinuation of anticoagulation in patients with intracranial hemorrhage at high thromboembolic risk. *Arch Neurol* 2000;57:1710-3.
9. Lazio BE, Simard JM. Anticoagulation in neurosurgical patients. *Neurosurgery* 1999;45:838-47.
10. Butler AC, Tait RC. Restarting anticoagulation in prosthetic heart valve patients after intracranial haemorrhage: a 2-year follow-up. *Br J Haematol* 1998;103:1064-6.
11. Laohaprasit V, Mayberg MR. Risks of anticoagulation therapy after experimental corticectomy in the rat. *Neurosurgery* 1993;32:625-8.
12. Katholi RE, Nolan SP, McGuire LB. The management of anticoagulation during noncardiac operations in patients with prosthetic heart valves. A prospective study. *Am Heart J* 1978;96:163-5.