

CASE REPORT

Primary Leiomyoma of the Ovary

Overin Primer Leiomyomu

Ufuk USTA, Neşe KARADAĞ, Emine TÜRKMEN, Hacer HALTAŞ

Başvuru tarihi / Submitted: 28.07.2005 Kabul tarihi / Accepted: 27.09.2005

Primary leiomyoma of the ovary is rare. It is usually reported in women of childbearing age. Clinically most patients are asymptomatic and are incidentally diagnosed. Uterine leiomyomas may accompany ovarian leiomyomas. A 55-year-old postmenopausal woman presented with left-sided pelvic pain. She underwent total abdominal hysterectomy and bilateral salpingo-oophorectomy with an initial diagnosis of a left cystic mass. Macroscopically, it was a solid, gray-white, tumorous nodule, 1 cm in size, with prominent borders. Histopathologic diagnosis was leiomyoma. In the absence of hormonal therapy, the occurrence of a solitary ovarian leiomyoma without uterine involvement is quite rare in postmenopausal women.

Key Words: Hysterectomy; leiomyoma/pathology/surgery; ovarian neoplasms/surgery.

Overin primer leiomyomu nadirdir. Genellikle çocuk doğurma yaşındaki kadınlarda bildirilmiştir. Hastaların çoğu asemptomatiktir ve rastlantısal olarak tanı konur. Over leiomyomlarının birçoğuna uterin leiomyomlar eşlik eder. Sol pelvik ağrı nedeniyle başvuran 55 yaşında postmenopozal kadın hastaya, sol overde kistik kitle nedeniyle total abdominal histerektomi ve bilateral salpingooferektomi yapıldı. Sağ overde saptanan, makroskopik olarak kesit yüzü gri-beyaz, sınırları belirgin, 1 cm çapındaki solid kitlenin mikroskopik inceleme sonucu leiomyom olarak rapor edildi. Hormonal tedavi almayan, postmenopozal bir kadın hastada, uterusu olmaksızın sadece overde leiomyom görülmesi nadir bir durum olduğu için sunmayı uygun bulduk.

Anahtar Sözcükler: Histerektomi; leiomyoma/patoloji/cerrahi; over neoplazileri/cerrahi.

Primary leiomyoma of the ovary is rare and up to date about 55 leiomyomas have been reported.^[1,2] This tumor is usually found in women of childbearing age, the age of patients with ovarian leiomyoma range from 20 to 65 years.^[1,3] Clinically many patients are asymptomatic and the tumor is discovered incidental-

ly.^[1-4] Here, an ovarian leiomyoma, incidentally diagnosed in the right ovary of a 55 year old postmenopausal woman is presented.

CASE REPORT

A 55-year-old postmenopausal woman, with the pain in the left side of pelvis, underwent

total abdominal hysterectomy and bilateral salphingo-ovariectomy due to a left ovarian cystic mass. The woman was not on hormone replacement therapy. The specimen sent to the pathology laboratory was macroscopically composed of uterus and bilateral uterine adnexa. Uterus weighed 71g and was measured as 7.5x6x3 cm. The cut surfaces of the myometrium showed normal morphology. Left ovary, 11x9.5x7 cm in size, was totally cystic and hyperemic and was full of bloody fluid. The inner surface of the cyst was smooth with no papillary structures in it. Right ovary was 2.5x2x0.5 cm with a 1 cm nodule bulging from the outer surface of the ovary. The cut surfaces of the ovary revealed a 1 cm solid, gray-white, tumorous nodule with prominent borders.

After overnight fixation of the specimen with 10% formaldehyde, representative parts from uterus, ovaries and tubes were sampled, which were later processed in alcohol and embedded in paraffin. 5µm thick sections obtained from paraffin blocks were stained with hematoxyline and eosin. Sections from the nodule of the right ovary were taken on polylysine coated slides, for both histochemistry and immunohistochemistry.

In microscopic examination, myometrium of the uterus showed normal histology and endometrium showed cystic atrophy. The sections from the left ovarian cyst wall showed diffuse hyperemia with many dilated vascular structures. The inner surface of the cyst wall

was devoid of epithelium. The macroscopic and microscopic findings were compatible with torsion of a simple ovarian cyst.

The sections of the nodule of the right ovary revealed fascicles and bundles of spindle cells with oval, blunt nuclei and eosinophilic cytoplasm (Fig. 1a). There was no nuclear atypia, no mitosis, no necrosis and there was not any sign of degeneration (Fig. 1b). The initial histopathologic diagnosis was leiomyoma of the ovary and to confirm the diagnosis, the tumor sections were stained with Masson's trichrome and periodic acid shiff (PAS) histochemically, and with desmin (monoclonal, Neomarkers, Fremont, CA, USA) and α - smooth muscle actin (α -SMA) (Monoclonal, Neomarkers, Fremont, CA, USA) immunohistochemically. The tissue sections were stained with Masson's trichrome in the aspect of smooth muscle. There was no specific finding with PAS. There was strong and diffuse cytoplasmic positive reaction for α -SMA and strong but focal cytoplasmic reaction for desmin (Figures 2a, b). The final histopathologic diagnosis of the nodule was primary leiomyoma of the ovary.

DISCUSSION

Ovarian leiomyoma is a unilateral lesion, but a single case of large bilateral ovarian leiomyoma in a 21-year-old woman was reported.^[1,3,4] Ovarian leiomyoma is often described together with uterine leiomyoma, suggesting an identical hormonal stimulant.^[3] Ovarian leiomyoma is

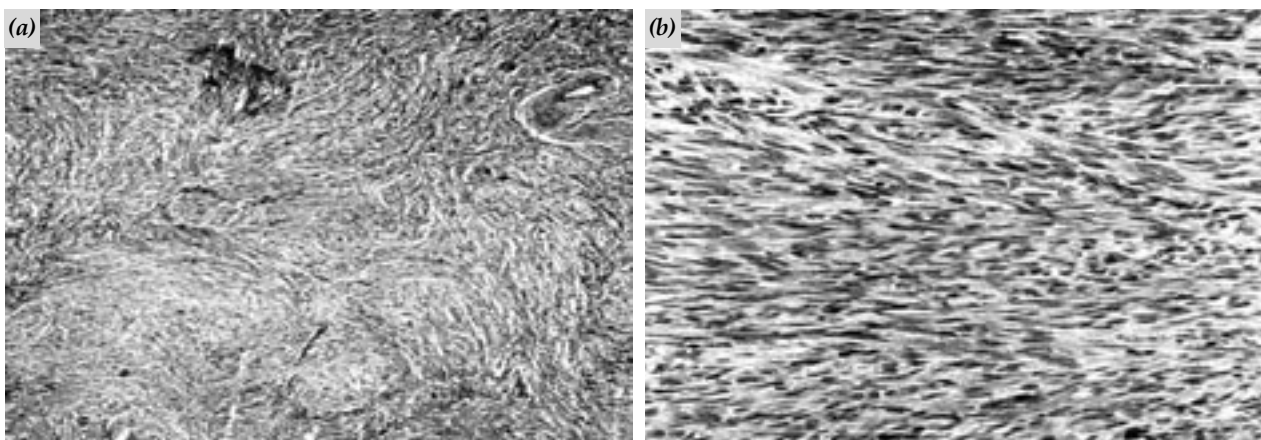


Fig. 1. (a) Tumor composed of interlacing bundles and fascicles of spindle cells (H-E x 100). (b) Spindle cells of ovarian leiomyoma with cigar-shaped blunt nuclei, with no mitosis and no pleomorphism (H-E x 400).

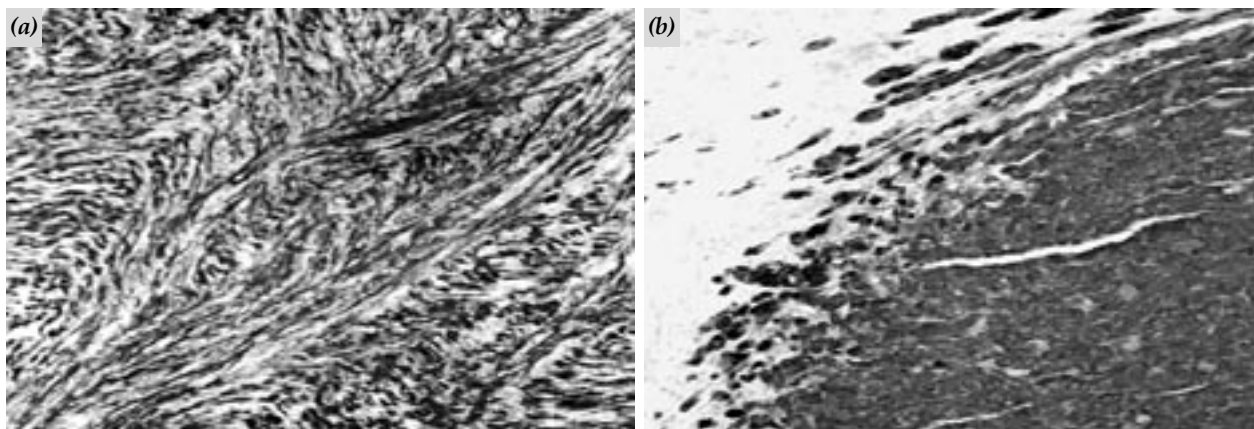


Fig. 2. Immunohistochemically positive cytoplasmic staining for; (a) alpha smooth muscle actin (x 200), (b) desmin (x 200).

microscopically and macroscopically identical with uterine leiomyoma.^[3] In a study by Doss et al with 15 ovarian leiomyomas, it was found out that the majority of ovarian leiomyomas (78%) were associated with uterine leiomyomas.^[5] Thirteen leiomyomas had mitotic indices $<1/10$ high power fields (HPFs) and two had mitotic indices between 1 and 2/10 HPFs.^[5]

Histogenesis of ovarian leiomyoma is tried to be explained by several theories. The muscular coat of the blood vessels, which are present in the hilus of the ovary, and smooth muscle fibers present in the ovary at the attachment of the ovarian ligament are the two main sources responsible for the development of an ovarian leiomyoma.^[2,3] Some authors believe that the tumor could develop from undifferentiated germ cells in the ovarian stroma, but co-existence with germ cell tumors has not been reported yet.^[3] Some authors emphasize smooth muscle fibers in the cortex of the ovary as the origin of leiomyoma.^[2,3] Endometriotic cysts are also suggested to trigger metaplasia of surrounding stroma into smooth muscle cells.^[2] Uterine leiomyoma metastasizing to the ovary is another possibility. However, secondaries are usually multiple, most common in the lungs, and invariably associated with uterine leiomyoma.^[3] In the presented case the absence of uterine leiomyoma is important. This is further evidence that the ovarian leiomyoma was a primary lesion, not a parasitized or a metastasized uterine tumor.

The correct diagnosis of a primary ovarian leiomyoma requires recognition of the smooth muscle nature of the tumor.^[2,6] Immunohistochemically, this can be done with the help of desmin and α -SMA, as both should stain the cytoplasm of the spindle tumor cells. Normal ovarian stroma routinely contains cells stained with detectable desmin less abundant than α -SMA.^[1,6,7] Expression of desmin and actin is equivalent in myogenous lesions, whereas monoclonal actin may be less specific for smooth muscle lesions because other tissues, such as desmoplastic stroma in carcinomas, may express actin, but not desmin.^[6] In the presented case Masson's trichrome stain shows that the lesion is not a desmoplasia with a fibroblastic nature.

Ovarian leiomyomas must be distinguished from ovarian fibroma, thecoma, cellular fibroma and sclerosing stromal tumor.^[2,3,6] Thecomas do not express α -SMA and can thus be differentiated from leiomyomas which stain intensively for α -SMA.^[7] Masson's trichrome, helps to distinguish fibrous and smooth muscle components of the lesion.^[1,2,8] Differentiation from the extremely rare leiomyosarcoma of the ovary depends on the degree of cytological pleomorphism and the number of mitoses.^[1,2,3] However, unless definite nuclear atypia co-exists, a diagnosis of ovarian leiomyosarcoma should be made with caution.^[2]

Treatment of ovarian leiomyoma is simple removal of the tumor by ovariectomy or by peeling it out of the ovary.^[1,3]

In conclusion, this case is a typical primary ovarian leiomyoma with regard to its histopathologic and immunohistochemical features. The postmenopausal patient not taking hormone therapy and the absence of a uterine counterpart of the lesion makes the case more interesting.

REFERENCES

1. Seidman JD, Russell P, Kurman RJ. Surface epithelial tumors of the ovary. In: Kurman RJ, editor. Blaustein's pathology of the female genital tract. 5th ed. New York: Springer-Verlag; 2002. p. 791-904.
2. Erkaya S, Kutlay B, Uygur D, Kara F, Tezer A. Primary ovarian leiomyoma in a postmenopausal woman. *Acta Obstet Gynecol Scand* 2000;79:79-87.
3. Vierhout ME, Pijpers L, Tham MN, Chadha-Ajwani S. Leiomyoma of the ovary. *Acta Obstet Gynecol Scand* 1990;69:445-7.
4. Kandalaf PL, Esteban JM. Bilateral massive ovarian leiomyomata in a young woman: a case report with review of the literature. *Mod Pathol* 1992;5:586-9.
5. Doss BJ, Wanek SM, Jacques SM, Qureshi F, Ramirez NC, Lawrence WD. Ovarian leiomyomas: clinicopathologic features in fifteen cases. *Int J Gynecol Pathol* 1999;18:63-8.
6. Lastarria D, Sachdev RK, Babury RA, Yu HM, Nuovo GJ. Immunohistochemical analysis for desmin in normal and neoplastic ovarian stromal tissue. *Arch Pathol Lab Med* 1990;114:502-5.
7. Czernobilsky B, Shezen E, Lifschitz-Mercer B, Fogel M, Luzon A, Jacob N, et al. Alpha smooth muscle actin (alpha-SM actin) in normal human ovaries, in ovarian stromal hyperplasia and in ovarian neoplasms. *Virchows Arch B Cell Pathol Incl Mol Pathol* 1989;57:55-61.
8. Matamala MF, Nogales FF, Aneiros J, Herraiz MA, Caracuel MD. Leiomyomas of the ovary. *Int J Gynecol Pathol* 1988;7:190-6.