

BRAF^{V600E} Mutation, RET/PTC1 and PAX8-PPAR Gamma Rearrangements in Follicular Epithelium Derived Thyroid Lesions - Institutional Experience and Literature Review

Ahmet Şahpaz¹, Binnur Önal¹, Ahmet Yeşilyurt², Ünsal Han¹, Tuncay Delibaşı³

¹Department of Pathology & Cytology, Ankara Dışkapı Training and Research Hospital, Ankara, Turkey

²Genetic Diagnosis Center, Ankara Dışkapı Training and Research Hospital, Ankara, Turkey

³Department of Endocrinology and Metabolism, Ankara Dışkapı Training and Research Hospital, Ankara, Turkey

Background: Thyroid cancers are the most frequently occurring endocrine malignancy worldwide. In Turkey, thyroid cancers are ranked 2nd on the incidence list in women, with a rate of 16.2%, but they are not included among the top 10 cancer types in men.

Aims: To identify the contribution of the *BRAF*^{V600E} mutation, and the RET/PTC1 and PAX8-PPAR γ rearrangements in the diagnosis and differential diagnosis of follicular epithelial-derived thyroid lesions.

Study Design: Retrospective clinical and molecular genetic study.

Methods: A total of 86 thyroid cases diagnosed between 2001 and 2012 at the Department of Pathology were included in the retrospective study group. Samples best representing the lesion and comprising capsules were chosen in the selection of paraffin blocks pertaining to the cases. The *BRAF*^{V600E} mutation, and the RET/PTC1 and PAX8-PPAR γ rearrangements were investigated in all cases.

Results: The *BRAF*^{V600E} mutation was observed in 12 out of 37 papillary carcinoma cases (32.4%), in 1 out of 15 follicular carcinoma cases (6.6%), and in 1 out of 7 undifferentiated carcinoma cases (14.3%). No mutation was detected in benign lesions.

The RET/PTC1 rearrangement was detected in 2 out

of 7 undifferentiated carcinoma cases (28.6%), and in 1 out of 15 follicular carcinoma cases (6.6%). No gene rearrangement was detected in benign lesions.

The PAX8-PPAR γ rearrangement was detected in 5 out of 15 follicular thyroid carcinoma cases (33.3%) and in 1 out of 15 follicular adenoma cases (6.6%).

Conclusion: The *BRAF*^{V600E} mutation and RET/PTC1 rearrangement were effective in distinguishing the follicular epithelium-derived benign and malignant lesions of the thyroid in the resection materials. The *BRAF*^{V600E} mutation was rather specific to papillary carcinoma in the thyroid, and in cases where the *BRAF*^{V600E} mutation was detected, multi-centricity, lymph node metastasis and capsular invasion findings were observed more frequently compared to cases in which no mutation was observed. The PAX8-PPAR γ rearrangement was observed to be more effective in the differentiation of adenomas and carcinomas in follicular neoplasms of the thyroid, whereas the RET/PTC1 analysis contributed to the differential diagnosis of papillary carcinoma histogenesis at a frequency of 29% in undifferentiated thyroid carcinomas.

Keywords: *BRAF*^{V600E}, diagnosis, management, PAX8-PPAR γ , RET/PTC1, thyroid gland

This study has been partly presented as a poster at the 37th European Congress of Cytology, September 30-October 3, 2012, Cavtat-Dubrovnik, Croatia.

Address for Correspondence: Dr. Ahmet Şahpaz, Department of Pathology and Cytology, Ankara Dışkapı Training and Research Hospital, Ankara, Turkey
Phone: +90 532 726 24 26 e-mail: drasahpaz@gmail.com

Received: 26.06.2014 Accepted: 08.12.2014 • DOI: 10.5152/balkanmedj.2015.15101

Available at www.balkanmedicaljournal.org

Cite this article as:

Şahpaz A, Önal B, Yeşilyurt A, Han Ü, Delibaşı T. *BRAF*^{V600E} mutation, RET/PTC1 and PAX8-PPAR gamma rearrangements in follicular epithelium derived thyroid lesions - institutional experience and literature review. *Balkan Med J* 2015;32:156-66.



Thyroid cancers are the most frequently occurring endocrine malignancy worldwide. In Turkey, thyroid cancers are ranked 2nd on the incidence list in women, with a rate of 16.2%, but they are not included into the top 10 cancer types in men (1). Thyroid nodules constitute the first finding in the majority of cases. Clinically detectable thyroid nodules are observed in 5-20% of society (2). Although most of these nodules are benign, 5-30% are malignant and require surgical treatment. Fine needle aspiration cytology (FNAC) is widely used in Europe and across the world in the differential diagnosis of thyroid nodules (3). Although fine needle aspiration clearly differentiates benign lesions from malignant lesions, FNAC is reported as 'uncertain thyroid cytology' in 20-30% of cases. In the 2010 Bethesda system utilized in reporting thyroid cytopathology (4), cases reported as atypical lesions with undetermined significance (AUS)/follicular lesions with undetermined significance (FLUS), follicular neoplasms (FN) and cases with suspicion of malignancy (SFN) were included in this group. Those diagnosed with 'follicular neoplasm' and 'suspicion of follicular neoplasm' (FN-SFN) firstly undergo lobectomy, while those diagnosed with carcinoma in the histopathological assessment of lobectomy are completed with total thyroidectomy with another surgical procedure. Therefore, if the power of preoperative morphological diagnosis may contribute to the differential diagnosis of thyroid nodules via molecular analysis, this may provide a significant contribution to the clinical management of the cases. Also, two-step or unnecessary surgeries can potentially be avoided.

Molecular analyses are important in both familial and non-familial thyroid carcinomas. In molecular studies, it has been observed that thyroid carcinomas emerge upon passing through a high number of molecular pathways. Four molecular changes, namely *BRAF* and RAS point mutations, and RET/PTC and PAX8-PPAR γ rearrangements, are the best defined in the two most common forms of cancer of the thyroid, which are papillary and follicular thyroid carcinomas (5-9).

Genetic changes in the PI3K/AKT signaling pathway in thyroid carcinomas are reported to be found at higher rates in poorly differentiated carcinomas and at lower rates in well-differentiated carcinomas (10-12). *BRAF* is the member with the strongest activation in the RAF kinase family and is abundantly expressed in follicular thyroid cells (13,14). Activation of a mutation in the *BRAF* gene leads to a malignant transformation in follicular thyroid cells, which is a somatic genetic change and not a germline mutation (5,15-20). It is reported in many studies that papillary thyroid carcinoma cases with the *BRAF*^{V600E} mutation have a more aggressive course and are directly associated with a large tumor diameter, early lymph node or distant organ metastasis, metastasis outside the thyroid and advanced stage disease (21-25).

The RET/PTC and NTRK1 proto-oncogene rearrangements are the best known among various genetic factors playing a role in the pathogenesis of papillary thyroid carcinoma. These genes, which are located on chromosome 1q21-q22, are members of the receptor kinase family transferring the messages coming from outside the cells for cell growth and differentiation (13,26-28). The new fusion genes shaped in papillary cancers are known as RET/PTC (ret/papillary thyroid carcinoma) (5,29,30). Sixteen RET gene rearrangement types have been defined. The most frequently known and thyroid-specific are RET/PTC1, 2 and 3 and the most widespread is RET/PTC1. RET/PTC1 is more common in papillary micro-carcinomas and classic-type papillary thyroid carcinomas, while RET/PTC3 is more common in solid and tall cell subtype papillary thyroid carcinomas. The RET/PTC rearrangement is reported at a lower rate in the follicular subtype of papillary thyroid carcinoma compared to classical papillary thyroid carcinomas. RET/PTC proto-oncogene activation occurs in the early stage of papillary thyroid cancer. It is known that this activation is significantly higher, especially in papillary thyroid carcinomas developed in children and in those exposed to radiation (31-34).

The PAX8-PPAR γ (peroxisome proliferator-activated receptor gamma) rearrangement is a gene rearrangement occurring as a result of the t(2;3)(q13;p25) translocation. It is a translocation that has been specifically defined in follicular carcinomas, between PAX8, which is a paired 'homeobox' gene that plays an important role in thyroid development, and receptor gamma 1 (PPAR gamma 1), which is activated with the peroxisome proliferator that is a nuclear hormone receptor playing an effective role in the differentiation of cells in the final stage. It encodes a copying factor which is mandatory for the proliferation of thyroid follicular cells (5,35). Tumors presenting the PAX8-PPAR γ rearrangement are mostly found in young patients and are small in size, have a solid/nested growth pattern and mostly tend to cause vascular invasion (36).

The contribution of the *BRAF*^{V600E} mutation and the RET/PTC1 and PAX8-PPAR γ rearrangements in the diagnosis and differential diagnosis in follicular epithelium-derived lesions of the thyroid has been investigated in this study.

MATERIALS AND METHODS

Patient selection

In the pilot study of the project (project no: 2012-31, approved by the Hospital Ethics Committee and sponsored by the Research Fund of the Hospital); DNA isolation was performed for *BRAF* mutation on the cell samples obtained via

microlaser dissection from archival thyroid FNA slides while a modification was made to the method in order to include paraffin tissue sections in the study due to the inadequate quality of the RNA obtained for RET/PTC1 and PAX8-PPAR γ rearrangements. Eighty-six cases, selected in a retrospective manner from the archives of the Pathology Clinic dated between 2001 and 2012 and reported as papillary thyroid carcinomas (n=37), follicular thyroid carcinomas (n=15), poorly differentiated thyroid carcinomas (n=7), undifferentiated thyroid carcinomas (n=7), follicular adenomas (n=15) and nodular hyperplasias (n=5), were selected for the study. Archived Hematoxylin and Eosin (H&E) sections of the cases included in the study were re-assessed to determine the paraffin blocks best representing the lesion and comprising the capsule were identified; then, 3-5 sections at a thickness of 8-10 microns were taken from these blocks in order to obtain a DNA/RNA isolation. Data relating to age, gender, lesion size, lymph node metastasis and tumor multi-centricity were recorded from the pathology reports and all sections were reviewed in terms of capsular and vascular invasion.

Molecular analyses

DNA and RNA isolations performed on paraffin tissue sections were measured and found to be adequate. The range of RNA amounts in the samples were measured approximately between 100-600 ng/ μ l by nanodrop. The quality of RNA was controlled via bio-analyzer (agilent) system. Besides, for cDNA control, real time PCR was performed by housekeeping gene ActB.

A High Pure RNA Isolation Kit (Roche®, Mannheim, Germany, cat. No. 06 650 775 001) was used for RNA Isolation, a Transcriptor High Fidelity cDNA Synthesis Kit (Roche®, Mannheim, Germany) was used for cDNA synthesis and a High Pure PCR Template Preparation Kit (Roche®, Mannheim, Germany, cat. No. 06 650 767 001) was used for DNA Isolation, in accordance with the protocols of the manufacturing companies.

The DNA samples that were obtained were preserved at -80°C until the relevant analyses were performed.

A melt curve analysis was conducted using the ready kit LightMix® Kit *BRAF*^{V600E} (Roche®, Berlin, Germany Cat.-No. 40-0406-96) for the *BRAF*^{V600E} Mutation Analysis.

The primers F1: ATTGTCATCTCGCCGTTCC, F2: CAAGAGAACAAGGTGCTGAAGAT, R1: TGTACCCTGCTCTGCCTTTC, R2: CTGCTTCAGGACGTTGAACT, UPL1 and UPL#63 (Roche®, Berlin, Germany cat. no. 04688627001) were used for the RET/PTC 1 Rearrangement Analysis.

The primers F1: AGCCAGCACCTCGA, F2: ATTTGAGCGGCAGCACTAC, R1: TGGAATGTCTTCGTAAT-

GTGGA, R2: CTGCAACCACTGGATCTGTTC, and UPL1 #5, (Roche®, Berlin, Germany cat. no. 04685024001) were used for PAX8-PPAR Gamma Rearrangement.

An absolute quantification was performed for RET/PTC1 and PAX8/PPAR γ . Amplification curves and CT values were obtained for positive samples. No amplification curve or CT value was obtained for negative samples.

Statistical analysis

Statistical analyses were conducted by using the Statistical Package for the Social Sciences (SPSS), version 15.0, for Windows (SPSS, Chicago, IL, USA). Numerical variables were summarized with average \pm standard deviations and [Min-Max] values, while categorical variables were summarized with numbers and percentages. Shapiro Wilks test was used to analyze whether the numerical variables presented a normal distribution. The Kruskal Wallis test was used to investigate whether there was a difference in terms of numerical variables between groups. Paired comparisons were made with Bonferroni corrected Mann Whitney U test. The Mann Whitney U test was utilized to determine whether there was any difference between two groups in terms of numerical variables. Chi-square test was used to assess whether there was any difference between groups in terms of categorical variables. The level of significance was accepted as $p < 0.05$.

RESULTS

The total number of subjects constituting the study group was 86; twenty (23%) of these were benign and 66 (77%) were malignant cases.

No statistically significant difference was observed between malignant and benign subject groups in terms of gender distribution ($p=0.318$). However, the female gender was observed to be dominant in all cases (F: M=3/1).

The age distribution of the subjects varied between 9 and 81 years, while the average age of benign and malignant subject groups was 47.0 \pm 16.7 years. The average age of undifferentiated thyroid carcinoma was observed to be significantly high compared to all groups except for the poorly differentiated thyroid carcinoma group.

The cases were evaluated in terms of histological parameters with prognostic value, such as the tumor size, capsular invasion, vascular invasion, lymph node metastasis and tumor multi-centricity (Table 1).

No significant difference was observed between tumor types in terms of tumor size ($p=0.051$). The size varied between 1 and 4.2 cm in benign cases, while the average size was 2.5 \pm 1.0 cm. The tumor size distribution varied between

TABLE 1. Prognostic histopathological parameters in thyroid neoplasms

	PC	FC	PDT	UTC	Total
Tumor size					
1-2 cm	15	3	1	2	21
2-4 cm	16	2	1	2	21
Larger than 4 cm	6	10	5	3	24
Capsular invasion					
Observed	11	15	6	7	39
Not observed	26	0	1	0	27
Vascular invasion					
Observed	3	9	5	4	21
Not observed	34	6	2	3	45
Lymph node metastasis					
Observed	9	0	2	1	12
Not observed	28	15	5	6	54
Tumor multi-centricity					
Observed	13	2	0	0	15
Not observed	24	13	7	7	51
Total	37	15	7	7	66

PC: papillary carcinoma; FC: follicular carcinoma; PDT: poorly differentiated carcinoma; UTC: undifferentiated carcinoma

1 and 11 cm in malignant cases, while the average size was 3.3 ± 2.2 cm.

In the papillary carcinoma cases shown in Table 1 and displaying a capsular invasion, 4 were classic type, 3 were follicular subtype, 2 were diffuse sclerosing subtype, 1 was oncocytic subtype and 1 was tall cylindrical cell subtype.

All of the papillary carcinoma cases detected to have vascular invasion were classic type.

In 9 papillary carcinoma cases displaying a lymph node metastasis, 5 were classic type, 2 were follicular subtype, 1 was oncocytic subtype and 1 was diffuse sclerosing subtype.

In 13 papillary carcinomas displaying multi-centricity, 2 were classic type, 6 were follicular subtype, 3 were oncocytic subtype, 1 was diffuse sclerosing subtype and 1 was tall cylindrical cell subtype papillary thyroid carcinoma.

No difference was observed between benign tumors in terms of location ($p=1.000$). No statistical difference was observed between malignant tumors in terms of location ($p=0.089$).

Results of the genetic analysis relating to the subjects in the study group are presented in Table 2. The *BRAF*^{V600E} mutation was detected in 12 out of 37 papillary carcinoma cases (32.4%), in 1 out of 15 follicular thyroid carcinomas (6.7%), and in 1 out of 7 undifferentiated thyroid carcinoma cases (14.3%). Five out of 12 papillary thyroid carcinoma cases in which *BRAF*^{V600E} positivity was detected were follicular subtype, 4 were classical type, and 3 were oncocytic subtype papillary thyroid carcinomas (Figure 1a, b).

TABLE 2. Molecular analysis results in thyroid neoplasms and benign lesions

Histological Diagnosis (no. of cases)	<i>BRAF</i> ^{V600E} positive cases (%)	RET/PTC1 rearrangement cases (%)	PAX8-PPAR γ rearrangement cases (%)
PC (37)			
Classical (14)	4 (29)	-	-
Follicular (15)	5 (33)	-	-
Oncocytic (5)	3 (60)	-	1 (20)
Diffuse sclerosing (2)	-	-	-
Tall cell (1)	-	-	-
FC(15)			
Oncocytic (6)	1 (17)	-	2 (33)
Conventional (9)	-	1 (11)	3 (33)
FA (15)			
Oncocytic (7)	-	-	1 (14)
Conventional (8)	-	-	-
PDT (7)	-	-	-
UTC (7)	1 (14)	2 (29)	-
NH (5)	-	-	-

PC: papillary carcinoma; FC: follicular carcinoma; FA: follicular adenoma; PDT: poorly differentiated carcinoma; UTC: undifferentiated carcinoma; NH: nodular hyperplasia

In this study, the *BRAF*^{V600E} mutation was detected in line with literature and Turkish data in 12 (32.4%) out of 37 papillary thyroid carcinoma cases. In cases where the *BRAF*^{V600E} mutation was detected, multi-centricity, lymph node metastasis and capsular invasion findings were observed more frequently compared to cases where no mutation was detected. No BRAF mutation was observed in benign lesions (conventional and oncocytic-type follicular adenoma, nodular hyperplasia), well differentiated tumor diagnostic case groups with undetermined malignancy potential, poorly differentiated thyroid carcinoma and conventional type follicular thyroid carcinoma.

The RET/PTC1 rearrangement was detected in 1 out of 9 conventional follicular thyroid carcinoma cases (11.1%) and in 2 out of 7 undifferentiated thyroid carcinoma cases (28.6%) (Figure 2a, b). This genetic change was not detected in the papillary thyroid carcinomas, oncocytic-type follicular thyroid carcinomas, poorly differentiated thyroid carcinomas and benign lesions (conventional and oncocytic-type follicular adenomas) included in the study.

The PAX8-PPAR γ rearrangement was detected in 1 out of 7 oncocytic-type diagnosed follicular adenomas (14.2%), in 3 out of 9 conventional follicular carcinoma cases (33.3%), in 2 out of 6 oncocytic-type follicular thyroid carcinomas (33.3%) and in 1 out of 37 papillary thyroid carcinoma cases (2.7%) (Figure 3a, b).

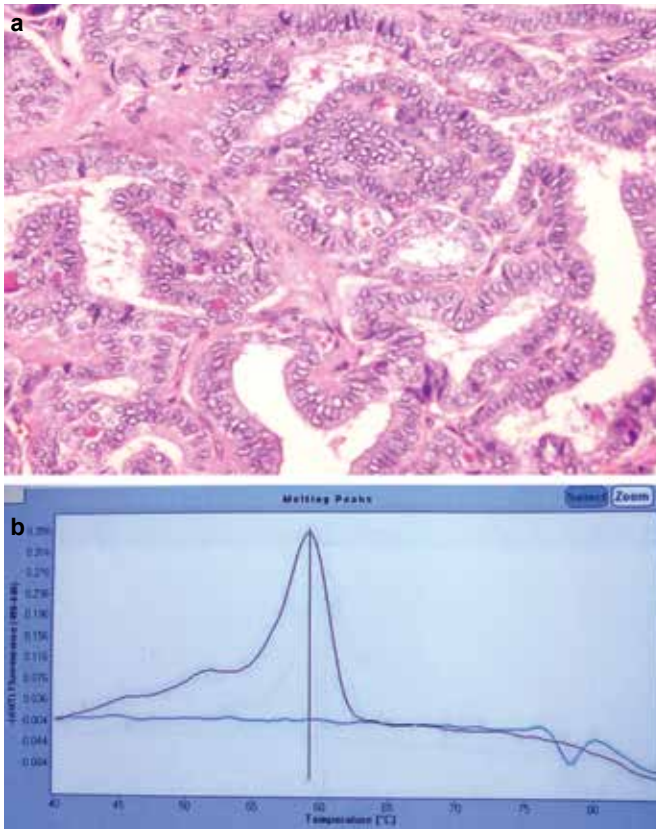


FIG. 1. a, b. Papillary carcinoma (classic type), H&E (x200) (a); BRAF V600E Mutation Melting Curve Analysis (b).

DISCUSSION

One of the most frequently encountered problems in the assessment of follicular epithelium-derived lesions of the thyroid is the differentiation and typing of benign lesions from malignant lesions in lesions displaying a cytologically follicular pattern. Problems may arise in diagnostic and differential diagnoses when there are no evident papillary thyroid carcinoma nuclear characteristics in these lesions histopathologically or when the capsular and/or vascular invasion assessment is insufficient.

The malignancy potential may not be determined in a group of cases even as a consequence of all histopathological and immunohistochemical assessments. Therefore, new diagnostic and prognostic information is required on thyroid lesions. The oncogenic events playing a role in the onset and progress of thyroid cancers should be sufficiently enlightened and the diagnostic and prognostic importance carried by such information for certain tumor types should be identified even if the clinical implementation is not yet clear. The preoperative diagnosis of the tumor, its impacts on biological behavior and the use of molecular markers for customized treatments will protect patients from unnecessary surgical procedures and therapies requiring lifelong replacement.

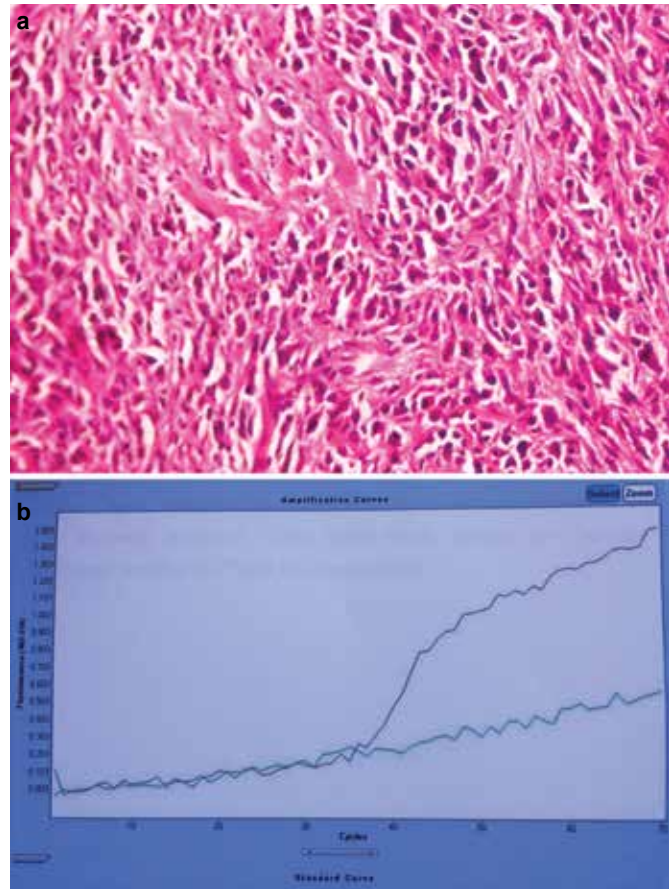


FIG. 2. a, b. Undifferentiated (anaplastic) carcinoma, H&E (x400) (a); RET/PTC1 Rearrangement Amplification curve (b).

The preservation of genetic material obtained from fresh cytological material during the thyroid FNA procedure, which is increasing in use in clinical practice, and the conduct of molecular analysis studies for making a benign/malignant distinction in cases reported as 'undetermined thyroid cytology' such as AUS, FN-FN suspicion and malignancy suspicion in the 'grey area' in the cytopathological assessment, will be more beneficial for clinicians in terms of optimal patient management. It is urgently required to ensure standardization aimed at the cytomolecular and histomolecular pathological infrastructure among centers to serve this purpose. There are many studies in literature about the BRAF mutation as well as the RET/PTC and PAX8-PPAR γ rearrangements. Although the BRAF mutation and RET/PTC rearrangements were generally found to be associated with carcinomas in these studies, the PAX8-PPAR γ rearrangement was also detected in follicular adenoma cases. A summary of literature analysis relating to genetic studies in thyroid lesions is shown in Table 3 (2,10,17,23,28-30,34,35,37-52).

Many studies have demonstrated that the *BRAF*^{V600E} mutation and RET/PTC rearrangement constitute alternative path-

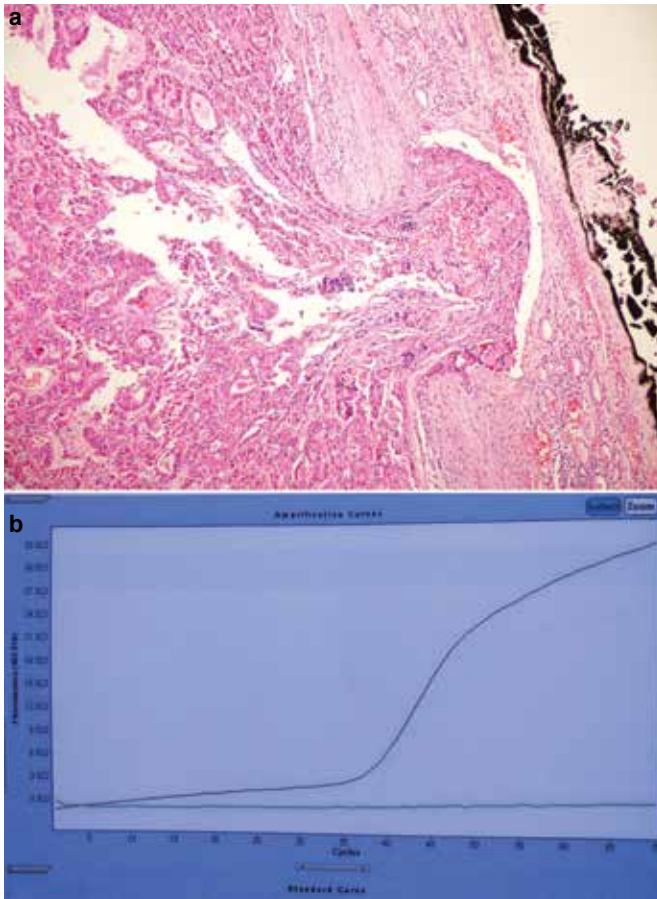


FIG. 3. a, b. Oncocytic Subtype Follicular Carcinoma, H&E (x100) (a); PAX8-PPAR δ Rearrangement Amplification Curve (b).

ways in the etiopathogenesis of papillary thyroid carcinoma. Cases where the *BRAF*^{V600E} mutation and RET/PTC rearrangement coexisted have been reported in the literature (53,54). The coexistence of the *BRAF*^{V600E} mutation and RET/PTC rearrangement was not detected in any subject in our study.

In the studies on the subtypes of papillary thyroid carcinoma, the *BRAF*^{V600E} mutation was detected at a high rate in Warthin-like, tall cell, diffuse sclerosing, solid and classic types, while the *BRAF*^{V600E} mutation was detected at lower rates in follicular subtypes and oncocytic subtypes (38,41,55,56). Mutations above the average rate of 25-30% (60%) reported in oncocytic subtype carcinomas for BRAF positivity and above the rates (33%) specified for follicular subtype papillary carcinomas (10% and lower) were detected in our study. No mutation was detected in diffuse sclerosing (n=2 subjects) and tall cell (n=1 subject) subtypes of papillary carcinomas. However, it is not possible to perform a statistical interpretation due to the low number of subjects.

The BRAF mutation was not detected in follicular lesions in the literature, whereas positivity was observed in one onco-

cytic subtype follicular thyroid carcinoma in our study. Capsular and vascular invasion was observed in the re-assessment of the case with all H&E and immune sections, while the nuclear characteristics and immune profile of papillary carcinoma were not detected. It was reported that the detection of molecular characteristics, in the subjects diagnosed with the follicular subtype of papillary carcinoma, may be significant in terms of demonstrating a potential relation between the papillary-follicular thyroid carcinomas of these tumors (44).

It was reported in the literature that papillary thyroid carcinoma cases found to have a *BRAF*^{V600E} mutation were more aggressive in studies assessing the relation between *BRAF*^{V600E} mutation and prognosis and that metastasis outside the thyroid, lymph node and distant metastases increased, that there was a relation between advanced age and advanced stage tumor and that there was resistance to radioactive iodine therapy (18,43). In line with the literature and Turkish data, a *BRAF*^{V600E} mutation was detected in 12 out of 37 papillary thyroid carcinoma cases (32.4%). In cases where a *BRAF*^{V600E} mutation was detected, multi-centricity, lymph node metastasis and capsular invasion findings were observed more frequently compared to cases where no mutation was detected. In our study, we have observed that *BRAF*^{V600E} mutation may be utilized for diagnostic purposes in the benign/malignant distinction in follicular epithelium derived lesions of the thyroid.

Obtaining DNA smoothly with micro-laser dissection in fine needle aspiration materials provides facility in clinical applications of BRAF in the preoperative period. Furthermore, considering that papillary carcinoma cases where the *BRAF*^{V600E} mutation is observed have worse prognostic parameters compared to those cases where the mutation is not observed, thyroidectomies and lymphadenectomies can be applied on a wider scale in cases where the *BRAF*^{V600E} mutation is observed compared to cases where no mutation is observed.

Sixteen types of RET gene rearrangement have been defined in the literature. The most commonly known, which are specific to the thyroid, are RET/PTC1, 2 and 3, with the most common being RET/PTC1. The RET/PTC rearrangement has been investigated in many studies. No RET/PTC arrangement was detected in benign lesions such as nodular hyperplasias and follicular adenomas in our study, as was the case with most of the studies in the literature (8,27,48).

The RET/PTC1 rearrangement was found to be mostly associated with papillary thyroid carcinomas, while the RET/PTC3 rearrangement was found to be associated with radiation-induced papillary thyroid carcinomas. Moreover, while conventional papillary thyroid carcinoma cases mostly have a classic type morphology, solid and follicular subtype morphology is more commonly observed in subjects exposed to

TABLE 3. Summary of literature relating to genetic analysis studies in thyroid lesions

Name of Study	Year of Study	No. of subjects	<i>BRAF^{V600E}</i>					RET/PTC					PAX8-PPAR γ				
			PC %	FC %	FA %	PDT %	UTC %	PC %	FC %	FA %	PDT %	UTC %	PC %	FC %	FA %	PDT %	UTC %
Cheung et al. (28)	2001	73	-	-	-	-	-	64	-	0	-	0	-	-	-	-	-
Marques et al. (37)	2002	40	-	-	-	-	-	-	-	-	-	-	0	56	13	-	0
Basolo et al. (34)	2002	90	-	-	-	-	-	31	-	-	-	-	-	-	-	-	-
Chiappetta et al. (30)	2002	31	-	-	-	-	-	-	57	58	-	-	-	-	-	-	-
Nikiforova et al. (38)	2003	320	38	0	0	13	10	-	-	-	-	-	-	-	-	-	-
Kimura et al. (39)	2003	124	36	0	0	-	-	16	-	-	-	-	-	-	-	-	-
Nikiforova et al. (35)	2003	88	-	-	-	-	-	-	-	-	-	-	-	36	4	-	-
Cheung et al. (40)	2003	28	-	-	-	-	-	-	-	-	-	-	-	35	55	-	-
Travisco et al. (41)	2004	124	36	-	-	-	-	-	-	-	-	-	-	-	-	-	-
Begüm et al. (42)	2004	23	80	0	-	-	50	-	-	-	-	-	-	-	-	-	-
Salvatore et al. (2)	2004	60	-	-	-	-	-	18	-	0	-	-	-	-	-	-	-
Xing et al. (23)	2005	219	49	-	-	-	-	-	-	-	-	-	-	-	-	-	-
Şahin et al. (43)	2005	108	-	-	-	-	-	-	-	-	-	-	-	57	13	-	-
Castro et al. (44)	2006	79	10	0	0	-	-	-	-	-	-	-	37	45	33	-	-
Lupi et al. (45)	2007	500	44	-	-	-	-	-	-	-	-	-	-	-	-	-	-
Sheu et al. (17)	2007	8	0	-	-	-	-	28	-	-	-	-	-	-	-	-	-
Sapio et al. (46)	2007	168	46	0	0	-	-	-	-	-	-	-	-	-	-	-	-
Kebebew et al. (47)	2007	347	51	1	-	-	-	-	-	-	-	-	-	-	-	-	-
Pizzolanti et al. (10)	2007	6	-	-	-	-	-	17	-	0	-	-	-	-	-	-	-
Mochizuki et al. (48)	2010	42	-	-	-	-	-	11	-	-	-	0	-	-	-	-	-
Marotta et al. (29)	2010	4	25	-	-	-	-	25	-	-	-	-	-	-	-	-	-
Schimnich et al. (49)	2010	86	-	-	-	-	-	-	-	-	-	-	-	62	5	-	-
Guerra et al. (50)	2011	71	-	-	-	-	-	36	0	-	-	0	-	-	-	-	-
Kurtuluş et al. (51)	2012	109	39	-	-	-	-	-	-	-	-	-	-	-	-	-	-
Aday et al. (52)	2013	108	53	-	-	-	-	-	-	-	-	-	-	-	-	-	-
Şahpaz et al.* (presented study)	2013	86	32	7	0	0	14	0	7	0	0	29	3	33	7	0	0

PC: papillary carcinoma; FC: follicular carcinoma; FA: follicular adenoma; PDT: poorly differentiated carcinoma; UTC: undifferentiated carcinoma

radiation (29,51). Although it is specified in certain publications that papillary thyroid carcinomas with a solid morphology, developing pursuant to exposure to radiation have a worse prognosis, no statistical observation was observed in the prognosis of these subjects and gene rearrangement (5,29,51).

The RET/PTC1 rearrangement was not detected in any papillary carcinoma cases in our study. Considering all cases, the detection of the RET/PTC1 rearrangement in only 4 cases and no detection of the RET/PTC1 rearrangement especially in papillary thyroid carcinoma cases differs from the literature. We assume that this difference may arise from the fact that the papillary thyroid carcinoma cases in our study are within the adult age group (18-81) and do not have any history of radiation exposure and also that we have analyzed only the RET/PTC1 rearrangement in this study.

One of the remarkable points in our study is the detection of the RET/PTC1 rearrangement at a rate of 29% in undifferentiated carcinomas. These data substantiate the referred papillary carcinoma histogenesis in undifferentiated carcinomas and the rate of 1/3 in the relevant literature. Considering the remarkably small number of studies on RET/PTC rearrangement in undifferentiated (anaplastic) and poorly differentiated carcinoma cases in the literature, we believe that there is a need for larger series of controlled studies on this topic.

The PAX8-PPAR γ rearrangement is a gene rearrangement occurring as a result of a t(2,3)(q13: p25) translocation. It encodes a copying factor required for the proliferation of follicular thyroid cells (3,33). Positivity at different rates has been reported in the follicular neoplasm of the thyroid. Studies have demonstrated that tumors presenting a PAX8-PPAR γ

rearrangement are seen in younger patients and are associated with tumoral characteristics such as small size, solid/nested growth pattern and tendency to cause vascular invasion more frequently (5,6,34). However, the age range of 5 follicular thyroid carcinoma cases presenting a PAX8-PPAR γ rearrangement was 28-56 years and the average age was 42.6 years, while the tumor sizes varied between 1.8-6 cm, the mean size was 4.2 cm and the vascular invasion rate was detected as 2/5 in our study.

Considering characteristics such as the fact that the follicular adenoma cases where a PAX8-PPAR γ rearrangement was observed had a thick capsule and displayed a strong and widespread immune-reactivity with HBME1 and galectin 3, it was reported that these cases could actually be pre-invasive and/or *in situ* follicular carcinomas (33). Vascular/capsular invasion was observed in the reviewed archive sections of the case diagnosed with oncocyctic-type papillary carcinoma where a PAX8-PPAR γ rearrangement was observed in this study, no diagnostic change was made in the case displaying an immune profile showing HBME1 and galectin 3 as well as a diffuse positivity of CK 19, but the patient was included in the close follow-up protocol in terms of potential hematogeneous metastasis.

Unlike that which is indicated in the literature, PPAX8-PPAR γ rearrangement was detected at a rate of 33% in conventional and oncocyctic subtype follicular thyroid carcinoma cases in our study, while a PAX8-PPAR γ rearrangement was detected in one follicular adenoma case (1/15). No vascular/capsular invasion was observed in the archived sections when this case was re-assessed. However, it was indicated in some studies that the follicular adenoma cases where a PAX8-PPAR γ rearrangement was detected, could be pre-invasive follicular carcinoma or could be diagnosed with adenoma due to overlooking the invasion during the histological assessment (33,57). In subjects where a differential adenoma/carcinoma diagnosis could not be made histomorphologically, the differential diagnosis may be supported with PAX8-PPAR γ rearrangement analysis and a close follow-up protocol can be applied post-surgically in the management of the patient.

It is obvious that the cases with undetectable malignancy potential will receive more specific diagnoses in situations where genetic analyses are utilized. RET/PTC1 and PAX8-PPAR γ analysis contributed to the differential diagnosis in 4 out of 14 cases in our study. One of these displayed the molecular characteristics of papillary thyroid carcinoma while the other 3 displayed the molecular characteristics of follicular thyroid carcinoma.

In our study, positivity was not detected in any of the poorly differentiated thyroid carcinoma cases. Genetic analyses may be significant in terms of guiding us about the histogenesis, in case the differentiated areas are completely lost in these

tumors. In undifferentiated (anaplastic) thyroid carcinomas, genetic analyses may be helpful in cases where it is difficult to make a differential diagnosis with metastases in addition to providing help for identifying papillary carcinoma histogenesis in particular, as was the case in our study.

Nikiforov et al. (58) mentioned in their manuscript that, specifically, BRAF, RET/PTC or PAX8-PPAR γ mutations correlate with the malignant outcome in nearly 100% of cases, assuming that the analysis is performed in a clinical laboratory, following appropriate validation of the detection techniques. Further progress is required in diagnostic accuracy and it will probably be achieved in the near future upon to the availability of novel technologies such as next generation sequencing (NGS), which offers simultaneous sequencing of thousands of millions of short nucleic acid sequences in a massively parallel way and also includes whole genome sequencing (58).

In conclusion, BRAF^{V600E}, RET/PTC1, and PAX8-PPAR γ molecular analyses performed on paraffin tissues in follicular epithelium-derived lesions of the thyroid did not display a clearly diagnostic role, it was observed that BRAF^{V600E} and RET/PTC1 analyses were useful in distinguishing between benign and malignant lesions.

Likewise, a PAX8-PPAR γ rearrangement was not observed in any benign case in our study, except for an oncocyctic-type follicular adenoma case. In terms of patient management, benign oncocyctic-type follicular adenoma and oncocyctic-type papillary carcinoma cases displaying positivity in the PAX8-PPAR γ analysis may be included in a close post-surgical follow-up protocol, as was the case in our study.

The BRAF^{V600E} mutation is specific to the papillary carcinoma diagnosis in our study as is also the case in the literature; in subjects in whom a BRAF^{V600E} mutation was detected, multi-centricity, lymph node metastasis and capsular invasion findings were observed more frequently compared to subjects where no mutation was detected.

A RET/PTC1 gene rearrangement detected in 29% of undifferentiated thyroid carcinomas contributed to the differential diagnosis for papillary carcinoma histogenesis.

Although molecular tests are welcomed with excitement in the field of targeted and individual therapy, for reasons such as the currently low sensitivity of molecular tests and the technical challenges in RNA isolation, only acceleration of the standardization process among the centers focused on the infrastructure of molecular pathology and the conduct of randomized controlled trials in a large case series followed-up clinically may pave the way for developments that may potentially protect patients from unnecessary surgical procedures and lifelong lasting replacement therapies.

Ethics Committee Approval: Ethics committee approval was received for this study from the ethics committee of T.C. Sağlık

Bakanlığı Ankara Dışkapı Yıldırım Beyazıt Eğitim Araştırma Hastanesi Klinik Araştırmalar Etik Kurulu (02/06/2014 Karar No 16/9).

Informed Consent: Written informed consent was obtained from patients who participated in this study.

Peer-review: Externally peer-reviewed.

Author contributions: Concept - A.Ş., B.Ö., Ü.H.; Design - A.Ş., B.Ö., A.Y.; Supervision - A.Ş., B.Ö., A.Y., Ü.H., T.D.; Resource - A.Ş., B.Ö., A.Y., T.D.; Materials - A.Ş., B.Ö., A.Y., Ü.H.; Data Collection &/or Processing - A.Ş., B.Ö., A.Y., Ü.H.; Analysis &/or Interpretation - A.Ş., B.Ö., A.Y.; Literature Search - A.Ş., B.Ö., Ü.H.; Writing - A.Ş., B.Ö., T.D., A.Y., Ü.H.; Critical Reviews - A.Ş., B.Ö., T.D., A.Y., Ü.H.

Conflict of Interest: No conflict of interest was declared by the authors.

Financial Disclosure: The authors declared that this study has sponsored by the Research Fund of the Hospital.

REFERENCES

- Public Healthly Institution of Turkey; Cancer Department; Turkish cancer incidence; 2009 <http://kanser.gov.tr/daire-faaliyetleri/kanser-istatistikleri/922-2009-kanser-insidanslari.html>.
- Salvatore G, Giannini R, Faviana P, Caleo A, Migliaccio I, Fagin JA, et al. Analysis of BRAF point mutation and RET/PTC rearrangement refines the fine-needle aspiration diagnosis of papillary thyroid carcinoma. *J Clin Endocrinol Metab* 2004;89:5175-80. [\[CrossRef\]](#)
- Kocjan G, Feichter G, Hagmar B, Kapila K, I.Kardum-Skelin, Kloboves-Prevodnik V, et al. Fine needle aspiration cytology: a survey of current European practice. *Cytopathology* 2006; 17:219-26. [\[CrossRef\]](#)
- Ali SZ. Thyroid cytopathology: Bethesda and beyond. *Acta Cytol* 2011;55:4-12. [\[CrossRef\]](#)
- Tubbs RR, Stoler MH. Molecular Endocrine Pathology in Goldblum JR (eds), Cell and tissue based molecular pathology. Elsevier 2009; 296-300.
- Zhu Z, Gandhi M, Nikiforova MN, Fischer AH, Nikiforov YE. Molecular profile and clinical-pathologic features of the follicular variant of papillary thyroid carcinoma, an unusually high prevalence of RAS mutations. *Am J Clin Pathol* 2003;120:71-7. [\[CrossRef\]](#)
- Nikiforov YE, Ohori NP, Hodak SP, Carty SE, LeBeau SO, Ferris RL, et al. Impact of mutational testing on the diagnosis and management of patients with cytologically indeterminate thyroid nodules: A prospective analysis of 1056 FNA samples. *J Clin Endocrinol Metab* 2011;96:3390-7. [\[CrossRef\]](#)
- Nikiforov YE, Steward DL, Robinson-Smith TM, Haugen BR, Klopper JP, Zhu Z, et al. Molecular testing for mutations in improving the fine-needle aspiration diagnosis of thyroid nodules. *J Clin Endocrinol Metab* 2009;94:2092-8. [\[CrossRef\]](#)
- Giordano TJ, Kuick R, Thomas DG, Miskel DE, Vinco M, Sanders D, et al. Molecular classification of papillary thyroid carcinoma: distinct BRAF, RAS, and RET/PTC mutation-specific gene expression profiles discovered by DNA microarray analysis. *Oncogene* 2005;24:6646-56. [\[CrossRef\]](#)
- Pizzolanti G, Russo L, Richiusa P, Bronte V, Nuara RB, Rodolico V, et al. Fine-needle aspiration molecular analysis for the diagnosis of papillary thyroid carcinoma through BRAF V600E mutation and RET/PTC rearrangement. *Thyroid* 2007;17:1109-15. [\[CrossRef\]](#)
- Cheung CC, Ezzat S, Ramyar L, Freeman JL, Asa SL. Molecular basis of hürtle cell papillary thyroid. *J Clin Endocrinol Metab* 2000;85:878-82. [\[CrossRef\]](#)
- Ciampi R, Nikiforov YE. RET/PTC Rearrangements and BRAF mutations in thyroid tumorigenesis. *Endocrinology* 2007;148:936-41. [\[CrossRef\]](#)
- Tang KT, Lee CH. BRAF Mutation in Papillary thyroid carcinoma: pathogenic role and clinical implications. *J Chin Med Assoc* 2010;73:113-28. [\[CrossRef\]](#)
- Greco A, Borrello MG, Miranda C, Degl'Innocenti D, Pierotti MA. Molecular pathology of differentiated thyroid cancer. *Q J Nucl Med Mol Imaging* 2009;53:440-53.
- Kakudo K, Bai Y, Liu Z, Li Y, Ito Y, Ozaki T. Classification of thyroid follicular cell tumors: with special reference to borderline lesions. *Endocr J* 2012;59:1-12. [\[CrossRef\]](#)
- Hunt L J. Molecular testing in solid tumors. *Arch Pathol Lab Med* 2008;132:164-7.
- Sheu SY, Schwertheim S, Worm K, Grabellus F, Schmid KW. Diffuse sclerosing variant of papillary thyroid carcinoma: lack of BRAF mutation but occurrence of RET/PTC rearrangements. *Mod Pathol* 2007;20:779-87. [\[CrossRef\]](#)
- Fagin JA, Mitsiades N. Molecular pathology of thyroid cancer: diagnostic and clinical implications. *Best Pract Res Clin Endocrinol Metab* 2008;22:955-69. [\[CrossRef\]](#)
- Sadow PM, Heinrich MC, Corless CL, Fletcher JA, Nosé V. Absence of BRAF, NRAS, KRAS, HRAS mutations, and RET/PTC gene rearrangements distinguishes dominant nodules in Hashimoto thyroiditis from papillary thyroid carcinomas. *Endocr Pathol* 2010;21:73-9. [\[CrossRef\]](#)
- Yip L, Kebebew E, Milas M, Carty SE, Fahey TJ, Parangi S, et al. Summary statement: utility of molecular marker testing in thyroid cancer. *Surgery* 2010;148:1313-5. [\[CrossRef\]](#)
- Trovisco V, Soares P, Preto A, de Castro IV, Lima J, Castro P, et al. Type and prevalence of BRAF mutations are closely associated with papillary thyroid carcinoma histotype and patients' age but not with tumor aggressiveness. *Virchows Arch* 2005;446:589-95. [\[CrossRef\]](#)
- Lee HJ, Choi J, Hwang TS, Shong YK, Hong SJ, Gong G. Detection of BRAF mutations in thyroid nodules by allele-specific PCR using a dual priming oligonucleotide system. *Am J Clin Pathol* 2010;133:802-8. [\[CrossRef\]](#)
- Xing M. BRAF mutation in thyroid cancer. *Endocr Relat Cancer* 2005;12:245-62. [\[CrossRef\]](#)

24. Kumagai A, Namba H, Akanov Z, Saenko VA, Meirmanov S, Ohtsuru A, et al. Clinical implications of pre-operative rapid BRAF analysis for papillary thyroid cancer. *Endocr J* 2007;54:399-405. [\[CrossRef\]](#)
25. Kim SW, Lee JI, Kim JW, Ki CS, Oh YL, Choi YL, et al. BRAFV600E mutation analysis in fine-needle aspiration cytology specimens for evaluation of thyroid nodule: A large series in a BRAFV600E-prevalent population. *J Clin Endocrinol Metab* 2010;95:3693-700. [\[CrossRef\]](#)
26. Marotta V, Guerra A, Sapio MR, Vitale M. RET/PTC rearrangement in benign and malignant thyroid diseases: a clinical standpoint. *Eur J Endocrinol* 2011;165:499-507. [\[CrossRef\]](#)
27. Brzezianska E, Pastuszek-Lewandoska D, Lewinski A. Rearrangements of NTRK1 oncogene in papillary thyroid carcinoma. *Neuro Endocrinol Lett* 2007;28:221-9.
28. Cheung CC, Carydis B, Ezzat S, Bedard YC, Asa SL. Analysis of RET/PTC gene rearrangements refines the fine needle aspiration diagnosis of thyroid cancer. *J Clin Endocrinol Metab* 2001;86:2187-90. [\[CrossRef\]](#)
29. Marotta V, Guerra A, Sapio MR, Campanile E, Motta M, Fenzi G, et al. Growing thyroid nodules with benign histology and RET rearrangement. *Endocr J* 2010;57:1081-7. [\[CrossRef\]](#)
30. Chiappetta G, Toti P, Cetta F, Giuliano A, Pentimalli F, Amendola I, et al. The RET/PTC oncogene is frequently activated in oncocytic thyroid tumors (Hurtle cell adenomas and carcinomas), but not in oncocytic hyperplastic lesions. *J Clin Endocrinol Metab* 2002;87:364-9. [\[CrossRef\]](#)
31. Elisei R, Romei C, Vorontsova T, Cosci B, Veremeychik V, Kuchinskaya E, et al. RET/PTC rearrangements in thyroid nodules: studies in irradiated and not irradiated, malignant and benign thyroid lesions in children and adults. *J Clin Endocrinol Metab* 2001;86:3211-6. [\[CrossRef\]](#)
32. Santoro M, Melillo RM, Fusco A. RET/PTC activation in papillary thyroid carcinoma. *Eur J Endocrinol* 2006;155:645-53. [\[CrossRef\]](#)
33. Cyniak-Magięrska A, Wojciechowska-Durczyńska K, Krawczyk-Rusiecka K, Zygmunt A, Lewiński A. Assessment of RET/PTC1 and RET/PTC3 rearrangements in fine-needle aspiration biopsy specimens collected from patients with Hashimoto's thyroiditis. *Thyroid Res* 2011;4:5. [\[CrossRef\]](#)
34. Basolo F, Giannini R, Monaco C, Melillo RM, Carlomagno F, Pancrazi M, et al. Potent mitogenicity of the RET/PTC3 oncogene correlates with its prevalence in tall-cell variant of papillary thyroid carcinoma. *Am J Pathol* 2002;160:247-54. [\[CrossRef\]](#)
35. Nikiforova MN, Lynch RA, Biddinger PW, Alexander EK, Dorn GW, Tallini G, et al. RAS point mutations and PAX8-PPAR gamma rearrangement in thyroid tumors: evidence for distinct molecular pathways in thyroid follicular carcinoma. *J Clin Endocrinol Metab* 2003;88:2318-26. [\[CrossRef\]](#)
36. Foukakis T, Au AYM, Wallin G, Geli J, Forsberg L, Clifton-Bligh R, et al. The ras effector NORE1A is suppressed in follicular thyroid carcinomas with a PAX8-PPAR γ fusion. *J Clin Endocrinol Metab* 2006;91:1143-9. [\[CrossRef\]](#)
37. Marques AR, Espadinha C, Catarino AL, Moniz SN, Pereira T, Sobrinho LG, et al. Expression of PAX8-PPAR rearrangements in both follicular thyroid carcinomas and adenomas; *J Clin Endocrinol Metab* 2002;87:3947-52. [\[CrossRef\]](#)
38. Nikiforova MN, Kimura ET, Gandhi M, Bindinger PW, Knauf JA, Basolo F, et al. BRAF mutations in thyroid tumors are restricted to papillary carcinomas and anaplastic or poorly differentiated carcinomas arising from papillary carcinomas. *J Clin Endocrinol Metab* 2003;88:5399-404. [\[CrossRef\]](#)
39. Kimura ET, Nikiforova MN, Zhu Z, Knauf JA, Nikiforov YE, Fagin JA. High prevalence of BRAF mutations in thyroid cancer: genetic evidence for constitutive activation of the RET/PTC-RAS-BRAF signaling pathway in papillary thyroid carcinoma. *Cancer Res* 2003;63:1454-7.
40. Cheung L, Messina M, Gill A, Clarkson A, Learoyd D, Delbridge L, et al. Detection of the PAX8-PPAR fusion oncogene in both follicular thyroid carcinomas and adenomas. *J Clin Endocrinol Metab* 2003;88:354-57. [\[CrossRef\]](#)
41. Trovisco V, Castro V, Soares P, Maximo V, Silva P, Magalhaes J, et al. BRAF mutations are associated with some histological types of papillary thyroid carcinoma. *J Pathol* 2004;202:247-51. [\[CrossRef\]](#)
42. Begum S, Rosenbaum E, Henrique R, Cohen Y, Sidransky D, Westra WH. BRAF mutations in anaplastic thyroid carcinoma: implications for tumor origin, diagnosis and treatment. *Mod Pathol* 2004;17:1359-63. [\[CrossRef\]](#)
43. Sahin M, Allard BL, Yates M, Powell JG, Wang X, Hay ID et al. PPAR γ staining as a surrogate for PAX8/PPAR γ fusion oncogene expression in follicular neoplasms: clinico pathological correlation and histopathological diagnostic value. *J Clin Endocrinol Metab* 2005;90:463-8. [\[CrossRef\]](#)
44. Castro P, Rebocho AP, Soares RJ, Magalhaes J, Roque L, Trovisco V, et al. PAX8-PPAR {gamma} rearrangement is frequently detected in the follicular variant of papillary thyroid carcinoma. *J Clin Endocrinol Metab* 2006;91:213-20. [\[CrossRef\]](#)
45. Lupi C, Giannini R, Ugolini C, Proietti A, Berti P, Minuto M, et al. Association of BRAF V600E mutation with poor clinicopathological outcomes in 500 consecutive cases of papillary thyroid carcinoma. *J Clin Endocrinol Metab* 2007;92:4085-90. [\[CrossRef\]](#)
46. Sapio MR, Guerra A, Posca D, Limone PP, Deandrea M, Motta M, et al. Combined analysis of galectin-3 and BRAFV600E improves the accuracy of fine-needle aspiration biopsy with cytological findings suspicious for papillary thyroid carcinoma. *Endocr Relat Cancer* 2007;14:1089-97. [\[CrossRef\]](#)
47. Kebebew E, Weng J, Bauer J, Ranvier G, Clark OH, Duh QY, et al. The prevalence and prognostic value of BRAF mutation in thyroid cancer. *Ann Surg* 2007;246:466-70. [\[CrossRef\]](#)
48. Mochizuki K, Kondo T, Nakazawa T, Iwashina M, Kawasaki T, Nakamura N, et al. RET rearrangements and BRAF mutation in undifferentiated thyroid carcinomas having papillary carcinoma components. *Histopathology* 2010;57:444-50. [\[CrossRef\]](#)
49. Schimnich AA, Milosevic D, McIver B, Flynn H, Reddi HV, Eberhardt NL, et al. Evaluation of the PAX8/PPARG translocation in follicular thyroid cancer with a 4-color reverse-transcription

- PCR assay and automated high-resolution fragment analysis. *Clin Chem* 2010;56:391-8. [\[CrossRef\]](#)
50. Guerra A, Sapio MR, Marotta V, Campanile E, Moretti MI, Deandrea M, et al. Prevalence of RET/PTC rearrangement in benign and malignant thyroid nodules and its clinical application. *Endocr J* 2011;58:31-8. [\[CrossRef\]](#)
 51. Kurtulmuş N, Düren M, Giray S, İnce Ü, Peker Ö, Aydın Ö, et al. BRAFV600E mutation in Turkish patients with papillary thyroid cancer: strong correlation with indicators of tumor aggressiveness. *Endocrine* 2012;42:404-10. [\[CrossRef\]](#)
 52. Dağlar-Aday A, Toptas B, Ozturk T, Seyhan F, Saygılı N, Eronat AP, et al. Investigation of BRAFV600E mutation in papillary thyroid carcinoma and tumor-surrounding nontumoral tissues. *DNA Cell Biol* 2013;32:13-8. [\[CrossRef\]](#)
 53. Domingues R, Mendonca E, Sobrinho L, Bugalho M.J. Searching for RET/PTC rearrangements and BRAF V599E mutation in thyroid aspirates might contribute to establish a preoperative diagnosis of papillary thyroid carcinoma. *Cytopathology* 2005;16:27-31. [\[CrossRef\]](#)
 54. Romei C, Ciampi R, Faviana P, Agate L, Molinaro E, Bottici V, et al. BRAFV600E mutation, but not RET/PTC rearrangements, is correlated with a lower expression of both thyroperoxidase and sodium iodide symporter genes in papillary thyroid cancer. *Endocr Relat Cancer* 2008;15:511-20. [\[CrossRef\]](#)
 55. Xing M. BRAF Mutation in Papillary Thyroid Cancer: Pathogenic role, molecular bases, and clinical implications. *Endocr Rev* 2007;28:742-62. [\[CrossRef\]](#)
 56. Xing M, Westra WH, Tufano RP, Cohen Y, Rosenbaum E, Rhoden KJ, et al. BRAF mutation predicts a poorer clinical prognosis for papillary thyroid cancer. *J Clin Endocrinol Metab* 2005;90:6373-9. [\[CrossRef\]](#)
 57. Nikiforov YE. Molecular analysis of thyroid tumors. *Mod Pathol* 2011;24(Suppl 2):S34-43. [\[CrossRef\]](#)
 58. Nikiforov YE, Linwah Y, Nikiforova MN. New strategies in diagnosing cancer in thyroid nodules: impact of molecular markers. *Clin Cancer Res* 2013;19:2283-8. [\[CrossRef\]](#)