



Hybrid Stenting Procedure for Aortic Coarctation in a Very Low Birth Weight Newborn

Aras Tulunoğlu¹, Fatma Sevinç Şengül¹, Sertaç Haydin², Alper Güzeltaş²

¹Clinic of Pediatric Cardiology, University of Health Sciences Türkiye, İstanbul Mehmet Akif Ersoy Thoracic and Cardiovascular Surgery Training and Research Hospital, İstanbul, Türkiye

²Clinic of Pediatric Cardiac Surgery, University of Health Sciences Türkiye, İstanbul Mehmet Akif Ersoy Thoracic and Cardiovascular Surgery Training and Research Hospital, İstanbul, Türkiye

Herein, we present the case of a very low birth weight newborn with severe aortic coarctation which worsened despite treatment with prostaglandins. Coarctation stenting is a feasible alternative treatment choice to avoid the higher morbidity and mortality risks associated with the surgical repair.¹⁻³

A premature newborn (gestational age, 28 weeks) weighing 1,100 grams was referred to our center with absent femoral pulses and high blood pressure for his age recorded in the upper extremities. Echocardiography revealed significant coarctation of the aorta, a bicuspid aortic valve, and patent ductus arteriosus. The 4 mm segment of the isthmus was only 1.5 mm (Z score: -4). The left ventricle was spherical and hypertrophic (Z score: > 2), and its function was normal at the time (EF: 74%) (Figure 1). PGE1 was administered palliatively prior to performing surgery. Two weeks later, the infant developed oliguria, feeding intolerance, and mild abdominal distention. An emergency intervention was planned.

In a catheterization laboratory, our pediatric cardiovascular surgeon performed a right carotid artery cut-down technique, using a 5-Fr sheath (Glidesheath Slender Introducer; Terumo Corporation, Japan) advanced over a 0.014" coronary guidewire. An angiogram was obtained by injecting a radio-opaque dye into the hand via the introducer sheath; it demonstrated the coarctation area. The isthmus region, distal arcus, and segment distal to the coarctation were 4, 2.45, and 5.3 mm, respectively (Figure 2). Thus, a 4.5/9 mm coronary stent (Alvimedica Ephesos™ II;) was implanted in the coarctation area. The mounted coronary stent was positioned via a 0.014" coronary guidewire over the isthmus, just distal to the left subclavian artery. An angiogram confirmed the accurate positioning of the stent, and the balloon was inflated up to just above the nominal pressure, dilating the stent to approximately 4 mm (Figure 2). The procedure was performed in 20 minutes, and the fluoroscopy time

was 240 s. After the carotid artery was repaired, the procedure was completed without any complications. Postoperatively, the patient's symptoms of poor feeding and oliguria had diminished; the infant was transported back to the NICU. Six months after being discharged, the infant electively underwent coarctation repair surgery.

Coarctation stenting is preferred over surgery for palliation in very low birth weight infants because of the high mortality and morbidity

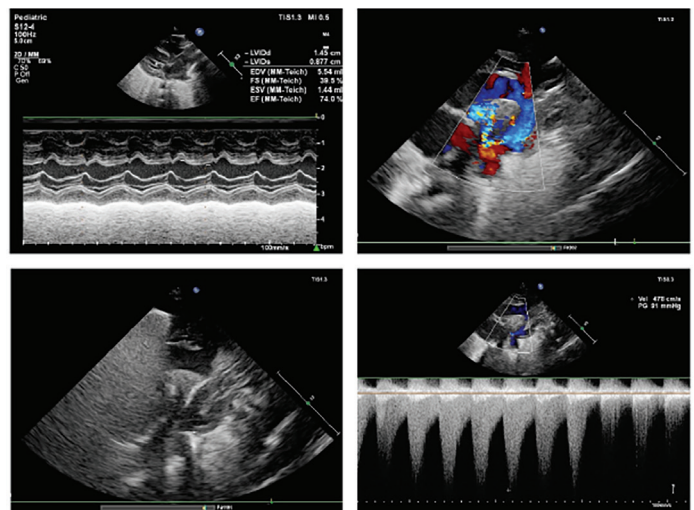


FIG. 1. Echocardiography showed left ventricular dilatation and hypertrophy (upper left), severe narrowing of the distal transverse aorta and retrograde flow in the patent ductus arteriosus (upper right), severe coarctation of the aorta (2D image, lower left), and a very high-pressure gradient (95 mmHg from proximal to distal sites of the coarctation; lower right).



Corresponding author: Aras Tulunoğlu, Clinic of Pediatric Cardiology, University of Health Sciences Türkiye, İstanbul Mehmet Akif Ersoy Thoracic and Cardiovascular Surgery Training and Research Hospital, İstanbul, Türkiye

e-mail: arastulunoglu@gmail.com

Received: October 08, 2023 **Accepted:** November 02, 2023 **Available Online Date:** May 02, 2024 • **DOI:** 10.4274/balkanmedj.galenos.2023.2023-9-57

Available at www.balkanmedicaljournal.org

ORCID iDs of the authors: A.T. 0000-0002-0190-6512; FS.Ş. 0000-0001-6791-3777; S.H. 0000-0003-4198-212X; A.G. 0000-0003-1924-9036.

Cite this article as: Tulunoğlu A, Şengül FS, Haydin S, Güzeltaş A. Hybrid Stenting Procedure for Aortic Coarctation in a Very Low Birth Weight Newborn. *Balkan Med J.*; 2024; 41(3):224-5.

Copyright@Author(s) - Available online at <http://balkanmedicaljournal.org/>

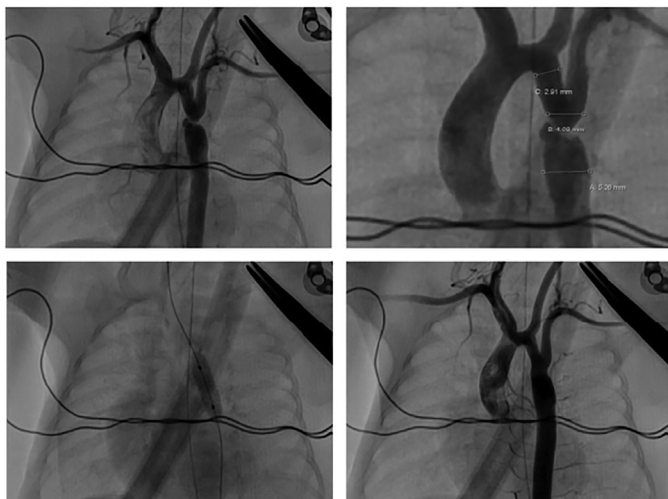


FIG. 2. Angiogram showing the coarctated site in the left oblique plane (upper left), measurements of the transverse and distal aorta (upper right), inflation of the coronary stent over a balloon in the correct position (lower left), and flow to the distal aorta (lower right).

rates. The early and late follow-up results encourage the application of coarctation stenting in carefully selected cases. Stent implantation using hybrid approaches should be considered in premature babies to avoid vascular complications.

Informed Consent: Informed consent was obtained from the patient's parents.

Authorship Contributions: Concept- A.T., F.S.Ş, S.H., A.G.; Design- A.T., F.S.Ş, S.H., A.G.; Data Collection or Processing- A.T., F.S.Ş, S.H., A.G.; Analysis or Interpretation- A.T., F.S.Ş, S.H., A.G.; Literature Search- A.T., F.S.Ş, S.H., A.G.; Writing- A.T., F.S.Ş, S.H., A.G.

Conflict of Interest: No conflict of interest was declared by the authors.

REFERENCES

1. Mini N, Zartner PA, Schneider MBE. Zartner Stenting of critical aortic coarctation in neonates between 600 and 1,350 g. Using a transfemoral artery approach. *Front Cardiovasc Med* 2022;9:1025411. [\[CrossRef\]](#)
2. Cools B, Meyns B, Gewillig M. Hybrid stenting of aortic coarctation in very low birth weight premature infant. *Catheter Cardiovasc Interv* 2013;81:E195-E198. [\[CrossRef\]](#)
3. Stegeman R, Breur JMPJ, Heuser J, et al. Primary coronary stent implantation is a feasible bridging therapy to surgery in very low birth weight infants with critical aortic coarctation. *Int J Cardiol* 2018;261:62-65. [\[CrossRef\]](#)