



# FAVA Syndrome with Unique Synovial Localisation Mimicking Diffuse Pigmented Villonodular Synovitis

Ufuk Usta<sup>1</sup>, Meltem Ayyıldız Mercan<sup>1</sup>, Gülşah Burgazdere<sup>2</sup>, Fethi Emre Ustabaşoğlu<sup>2</sup>, Mert Çiftdemir<sup>3</sup>

<sup>1</sup>Department of Pathology, Trakya University Faculty of Medicine, Edirne, Türkiye

<sup>2</sup>Department of Radiology, Trakya University Faculty of Medicine, Edirne, Türkiye

<sup>3</sup>Department of Orthopaedics and Traumatology, Trakya University Faculty of Medicine, Edirne, Türkiye

In 2014, Alomari et al.<sup>1</sup> have described a novel clinical, radiologic, and histopathologic entity known as “fibroadipose vascular anomaly (FAVA)” that comprises a fibroadipose lesion associated with venectasia and presents with pain. Since then, 143 cases have been published in the English literature as case reports or case series, spanning the ages of newborns to 35 years. Of these, only 35 cases were male.<sup>2-7</sup> The lesion, which is primarily found in the soft tissues of the lower extremities, was also described in the soft tissues of the upper extremities and trunk. Histologically, these intramuscular masses are composed of proliferated thin-walled, blood-filled vessels, fatty tissue, and dense perivascular fibrous tissue.<sup>2</sup> Despite FAVA being a sporadic lesion that is particularly associated with somatic mutations in the *PIK3CA* gene, the diagnosis of previously presented cases was primarily based on radiological and histopathological findings. Only a few presented cases exhibit molecular evidence of *PIK3CA* mutations.<sup>2,6,8</sup>

FAVA is included in the unclassified vascular anomalies category in the vascular malformations group of the International Society for the Study of Vascular Anomalies.<sup>9</sup> The magnetic resonance imaging (MRI) findings are essential for distinguishing these lesions from other vascular malformations. In MRI, the presence of a fatty component causes them to appear as hyperintense intramuscular structures on both T1- and T2-weighted images. Nevertheless, because of the presence of fluid, they are less hyperintense on T2-weighted images than vascular malformations.<sup>10</sup>

The literature consistently characterizes all the FAVA cases as occurring in the striated muscle tissues. This paper presents a case of FAVA in a 12-year-old male with a unique localization of intraarticular synovial tissue in the left knee joint. This tissue radiologically mimics diffuse pigmented villonodular synovitis and histologically resembles lipoma arborescence with additional features of hemosiderotic synovitis. This paper emphasizes its

clinical, radiologic, histopathologic, and molecular findings. Written and oral informed consent were obtained from the patient.

An eleven-year-old male patient presented to the orthopedic outpatient clinic with a history of swelling in his left knee for the previous 18 months, which had resulted in difficulty in walking. The patient exhibited unique phenotypic characteristics, including short stature, hydrocephalus, telorbitism, and a webbed neck. Additionally, the patient provided a history of having undergone surgery for an undescended testicle four years prior.

The patient reported that he experienced a fall four months ago, leading to an exacerbation of his left knee symptoms. On physical examination, it was observed that the suprapatellar region of the left knee had a large swelling and enlarged cutaneous vessels. Although the knee movements were painful, the left knee had a full range-of-motion. A radiographic examination revealed a slight enlargement of the left distal femur in the coronal plane as well as a gross lateralization of the patella. MRI showed widespread effusion in the patellofemoral joint. These effusions extended toward the suprapatellar region and caused distension, especially in the lateral capsular recess. Thick septations, widespread papillary projections, and synovial hypertrophy were detected within the effusion. Furthermore, the effusion contained hypointense foci on T2 weighted imaging, which suggested hemosiderin deposition. Lipoma arborescence and FAVA were excluded from the differential diagnosis because there were no signal alterations associated with a fatty component in the effusion. As a result of radiological evaluation, the patient was diagnosed with diffuse pigmented villonodular synovitis (PVNS), particularly due to the presence of hypointense foci on T2 weighted imaging indicating hemosiderin deposition (Figures 1, 2).



**Corresponding author:** Ufuk Usta, Department of Pathology, Trakya University Faculty of Medicine, Edirne, Türkiye

**e-mail:** drufukusta@hotmail.com

**Received:** 12 July, 2024 **Accepted:** 23 August, 2024 **Available Online Date:** January 02, 2025 • **DOI:** 10.4274/balkanmedj.galenos.2024.2024-7-12

Available at [www.balkanmedicaljournal.org](http://www.balkanmedicaljournal.org)

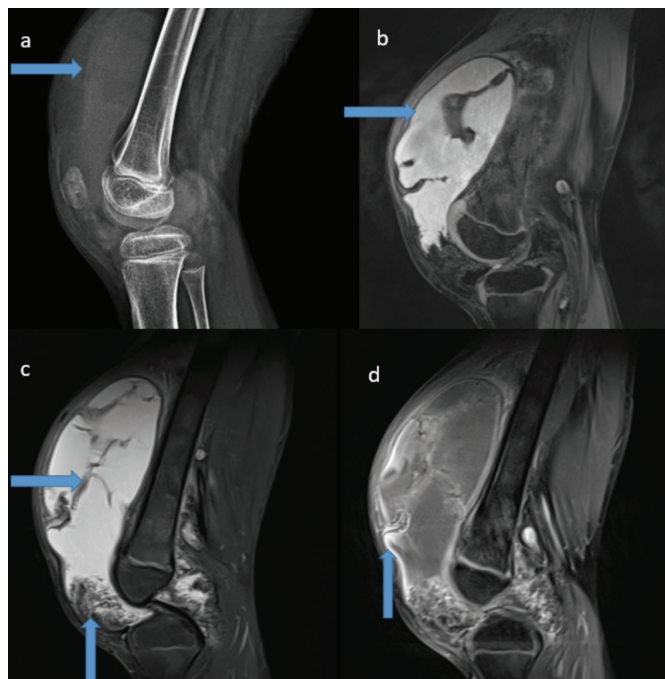
**ORCID iDs of the authors:** U.U. 0000-0002-0003-5903; M.A.M. 0000-0003-1329-3431; G.B. 0009-0007-3839-7786; F.E.U. 0000-0002-0340-4487; M.Ç. 0000-0002-9677-2819.

**Cite this article as:** Usta U, Ayyıldız Mercan M, Burgazdere G, Ustabaşoğlu FE, Çiftdemir M. FAVA Syndrome with Unique Synovial Localisation Mimicking Diffuse Pigmented Villonodular Synovitis. *Balkan Med J*; 2025; 42(1):83-5.

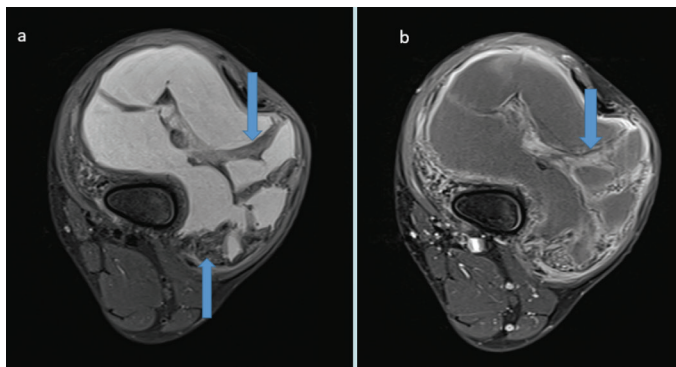
Copyright@Author(s) - Available online at <http://balkanmedicaljournal.org/>

The patient was investigated for various monoarthritis etiologies. Subsequently, the patient's case was reviewed by the institutional tumor board. Following the preliminary diagnosis of PVNS at tumor board, excisional biopsy was planned for the patient.

Macroscopically, the biopsy tissue was composed of a pigmented and spongy soft tissue mass that predominantly exhibited a villonodular growth pattern (Figure 3). The hematoxylin-eosin-stained sections

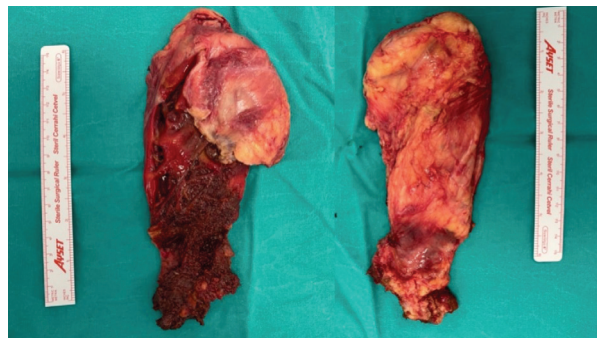


**FIG. 1.** (a) X-ray image of the knee demonstrating significant fluid accumulation, as evidenced by the increased opacity of the effusion that extends into the suprapatellar region. (b, c) T1-weighted sagittal magnetic resonance imaging (MRI) of the knee exhibits a hyperintense signal intensity indicative of increased fluid at the patellofemoral joint level. (c) T2-weighted sagittal MRI of the knee reveals thick septations and hypointense signal intensity due to hemosiderin deposition in the effusion. (d) Post-contrast sagittal MRI of the knee demonstrates heterogeneous contrast enhancement across the effusion.

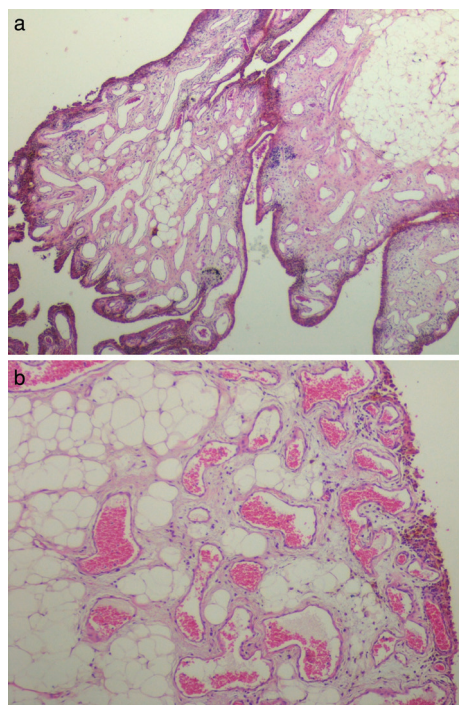


**FIG. 2.** (a) Axial proton density MRI reveals hypointense thick septations and hypointense signal alterations due to hemosiderin deposition. (b) Post-contrast axial MRI demonstrates heterogeneous contrast enhancement within the septa.

demonstrated a villonodular proliferation of the synovial tissue, which was enveloped by a highly pigmented synovial lining and a subsynovial fibrous tissue containing proliferated mature adipose tissue with intermingling proliferated dilated thin-walled blood vessels (Figure 4a). Although the synovium exhibited a substantial number of hemosiderin-laden histiocytes, contrary to PVNS, there were only a few scattered accompanying multinuclear histiocytes and a mild lymphocytic infiltrate (Figure 4b). Furthermore, the adipose and vascular elements of the subsynovial tissue were significantly greater than anticipated in PVNS. The highly



**FIG. 3.** Pigmented and spongy soft tissue mass exhibiting a predominantly villonodular growth pattern.



**FIG. 4.** Villous proliferation of synovial and subsynovial tissue, (a) Pronounced proliferation of vascular channels intermingling with the increased subsynovial fatty tissue and dense fibrous tissue between the vessels. Note the pigmented synovial lining (H&E, x40), (b) Increased subsynovial adipose tissue, pigmented synovial lining, and proliferation, dilation, and congestion in thin-walled vessels. Note the lack of multinucleated cells and lymphocytic infiltration (H&E, x100).

H&E, hematoxylin and eosin

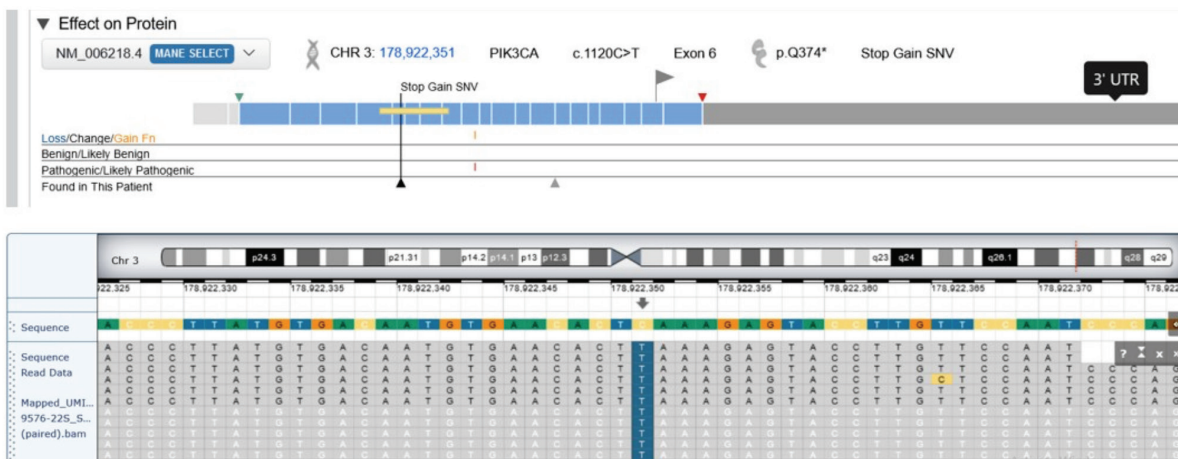


FIG. 5. Results of genetic analysis revealing PIK3CA mutation.

pigmented synovial lining and prominent perivascular fibrosis, along with vascular proliferation, ruled out lipoma arborescence. Additionally, the histopathologic findings did not satisfy the criteria established for an angioliipoma and a synovial hemangioma. Since all histomorphological findings were consistent with those of FAVA, a DNA-based mutation analysis was undertaken using the next generation sequencing (NGS) method with a panel of 56 genes to explore the PIK3CA mutation reported in FAVA (Figure 5). Simultaneously, an RNA-based molecular analysis was initiated in conjunction with the NGS method to investigate potential gene fusions. Genetic DNA analysis revealed a somatic PIK3CA mutation, which is consistent with the histopathological findings. The applied RNA genetic panel did not exhibit any pathogenic genetic variation.

Two years following the synovectomy, no residual lesion, recurrence, or dysfunction were observed except for a minor limitation in left knee function due to patellar maltracking.

**Informed Consent:** Informed consent were obtained from the patient.

**Authorship Contributions:** Supervision- U.U.; Materials- U.U., M.A.M., G.B., F.E.U., M.Ç.; Data Collection or Processing- U.U., M.A.M., G.B., F.E.U., M.Ç.; Analysis or Interpretation- U.U.; Literature Search- U.U., M.A.M., G.B., F.E.U., M.Ç.; Writing- U.U., M.A.M., G.B., F.E.U., M.Ç.; Critical Review- U.U.

**Conflict of Interest:** No conflict of interest was declared by the authors.

## REFERENCES

1. Alomari AI, Spencer SA, Arnold RW, et al. Fibro-adipose vascular anomaly: clinical-radiologic-pathologic features of a newly delineated disorder of the extremity. *J Pediatr Orthop.* 2014;34:109-117. [\[CrossRef\]](#)
2. Driskill JH, Hwang H, Callan AK, Oliver D. Case Report of Fibro-Adipose Vascular Anomaly (FAVA) with Activating Somatic PIK3CA Mutation. *Case Rep Genet.* 2022;2022:9016497. [\[CrossRef\]](#)
3. Fernandez-Pineda I, Marcilla D, Downey-Carmona FJ, Roldan S, Ortega-Laureano L, Bernabeu-Wittel J. Lower Extremity Fibro-Adipose Vascular Anomaly (FAVA): A New Case of a Newly Delineated Disorder. *Ann Vasc Dis.* 2014;7:316-319. [\[CrossRef\]](#)
4. Ferreira J, López Gutiérrez JC, Carneiro A, et al. Lower Extremity Fibro-Adipose Vascular Anomaly-Case Report. *Ann Vasc Surg.* 2020;66:671.e15-671.e18. [\[CrossRef\]](#)
5. Parmar B, Joseph JS, G KI, et al. Fibro-Adipose Vascular Anomaly: A Case Report and Literature Review. *Cureus.* 2022;14:e30757. [\[CrossRef\]](#)
6. Hori Y, Hirose K, Aramaki-Hattori N, et al. Fibro-adipose vascular anomaly (FAVA): three case reports with an emphasis on the mammalian target of rapamycin (mTOR) pathway. *Diagn Pathol.* 2020;15:98. [\[CrossRef\]](#)
7. Barwad A, Narwal A, Dutta R, et al. Fibro-Adipose Vascular Anomaly (FAVA): Not Another Vascular Anagram. *Int J Surg Pathol.* 2023;10668969231188419. [\[CrossRef\]](#)
8. Luks VL, Kamitaki N, Vivero MP, et al. Lymphatic and other vascular malformative/overgrowth disorders are caused by somatic mutations in PIK3CA. *J Pediatr.* 2015;166:1048-54.e1-5. [\[CrossRef\]](#)
9. Merrow AC, Gupta A, Patel MN, Adams DM. 2014 2014 Revised Classification of Vascular Lesions from the International Society for the Study of Vascular Anomalies: Radiologic-Pathologic Update. *Radiographics.* 2016;36:1494-1516. [\[CrossRef\]](#)
10. Khera PS, Garg PK, Babu S, Elhence P, Tiwari S, Nk S. Fibro Adipose Vascular Anomaly: A Rare and Often Misdiagnosed Entity. *Indian J Radiol Imaging.* 2021;31:776-781. [\[CrossRef\]](#)