



# A Novel Approach for the Treatment of Subclavian Steal Syndrome in a Patient Undergoing Coronary Artery Bypass Grafting

✉ Mesut Engin<sup>1</sup>, ✉ Yusuf Ata<sup>1</sup>, ✉ Ufuk Aydın<sup>1</sup>, ✉ Hasan Arı<sup>2</sup>, ✉ Tamer Türk<sup>3</sup>

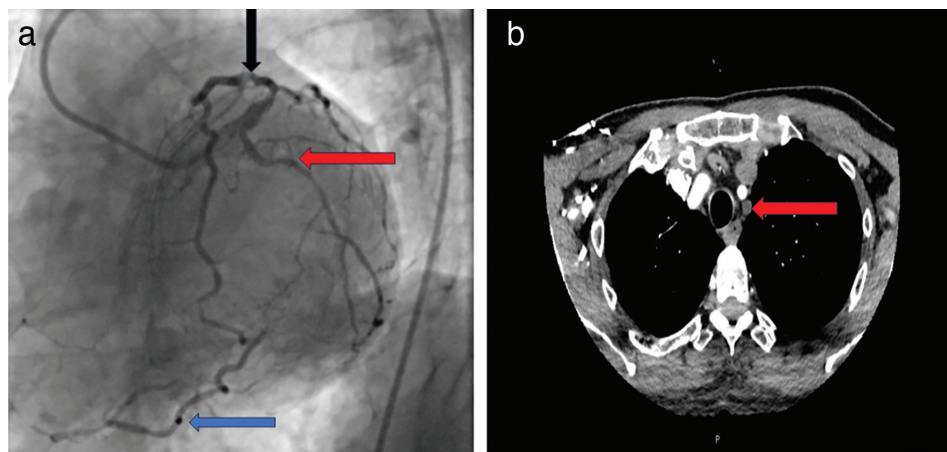
<sup>1</sup>Clinic of Cardiovascular Surgery, University of Health Sciences Türkiye, Bursa Yüksek İhtisas Training and Research Hospital, Bursa, Türkiye

<sup>2</sup>Clinic of Cardiology, University of Health Sciences Türkiye, Bursa Yüksek İhtisas Training and Research Hospital, Bursa, Türkiye

<sup>3</sup>Clinic of Cardiovascular Surgery, VM Medicalpark Bursa Hospital, Bursa, Türkiye

A 59-year-old male was admitted to our clinic for complaints of exercise-induced angina. A coronary angiography and three-vessel coronary artery bypass graft (CABG) surgery was planned (Figure 1a). He reported a medical history of chronic obstructive pulmonary disease (COPD), peripheral arterial disease, and hypertension. A preoperative carotid Doppler ultrasonography revealed a reversal in flow in the left vertebral artery. A computed tomography angiography (CTA) was performed, which revealed a completely occluded left subclavian artery (LSA) (Figure 1b). Thus, the patient was diagnosed with subclavian steal syndrome (SSS). Differences in the blood pressure between the right (135/82 mmHg) and left (85/42 mmHg) arms were also detected. The patient also complained of presyncope and vertigo. Based on the preoperative evaluation findings, three-vessel CABG and LSA revascularization were planned. Under general

anesthesia, a median sternotomy was performed, and the left internal thoracic artery (LITA) and saphenous vein were harvested. The three-vessel [right, circumflex, and left anterior descending (LAD) coronary arteries] CABG was performed with saphenous vein grafts while the patient was connected to the cardiopulmonary bypass (CPB) machine. Subsequently, the distal end of the LITA was anastomosed to the ascending aorta to achieve LSA revascularization (Figure 2a). The surgery was uneventful with aortic cross-clamp and CPB times of 71 and 103 min, respectively. The patient was discharged on the sixth postoperative day. Six months later, CTA revealed a patent LITA graft (Figure 2b). The LITA remained patent in the control angiography obtained one year after the surgery (Figure 2c). Furthermore, the pressure difference between the patient's two arms had decreased significantly (right arm: 125/72 mmHg, left arm: 122/70 mmHg). In



**FIG. 1.** (a) Cardiac catheterization revealed three-vessel disease (blue arrow: posterior descending branch of the total occluded right coronary artery, red arrow: circumflex artery, black arrow: left anterior descending artery). (b) Axial image of computed tomography angiography showing a completely occluded left subclavian artery (red arrow).

**Corresponding author:** Mesut Engin, Clinic of Cardiovascular Surgery, University of Health Sciences Türkiye, Bursa Yüksek İhtisas Training and Research Hospital, Bursa, Türkiye

**e-mail:** mesut\_kvc\_cor@hotmail.com

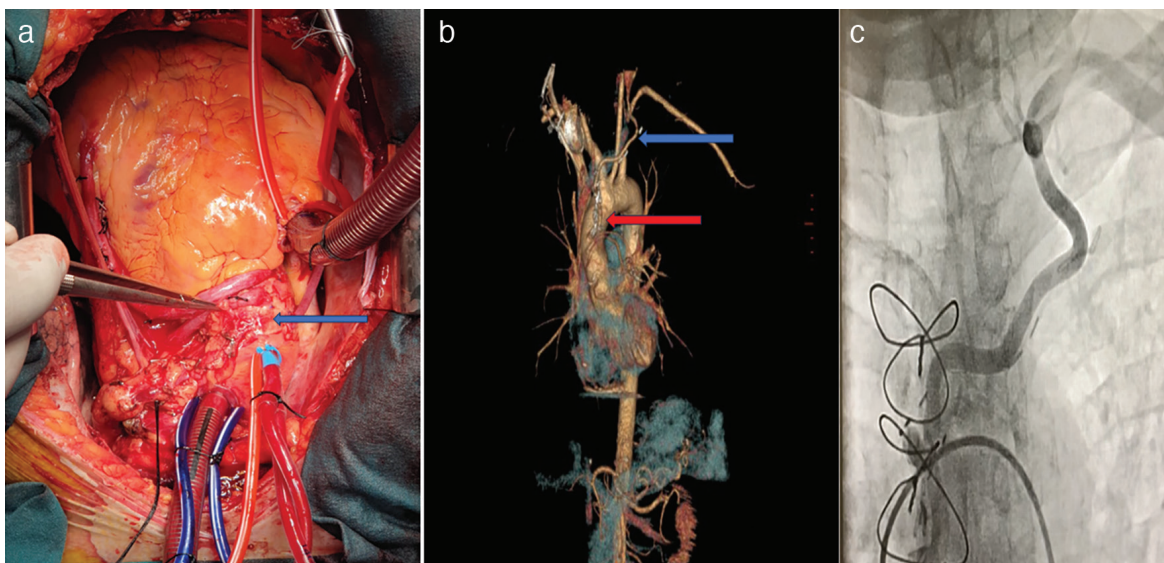
**Received:** November 04, 2024 **Accepted:** November 21, 2024 **Available Online Date:** xxxxxx • **DOI:** 10.4274/balkanmedj.galenos.2024.2024-11-4

Available at [www.balkanmedicaljournal.org](http://www.balkanmedicaljournal.org)

**ORCID iDs of the authors:** M.E. 0000-0003-2418-5823; Y.A. 0000-0002-1105-5862; U.A. 0000-0002-4083-6211; H.A. 0000-0002-9681-2374; T.T. 0000-0001-6747-0611.

**Cite this article as:** Engin M, Ata Y, Aydın U, Arı H, Türk T. A Novel Approach for the Treatment of Subclavian Steal Syndrome in a Patient Undergoing Coronary Artery Bypass Grafting. *Balkan Med J*;

Copyright@Author(s) - Available online at <http://balkanmedicaljournal.org/>



**FIG. 2.** (a) Anastomosis between the LITA and ascending aorta (blue arrow). (b) Control computed tomography angiography obtained 6 months after the operation shows a patent LITA (blue arrow) and the anastomosis between the LITA and ascending aorta. (c) Control angiography obtained one year after the surgery shows a patent LITA.

LITA, left internal thoracic artery.

the postoperative period, no neurological symptoms were detected in the patient.

An in situ LITA graft is the best option for LAD artery revascularization. However, studies have demonstrated that a well-prepared saphenous vein graft are similar to arterial grafts.<sup>1</sup> Furthermore, a recent study demonstrated similar long-term survival outcomes in patients in whom a saphenous vein graft and patients in whom a LITA was used for LAD revascularization.<sup>2</sup> Graft patency is affected by several factors such as the characteristics of the graft, quality of the anastomosis, structure of the anastomotic coronary artery, kinking of the grafts, and area of the coronary artery distal bed. The right internal thoracic artery could have also been used in our patient. However, it was not used because our patient suffered from COPD and right iliac artery disease. Furthermore, the radial artery could not be used for LAD revascularization because of the left upper extremity occlusive artery disease. In the right upper limb, the radial artery was the dominant artery of the forearm. Thus, saphenous vein grafts were used as coronary grafts in our patient, and an in situ LITA was used for LSA revascularization.

In conclusion, in-situ LITA grafts may be used for SSS in carefully selected patients. This method is described as the “ATA technique.”

**Informed Consent:** Written informed consent was obtained from the patient.

**Authorship Contributions:** Concept- M.E., Y.A., U.A.; Design- M.E., Y.A., U.A.; Supervision- M.E., Y.A., U.A.; Fundings- M.E., Y.A., U.A.; Materials- M.E., Y.A.; Data Collection or Processing- H.A., T.T.; Analysis and/or Interpretation- H.A., T.T.; Literature Search- M.E., Y.A., H.A., T.T.; Writing- M.E., Y.A., H.A., T.T.; Critical Review- M.E., Y.A., U.A., H.A., T.T.

**Conflict of Interest:** No conflict of interest was declared by the authors.

## REFERENCES

1. Dreifaldt M, Mannion JD, Geijer H, Lidén M, Bodin L, Souza D. The no-touch saphenous vein is an excellent alternative conduit to the radial artery 8 years after coronary artery bypass grafting: A randomized trial. *J Thorac Cardiovasc Surg.* 2021;161:624-630. [\[CrossRef\]](#)
2. Luthra S, Masraf H, Mohamed ME, et al. Left internal thoracic artery versus saphenous vein grafts to left anterior descending artery after isolated coronary artery bypass surgery. *Life (Basel).* 2024;14:385. [\[CrossRef\]](#)