



# Is MINOCA Syndrome Causing Fatal Left Ventricular Aneurysms Less Innocent than It Appears?

Cihan Öztürk<sup>1</sup>, Gökay Taylan<sup>1</sup>, Fethi Emre Ustabaşoğlu<sup>2</sup>, Turan Ege<sup>3</sup>

<sup>1</sup>Department of Cardiology, Trakya University Faculty of Medicine, Edirne, Turkey

<sup>2</sup>Department of Radiology, Trakya University Faculty of Medicine, Edirne, Turkey

<sup>3</sup>Department of Cardiovascular Surgery, Private Medikent Hospital, Kırklareli, Turkey

Myocardial infarction with non-obstructive coronary arteries (MINOCA) is clinically defined by the universal acute myocardial infarction (AMI) criteria, absence of obstructive coronary artery disease ( $\geq 50\%$  stenosis), and no overt cause for the presentation at angiography.<sup>1</sup> The underlying causes of MINOCA vary widely. However, excessive focus on determining etiology has resulted in limited clinical efforts.<sup>2</sup> Consequently, unexplained cases of MINOCA present challenges in risk stratification. Recent studies show that cardiac magnetic resonance imaging (CMR) identifies underlying causes in 87% of patients with MINOCA.<sup>3</sup> Given difficulties in CMR access, potential evaluation issues, rising healthcare costs, and economic constraints, diagnostic challenges have gained precedence.

Several studies indicate that MINOCA has a consistently better prognosis than AMI.<sup>1,3-5</sup> However, MINOCA's diverse etiologies<sup>6</sup> complicate generalization of findings for diagnosis and treatment, meaning prognosis is not as benign as it may seem. Patients with MINOCA frequently experience recurrent symptoms, with 16% reporting worsening or persistent chest pain within 5 years.<sup>7</sup> Some patients progress to occlusive coronary artery disease,<sup>8</sup> so persistent chest pain should not be assumed to be MINOCA-related.

Left ventricular aneurysms, a potentially fatal condition, can lead to heart failure, systemic embolism, ventricular arrhythmia, and cardiac rupture, typically following AMI. The likelihood of aneurysm

development increases with prolonged symptom-balloon time after AMI, and correlating symptom-balloon time with the patient's syntax score enhances predictive value.<sup>9</sup>

While left ventricular apical aneurysms are rare in MINOCA,<sup>10</sup> they have not previously been reported to cause left ventricular basal pseudoaneurysms. A left ventricular basal pseudoaneurysm with intraoperative imaging (Figure 1a-f) was identified in a 40-year-old female with chest pain diagnosed with non-ST-elevation myocardial infarction. Normal coronary arteries were observed, leading to a MINOCA diagnosis. A left ventricular basal pseudoaneurysm was confirmed by cardiac computed tomography (CT) and CMR, leading to referral for surgical treatment.

Post-AMI left ventricular aneurysms are associated with more complications, longer hospital stays, higher costs, and lower discharge likelihood.<sup>9</sup> However, data on ventricular aneurysms post-MINOCA are lacking. With improvements in MINOCA diagnosis and growing professional interest, we anticipate more knowledge and experience on MINOCA and its complications.

**Corresponding author:** Cihan Öztürk, Department of Cardiology, Trakya University Faculty of Medicine, Edirne, Turkey

**e-mail:** dr.cihanozturk@gmail.com

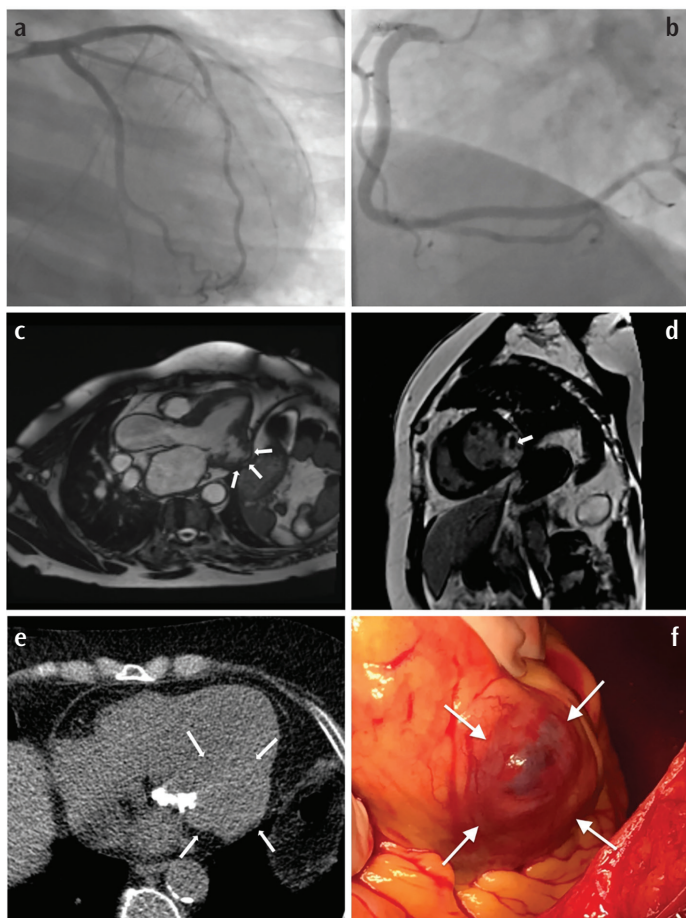
**Received:** July 30, 2024 **Accepted:** October 19, 2024 **Available Online Date:** xxxxxx • **DOI:** 10.4274/balkanmedj.galenos.2024.2024-7-116

Available at [www.balkanmedicaljournal.org](http://www.balkanmedicaljournal.org)

**ORCID iDs of the authors:** C.Ö. 0000-0001-8694-1693; G.T. 0000-0002-7015-4537; FE.U. 0000-0002-0340-4487; T.E. 0000-0002-2675-4447.

**Cite this article as:** Öztürk C, Taylan G, Ustabaşoğlu FE, Ege T. Is MINOCA Syndrome Causing Fatal Left Ventricular Aneurysms Less Innocent than It Appears?. *Balkan Med J*;

Copyright@Author(s) - Available online at <http://balkanmedicaljournal.org/>



**FIG. 1.** (a, b) Coronary angiography shows normal coronary arteries. (c) A 3-chamber image reveals a left ventricular aneurysm (arrows) measuring  $41 \times 23$  mm. (d) A short-axis late gadolinium enhancement image shows a non-enhanced lesion (arrow) within the aneurysm sac, possibly thrombus or calcification. (e) Non-contrast CT shows no calcification within the aneurysm sac (white arrows), suggesting the lesion is thrombus (note: calcifications in the image are on the mitral valve). (f) Intraoperative image of the left ventricular basal pseudoaneurysm. CT, computed tomography.

**Informed Consent:** Informed consent was obtained from all individual participants included in the study.

**Authorship Contributions:** Concept- C.Ö., G.T.; Design- C.Ö., G.T.; Supervision- C.Ö., G.T., F.E.U.; Fundings- C.Ö., G.T., F.E.U.; Materials- C.Ö., G.T., F.E.U., T.E.; Data Collection or Processing- C.Ö., G.T., F.E.U., T.E.; Analysis or Interpretation- C.Ö., G.T., F.E.U., T.E.; Literature Search- C.Ö., G.T., F.E.U., T.E.; Writing- C.Ö., G.T., F.E.U., T.E.; Critical Review- C.Ö., G.T., F.E.U., T.E.

**Conflict of Interest:** No conflict of interest was declared by the authors.

## REFERENCES

1. Pasupathy S, Air T, Dreyer RP, Tavella R, Beltrame JF. Systematic review of patients presenting with suspected myocardial infarction and nonobstructive coronary arteries. *Circulation*. 2015;131:861-870. [CrossRef]
2. Davis EF. Updates in the definition, diagnostic work up, and therapeutic strategies for MINOCA. *Current Treatment Options in Cardiovascular Medicine*. 2020;22:1-11. [CrossRef]
3. Pathik B, Raman B, Mohd Amin NH, et al. Troponin-positive chest pain with unobstructed coronary arteries: incremental diagnostic value of cardiovascular magnetic resonance imaging. *Eur Heart J Cardiovasc Imaging*. 2016;17:1146-1152. [CrossRef]
4. Niccoli G, Scalone G, Crea F. Acute myocardial infarction with no obstructive coronary atherosclerosis: mechanisms and management. *Eur Heart J*. 2015;36:475-481. [CrossRef]
5. Yalta K, Madias JE, Kounis NG, et al. Takotsubo syndrome: an international expert consensus report on practical challenges and specific conditions (part-1: diagnostic and therapeutic challenges). *Balkan Med J*. 2024;41:421-441. [CrossRef]
6. Yalta K, Madias JE, Kounis NG, et al. Takotsubo syndrome: an international expert consensus report on practical challenges and specific conditions (part-2: specific entities, risk stratification and challenges after recovery). *Balkan Med J*. 2024;41:442-457. [CrossRef]
7. Sharaf B, Wood T, Shaw L, et al. Adverse outcomes among women presenting with signs and symptoms of ischemia and no obstructive coronary artery disease: findings from the National Heart, Lung, and Blood Institute-sponsored Women's Ischemia Syndrome Evaluation (WISE) angiographic core laboratory. *Am Heart J*. 2013;166:134-141. [CrossRef]
8. Nordenskjöld AM, Lagerqvist B, Baron T, et al. Reinfarction in patients with myocardial infarction with nonobstructive coronary arteries (MINOCA): coronary findings and prognosis. *Am J Med*. 2019;132:335-346. [CrossRef]
9. You J, Gao L, Shen Y, et al. Predictors and long-term prognosis of left ventricular aneurysm in patients with acute anterior myocardial infarction treated with primary percutaneous coronary intervention in the contemporary era. *J Thorac Dis*. 2021;13:1706-1716. [CrossRef]
10. Li B, Ming Z, Wu J, Zhang M. Nonobstructive coronary artery myocardial infarction complicated by heart failure, ventricular aneurysm, and incessant ventricular arrhythmia: a case report. *Medicine (Baltimore)*. 2019;98:e13995. [CrossRef]