



Imiquimod and Lentigo Maligna: Can Severe Inflammation Be the Endpoint in Short-Term Use?

Seher Bostancı, Bengü Nisa Akay, Devrim Deniz Kuşçu, Ayşe Öktem

Department of Dermatology, Ankara University Faculty of Medicine, Ankara, Türkiye

Lentigo maligna (LM), an in situ form of melanoma, predominantly occurs on sun-exposed regions like the head and neck, progresses slowly, and displays variable pigmentation. While surgical excision is the preferred treatment, topical imiquimod has gained attention as an alternative for cases where surgery is not an option.¹ Imiquimod functions by activating toll-like receptors, specifically TLR7 and TLR8, which trigger nuclear factor kappa B activation and promote cytokine release, enhancing the immune response against the tumor. However, a standardized protocol for its off-label use in LM treatment has yet to be established.² This report describes our clinic's protocol and outcomes with 5% topical imiquimod in three cases.

Three patients (aged 51, 79, and 80) with biopsy-confirmed facial LM lesions declined surgery due to comorbidities. Prior to starting treatment, informed consent was obtained. The treatment protocol consisted of applying 5% imiquimod 5 days per week, with adjustments based on the severity of irritation. If minimal irritation was noted, the application frequency was increased to 7 days per week, and topical retinoid therapy was added at night if the response remained suboptimal. In cases of severe irritation, imiquimod was paused for 1 week, during which wound care creams were recommended. Treatment was then resumed at five applications per week. Patients applied imiquimod a minimum of 30 times until dermatoscopic examination confirmed complete healing (Figure 1). Follow-up biopsies at 3-6 months showed complete regression, with no recurrence observed over 24-30 months of follow-up (Table 1; Figure 2).

LM poses unique challenges due to its slow progression and occurrence in cosmetically sensitive areas, necessitating careful treatment planning. While surgical excision remains the preferred treatment, alternatives like imiquimod offer viable options for patients who are not candidates for surgery.^{1,3,4}

In our analysis of three cases, we achieved favorable outcomes using 5% topical imiquimod over a shorter duration. The protocol involved applying imiquimod 5 days per week, with breaks during periods of severe irritation, leading to complete lesion regression in all cases after approximately 30 applications. This contrasts with the conventional recommendation of 12 weeks of treatment and at least 60 applications, suggesting that shorter courses may be effective.² Follow-up histopathological examinations at 3-6 months confirmed regression, with no recurrence observed during dermatoscopic follow-up at 24-30 months. This modified approach, which balances patient comfort and cosmetic outcomes, highlights the potential for shorter treatment durations while maintaining efficacy. Further studies are needed to establish optimal treatment regimens for LM.

This report highlights the importance of long-term follow-up in assessing treatment outcomes and recurrence rates. While our initial findings showed complete regression and no recurrence during short-term follow-up, we recognize the necessity of extended monitoring, as recurrences have been documented up to 4.3 years post-treatment.⁵ Longer follow-up periods will be crucial in determining the durability of treatment responses and the recurrence rates associated with short-term imiquimod use.

Corresponding author: Devrim Deniz Kuşçu, Department of Dermatology, Ankara University Faculty of Medicine, Ankara, Türkiye

e-mail: devrimdenizkuscu@gmail.com

Received: November 11, 2024 **Accepted:** December, 14, 2024 **Available Online Date:** xxxxxx • **DOI:** 10.4274/balkanmedj.galenos.2024.2024-11-27

Available at www.balkanmedicaljournal.org

ORCID iDs of the authors: S.B. 0000-0001-5213-1932; B.N.A. 0000-0002-4896-1666; D.D.K. 0000-0002-4758-2146; A.Ö. 0000-0003-3810-6188.

Cite this article as: Bostancı S, Akay BN, Kuşçu DD, Öktem A. Imiquimod and Lentigo Maligna: Can Severe Inflammation Be the Endpoint in Short-Term Use?. *Balkan Med J.*;

Copyright@Author(s) - Available online at <http://balkanmedicaljournal.org/>

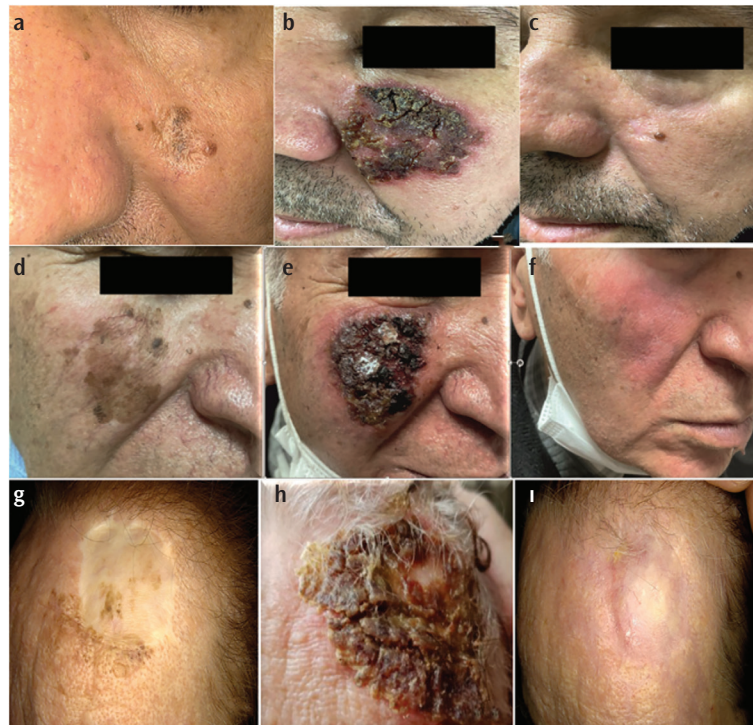

FIG. 1. Case 1: Initial presentation (a), severe inflammation during treatment (b), and complete resolution after treatment (c). Case 2: Initial presentation (d), severe inflammation during treatment (e), and complete resolution after treatment (f). Case 3: Initial presentation (g), severe inflammation during treatment (h), and complete resolution after treatment (i).

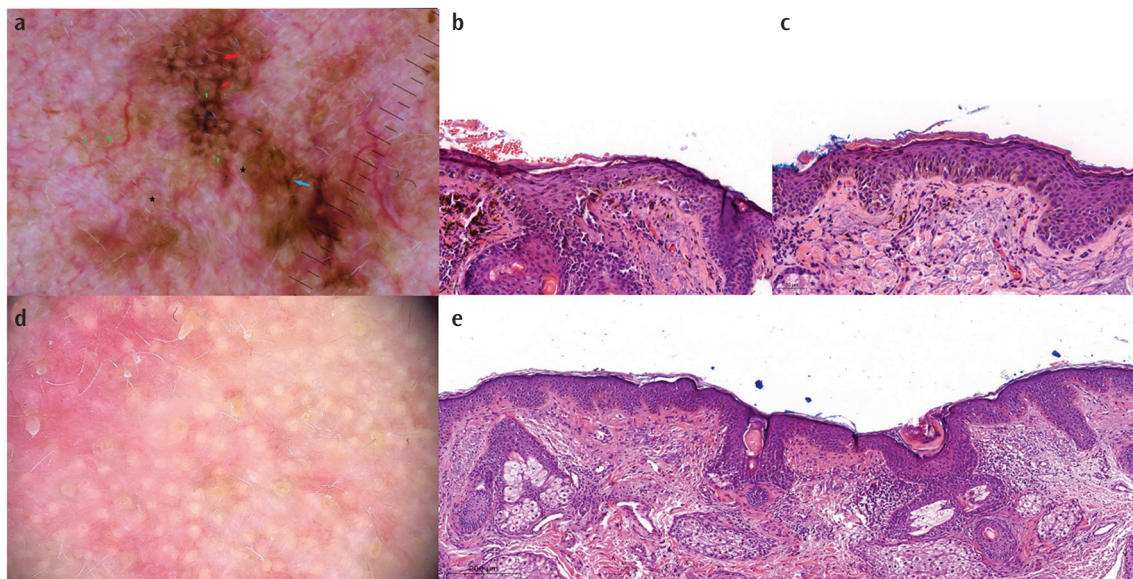


FIG. 2. Dermatoscopic image of lentigo maligna in Case 1 reveals angulated lines (blue arrow), rhomboidal structures (red arrow), brown-gray circles (green arrow), and circle-within-circle structures (black star) (a). Histopathological examination shows linear lentiginous atypical melanocytic proliferation with nuclear enlargement, hyperchromasia, and coarse melanin pigment (H&E x30) (b, c). Post-treatment dermatoscopy demonstrates complete tumor resolution (d), and while histopathology confirms the absence of residual melanocytic lesions (H&E x10.1) (e). H&E, hematoxylin and eosin.

TABLE 1. Lesion Characteristics and Treatment Protocol.

Age	Localization	Lesion status/ previous treatment	Duration of lesion at diagnosis	Reason for choosing imiquimod	Total imiquimod applications	Treatment protocol	Control biopsy	Relapse
51	Left malar	New lesion	2 years	Patient declined surgical treatment	30	Applied 5 days per week with a 2-day break; interrupted three times due to severe inflammation	Pathology: Complete cure (6 months post- treatment)	No relapse after 30 months
80	Right malar	New lesion	15 years	Lesion size and comorbidities	45	Initially 5 days/week for 4 weeks. Increased to 7 days/week after 20 applications due to insufficient irritation. Added topical retinoid at night. Severe inflammation after 2 weeks led to discontinuation of the retinoid. Resumed imiquimod 5 days/week and then stopped for 1 week due to severe inflammation, pain, and ulceration	Pathology: Complete cure (3 months post- treatment)	No relapse after 24 months
79	Left forehead	Recurrence at previous surgical excision site (13 years ago)	6 months	Patient declined surgical treatment	30	Applied 5 days per week with a 2-day break; interrupted twice due to severe inflammation	Pathology: Complete cure (6 months post- treatment)	No relapse after 30 months

Informed Consent: Prior to starting treatment, informed consent was obtained.

Authorship Contributions: Concept- S.B., B.N.A., D.D.K., A.Ö.; Design- S.B., B.N.A., D.D.K., A.Ö.; Supervision- S.B., B.N.A., D.D.K., A.Ö.; Data Collection or Processing- S.B., B.N.A., D.D.K., A.Ö.; Literature Search- S.B., B.N.A., D.D.K., A.Ö.; Writing- S.B., B.N.A., D.D.K., A.Ö.

Conflict of Interest: No conflict of interest was declared by the authors.

REFERENCES

1.

Vaienti S, Calzari P, Nazzaro G. Topical treatment of melanoma in situ, lentigo maligna, and lentigo maligna melanoma with imiquimod cream: a systematic review of the literature. *Dermatol Ther (Heidelb)*. 2023;13:2187-2215. [\[CrossRef\]](#)

2.

Guitera P, Waddell A, Paton E, et al. A practical guide on the use of imiquimod cream to treat lentigo maligna. *Australas J Dermatol*. 2021;62:478-485. [\[CrossRef\]](#)

3.

Daude M, Dinulescu M, Nguyen JM, et al. Efficacy of imiquimod in the management of lentigo maligna. *J Eur Acad Dermatol Venereol*. 2023;37:1785-1791. [\[CrossRef\]](#)

4.

Tio D, van der Woude J, Prinsen CAC, Jansma EP, Hoekzema R, van Montfrans C. A systematic review on the role of imiquimod in lentigo maligna and lentigo maligna melanoma: need for standardization of treatment schedule and outcome measures. *J Eur Acad Dermatol Venereol*. 2017;31:616-624. [\[CrossRef\]](#)

5.

Donigan JM, Hyde MA, Goldgar DE, Hadley ML, Bowling M, Bowen GM. Rate of recurrence of lentigo maligna treated with off-label neoadjuvant topical imiquimod, 5%, cream prior to conservatively staged excision. *JAMA Dermatol*. 2018;154:885-889. [\[CrossRef\]](#)