



# Differentiating Pectus Excavatum-Related RV Dysfunction from ARVD: The Role of Cardiac Imaging

Özge Özden Kayhan<sup>1</sup>, Cemre Turgul<sup>2</sup>, Çağla Akçay Ürkmez<sup>3</sup>, Gökhan Aksan<sup>4</sup>, Haşim Tüner<sup>1</sup>

<sup>1</sup>Clinic of Coronary Intensive Care Unit, Bahçelievler Memorial Hospital, İstanbul, Türkiye

<sup>2</sup>Department of Cardiology, Erciyes University Faculty of Medicine, Kayseri, Türkiye

<sup>3</sup>Clinic of Cardiology, Sakarya Training and Research Hospital, Sakarya, Türkiye

<sup>4</sup>Department of Cardiology, İstanbul University, İstanbul Faculty of Medicine, İstanbul, Türkiye

A 19-year-old male presented with intermittent palpitations and shortness of breath that were not associated with physical exertion. He had no documented history of cardiac disease. It is noteworthy that he had undergone surgical repair for pectus excavatum in 2018, followed by bar removal in 2020. The onset of his palpitations was reported to occur after the bar removal in 2020.

Physical examination and electrocardiography results were within normal limits. Transthoracic echocardiography revealed preserved left ventricular systolic function with an ejection fraction (EF) of 60% and mildly dilated right ventricular (RV) dimensions (RV basal diameter, 41 mm), along with borderline systolic function (TAPSE, 15 mm) (Figure 1a). Modified 4 chamber view and parasternal short axis aortic level view showed aneurysmatic right ventricle segment (Figure 1b, c). Cardiac magnetic resonance imaging showed significantly increased indexed RV volumes and global RV hypokinesia, with an EF of 42%. Furthermore, a large aneurysmal structure measuring 6 × 4.5 cm was identified in the RV apex on the inflow-outflow CINE image (Figure 1d, e). Although it was not remarkable on 4-chamber CINE image (Figure 1f) and short axis CINE image at the midventricular level (Figure 1g).

The initial differential diagnosis considered arrhythmogenic RV dysplasia (ARVD).

However, 72-h Holter monitoring did not detect any malignant arrhythmias, and genetic testing revealed no mutations linked to ARVD. In light of the absence of prominent arrhythmic symptoms, a negative family history of sudden cardiac death, and noncontributory genetic results, ARVD was ruled out. The observed RV dysfunction was instead attributed to the chronic mechanical impact of pectus excavatum.<sup>1</sup> Although this case involves multiple abnormalities, it does not correspond clearly to any established syndrome. The patient did not exhibit characteristic features of syndromic conditions known

to cause RV dysfunction, such as Marfan syndrome or Ehlers-Danlos syndrome. In the absence of identifiable syndromic traits, we do not interpret this case as part of a specific syndrome. Instead, the RV dysfunction is more plausibly attributed to the mechanical impact of pectus excavatum. Additional genetic testing and screening may help support this interpretation.

The suggested mechanism for RV dysfunction in pectus excavatum involves persistent cardiac compression between the sternum and the spine, resulting in RV remodeling and progressive impairment of function.<sup>1</sup> Owing to its anterior anatomical location, higher compliance, and non-concentric contraction pattern, the RV may be particularly susceptible to distortion, leading to global dysfunction.<sup>2</sup> The consideration of whether this represents a syndromic condition raises the possibility that the coexistence of RV dysfunction and structural chest wall anomalies may reflect a broader underlying disorder, such as a connective tissue disease or a congenital malformation syndrome. While the current presentation does not fit a defined syndrome, it remains plausible that the continued mechanical influence of pectus excavatum may contribute to more extensive systemic effects. Further investigation is necessary to determine whether such cases share a common pathophysiological basis.

Existing literature indicates that pectus excavatum can produce morphological changes that resemble those seen in ARVD, including RV apical aneurysms, outpouchings in the free wall, and midband hypertrophy.<sup>3</sup> Although prior studies have documented improvement in RV function following surgical repair<sup>4</sup>, our case is distinct in showing continued RV dysfunction even after bar removal, implying that pectus excavatum may result in irreversible RV damage in certain instances.<sup>5</sup> Pectus excavatum represents an underrecognized but potentially irreversible cause of RV dysfunction. It should be taken into account in patients with unexplained RV impairment, especially



**Corresponding author:** Özge Özden Kayhan, Clinic of Coronary Intensive Care Unit, Bahçelievler Memorial Hospital, İstanbul, Türkiye

**e-mail:** ozgeozdenctf@hotmail.com

**Received:** March 26, 2025 **Accepted:** May 19, 2025 **Available Online Date:**

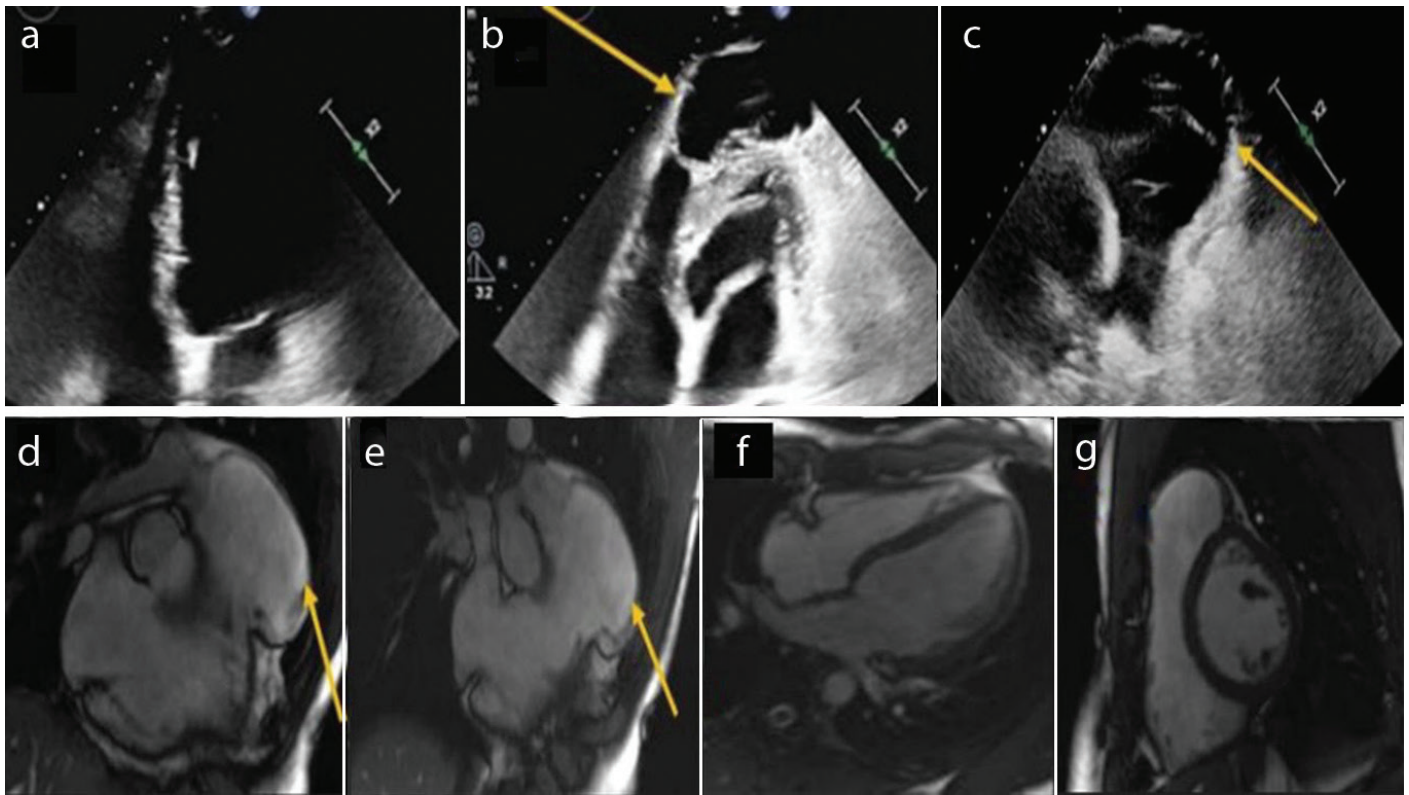
**DOI:** 10.4274/balkanmedj.galenos.2025.2025-3-133

Available at [www.balkanmedicaljournal.org](http://www.balkanmedicaljournal.org)

**ORCID iDs of the authors:** Ö.Ö.K. 0000-0003-4148-4366; C.T. 0009-0001-7814-0877; Ç.A.Ü. 0000-0003-0924-352X; G.A. 0000-0002-9637-1820; H.T. 0000-0003-2356-1460.

**Cite this article as:** Özden Kayhan Ö, Turgul C, Akçay Ürkmez Ç, Aksan G, Tüner H. Differentiating Pectus Excavatum-Related RV Dysfunction from ARVD: The Role of Cardiac Imaging. *Balkan Med J.* [Epub Ahead of Print]

Copyright©Author(s) - Available online at <http://balkanmedicaljournal.org/>



**FIG. 1.** (a) Transthoracic echocardiography apical 4 chamber view depicting mildly dilated right ventricle. (b) Modified apical 4 chamber transthoracic echocardiography view identifying aneurysmatic right ventricle segment at the right ventricle apex. (c) Parasternal short axis transthoracic echocardiographic view at the aortic level demonstrating aneurysmatic right ventricular segment. (d, e) Cardiac magnetic resonance imaging right ventricle inflow-outflow CINE images at different levels visualizing large aneurysmatic formation of right ventricle apex. (f) Cardiac magnetic resonance imaging 4 chamber CINE image indicating no significant right ventricular pathology. (g) Cardiac magnetic resonance imaging short axis CINE image at midventricular level revealing no significant right ventricular pathology.

those with a history of chest wall deformities. Morphological findings such as a rounded RV apex may aid in distinguishing this condition from other etiologies of RV dysfunction. A written informed consent was obtained from the patient for the publication of this clinical image.

**Informed Consent:** Informed consent was obtained from the patient for the publication of this report.

**Authorship Contributions:** Concept- Ö.Ö.K.; Design- Ö.Ö.K.; Analysis and/or Interpretation- H.T.; Literature Review- Ç.A.Ü., G.A., C.T.; Writing- C.T.

**Conflict of Interest:** No conflict of interest was declared by the authors.

## REFERENCES

1. Zhu J, Li X, Zhang Z, et al. The role of mechanical compression in the development of right ventricular dysfunction in pectus excavatum. *Eur Heart J Cardiovasc Imaging*. 2020;21(2):188-194. [\[CrossRef\]](#)
2. Kowalewski J, Brocki M, Drygas W. Impact of pectus excavatum on cardiac performance. *Eur J Cardiothorac Surg*. 2007;32(5):700-705. [\[CrossRef\]](#)
3. Kelly RE, Mellins RB, Shamberger RC, et al. Pectus excavatum deformity and its impact on cardiac function. *J Pediatr Surg*. 2010;45(5):987-993. [\[CrossRef\]](#)
4. Malek MH, Berger DE, Housh TJ, et al. Pulmonary and cardiac function after pectus excavatum repair. *Am J Respir Crit Care Med*. 2006;174(10):1353-1360. [\[CrossRef\]](#)
5. Maagaard M, Tang M, Ringgaard S, et al. Long-term cardiac function following pectus excavatum repair. *Ann Thorac Surg*. 2016;101(4):1196-1203. [\[CrossRef\]](#)