

Primary Hydatid Cyst of the Axillary Region: A Case Report

Haluk Recai Ünal¹, Erdinç Kamer¹, Türkan Rezanko², Özgür Kılıç¹, Mine Tunakan², Mehmet Ali Önal¹

¹Department of 4th General Surgery, İzmir Atatürk Training and Research Hospital, İzmir, Turkey

²Department of Pathology İzmir Atatürk Training and Research Hospital, İzmir, Turkey

ABSTRACT

Hydatid disease, which is caused by *Echinococcus granulosus*, is a common public health problem worldwide. The hydatid cysts may take many years to produce clinical symptoms. The liver is the organ most commonly affected. Diagnosis is made by a combination of clinical, imaging, serological and molecular techniques. Primary axillary hydatid disease is extremely rare and only 9 cases have been reported up to now. Herein, we reported a 48-year-old case with primary isolated hydatid disease in the axilla in whom total cystectomy was performed.

Key Words: Hydatid disease, soft tissue, axillary region

Received: 01.05.2009

Accepted: 19.06.2009

Introduction

Hydatid disease is caused by the larval tapeworm of the genus *Echinococcus* and still represents an important medical and surgical problem (1). *Echinococcus granulosus* is the most common species, but *Echinococcus multilocularis* and *Echinococcus oligarthus* also infest humans. Hydatid cysts develop most frequently (80%) in the liver. However, in 15% to 20% of the cases, the embryo passes through the capillary systems in the liver and lungs, reaches the general circulation, and passes to all viscera and soft tissues. For this reason, hydatid cysts may arise in atypical sites such as the orbit, urinary bladder, chest wall, subcutaneous tissue, tibia, parotid gland, breast, cervicofascial region, and thyroid (2-4). Primary axillary hydatid disease is extremely rare, with only nine previous case reports in the literature (5-13). Herein, we reported a case of a primary hydatid disease which originated in the subcutaneous tissue in the axillary region in a 48 year old female, which is fortunately not frequently found in surgical practice.

Case Report

A 48-year-old woman, a housewife who lived in a rural area, was admitted to our hospital with a painless mass in the left axillary region of two years duration. She had no history of injury, nipple discharge, breast mass, fever or any other symptoms. A dense semimobile and painless 4x4 cm mass was found in the left axillary fossa on physical examination. Routine haematologic and biochemical test results were normal. Ultrasonography revealed a 6x4 cm multiloculated cystic lesion with a thick wall and mobile

internal echoes in the left axillary fossa. Bilateral breast, whole abdominopelvic ultrasonographies and chest radiograms were normal. Computed tomography (CT) of the thorax demonstrated a 6x4x3 cm lobular calcified cystic mass with no significant invasion to the peripheral soft tissue, vascular or bone structures (Fig. 1). Fine needle aspiration (FNA) biopsy was performed and a clear fluid was obtained. The results of FNA cytology suggested hydatid disease. Aspiration cytology on microscopic examination showed the laminated membrane and hooklet (Fig. 2). An indirect echinococcal hemagglutination test was positive in dilutions up to 1/640 (a titer > 1/100 is considered positive result). Under general anesthesia, the cyst was excised completely without rupture, including the puncture site and subjacent subcutaneous tissue. On macroscopic examination, a multiloculed cyst with a calcified wall was seen. The cystic spaces contained a clear yellowish fluid and was surrounded completely with dense fibrous tissue. Light microscopic examination revealed the laminated chitinous membrane and confirmed a hydatid cyst (Fig. 3). The patient had an uneventful postoperative course, and she was discharged on the 3rd postoperative day. After surgery she was given treatment with albendazole for 6 months.

Discussion

Primary hydatid cysts are the result of a haematogenous dissemination of the embryos of *Echinococcus granulosus*, which pass through the capillary bed of the liver and lung, finally reaching more distant and atypical sites such as the kidney, orbit, heart, bone, spleen, muscle,

This case was presented at the 23-26 April 2009 Ege Surgical Congress

Address for Correspondence: Dr. Haluk Recai Ünalp, Department of 4th General Surgery, İzmir Atatürk Training and Research Hospital, İzmir, Turkey
Phone: +90 232 244 44 44 E-mail: halukunalp@gmail.com

brain, urinary bladder, chest wall, subcutaneous tissue, tibia, parotid, breast, cervicofascial region, and thyroid (2-5). As shown in the Table, primary axillary hydatid disease is extremely rare, with only nine previous case reports in the literature (5-13) (Table 1).

Uncomplicated hydatid disease is generally asymptomatic and usually occurs as a subcutaneous mass developing over a long period of time. The sonographic and tomographic appearances of axillary hydatid cyst are similar to those in other organs. Hydatid cyst may be unilocular at earlier stages, whereas older cysts are usually multilocular. They may either be made up of daughter cysts or have a solid appearance made up of multiple septated cysts. However, hyperintense hydatid cysts in the axillary region can be misdiagnosed as a soft tissue sarcoma or conglomerated lymphadenopathy (5). The differential diagnosis of the lesion should also include hematoma, abscess, lymphocele formation, breast cancer presenting as an axillary mass, or metastatic lesions. Imaging studies did not aid confirmation of a diagnosis of hydatid cysts in our case.

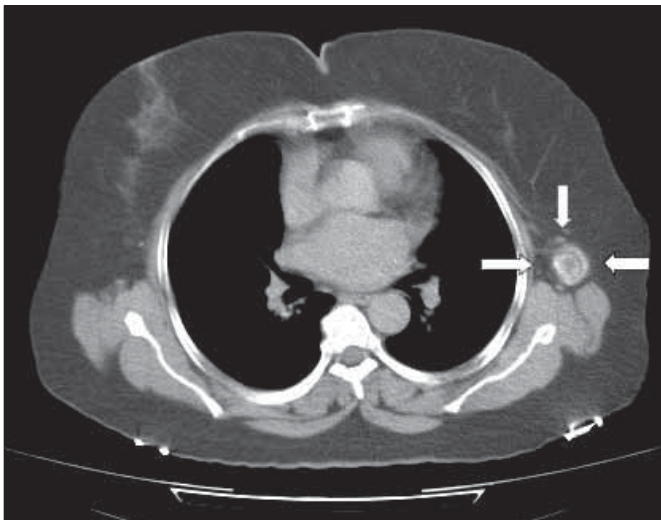


Figure 1. CT image shows a lobular calcified cystic 6x4x3 cm mass in left axillary region

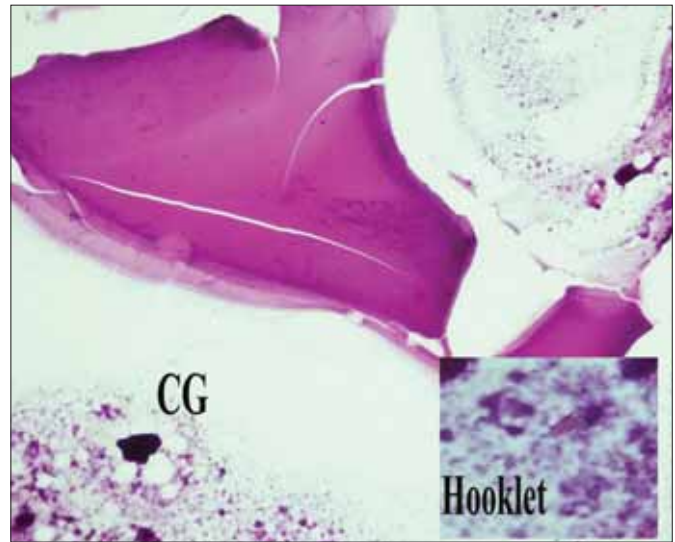


Figure 2. Remnants of laminated membrane, hooklets and calcified granules (CG) in cytological material (H&E X200)

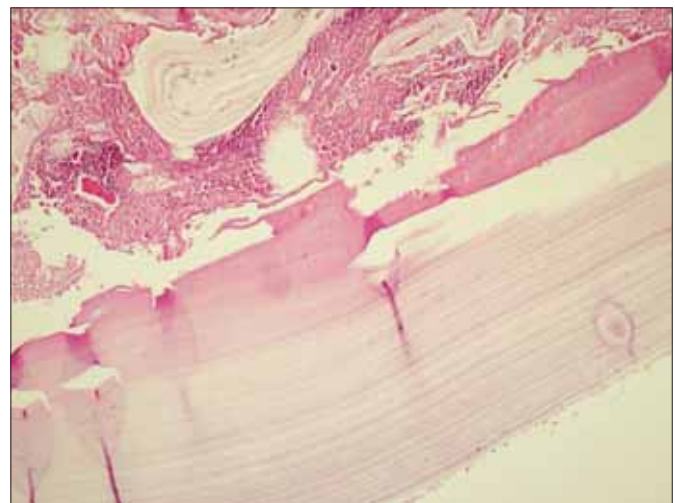


Figure 3. Histopathologic examination of surgically removed cyst showed laminated membrane (H&E X200)

Table 1. Reported cases of hydatid cysts of the axilla

Author	Year	Age /gender	Origin of cysts	Daughter cysts	Organ involvement	Screening	Follow up
Michel-Bechet. ⁵	1963	36/F	Left thoracic wall	Multiple	None	CXR, LP	NA
Remignon et al. ⁶	1965	75/F	Left major pectoral muscle	None	None	CXR	NA
Lamotte et al. ⁷	1967	32/M	Right axillary vein	Multiple	None	CXR, RS	NA
Mayol Martinez et al. ⁸	1994	67/F	Muscles	Multiple	None	CXR, US	NA
Sapunar and Bahamondes. ⁹	1995	63/M	Right humerus	Multiple	None	CXR, US	NA
Zamfir et al. ¹⁰	1997	11/F	Left neurovascular bundle	None	None	CT, US	NA
Navarro Martin et al. ¹¹	1998	84/M	NA	Multiple	None	CXR,US,CT	NA
Unal et al. ¹²	2001	53/F	Right pectoral muscle	None	None	CXR, US, CT	9 months
Losanoff et al. ¹³	2004	38/M	Subcutaneous tissue	NA	None	NA	NA

F: Female, M: Male, CT: Computed tomography, CXR: Chest X-ray, LP: Laparoscopy, RS: Radionuclide scintigraphy, US: Ultrasonography, NA: Data not available

Indirect hemagglutination tests may help to confirm the diagnosis of hydatid disease. Although the positive serum reactions may occur even in the absence of an associated hydatid cyst, abdominal ultrasonography and a plain chest radiography are mandatory to detect liver and lung involvement (3). Direct x-rays and imaging studies showed no other involvement in our patient. In routine practice, the accurate diagnosis in patient with soft tissue hydatidosis is frequently delayed until the time of FNA cytology or histopathologic examination after surgery. Although the routine use of FNA cytology for the diagnosis of hydatid disease should be discouraged, this procedure may represent a real aid in the definitive diagnosis of clinically unsuspected hydatid cysts (14). FNA were carried out in our patient as we did not suspect it to be a case of hydatid cyst preoperatively. FNA cytology showed the laminated membrane and diagnostic hooklets. Diagnosis was confirmed by the postoperative histopathologic examination (3, 4). There were no complications related to FNA. The patient did not show any untoward allergic reaction following FNA biopsy. Fine needle aspiration biopsy in the evaluation of suspected hydatid disease appears to be a safe diagnostic approach (15).

Antiparasitic medication is widely used in the treatment protocols of surgery and may be helpful to reduce the cyst size and for elimination of the parasite. Currently, scolicalidal agents are used for this purpose before and/or after surgery. However, the experience with scolicalidal agents such as albendazole (400 mg/kg) and praziquantel (50 mg/kg) or a combination of these drugs in the treatment of soft-tissue hydatid disease is very limited and results of the medical treatment are far from being curative (16, 17). Due to the small size of the axillary cyst, calcified cyst wall (Type-V in Gharbi and Grade-V in WHO classification) and short interval between diagnosis and operation (4th days after diagnosis), we did not give any antiparasitic medication to this patient preoperatively.

Percutaneous treatment has become a serious alternative to surgery in most of the organs of the body such as the liver, lungs, kidney in patients with hydatid cysts. However, there is only one study in the literature describing the results of percutaneous treatment of soft-tissue hydatid cysts (17).

Surgery is still the most effective treatment for hydatid disease. The main purpose of the surgery is to prevent the patient from complications such as compression of surrounding structures, infection or rupture of the cyst. Total cystectomy with fibrous adventitia which allows removal of all parasitic elements without spillage of the contents of the cyst, is curative treatment for soft tissue hydatidosis. The thickness of a pericyst depends on the response of the host to the parasite and localization of cyst. Soft tissue cysts can be easily ruptured, therefore rupture of the cyst must be avoided to prevent recurrence (18). We performed total cystectomy without rupture easily in our case in spite of the anatomical distortion of the axillary region. However, very dense adhesions of the adventitia to major vessels or nerves may be found in such cases. In this

condition, according to our experience as surgeons in an endemic region, partial pericystectomy and evacuation of the cystic content should be performed, avoiding the area near the major vessels or nerves in order to prevent their surgical damage.

In conclusion, when a palpable mass is detected in the axillary region, although very rare, the possibility of a hydatid cyst also should be kept in mind in the differential diagnosis, especially in endemic regions.

Conflict of Interest

No conflict of interest was declared by the authors.

References

1. Albayrak D, Sezer YA, İbiş AC, Yağcı MA, Hatipoğlu AR, Coşkun İ. Karaciğer Kist Hidatik Olgularımız. *Trakya Univ Tip Fak Derg* 2008;25:95-9.
2. Bengisun U, Ozaslan C, Kutlay J, Çamur A, Demirci S. Primary hydatid cyst of the breast. *Eur J Surg* 1983;159:503-4.
3. Yaghar RJ. Hydatid disease of the breast: a case report and literature review. *Am J Trop Med* 1999;61:714-5.
4. Acear T, Gomceli I, Güzel K, Yazgan A, Aydın R. Isolated hydatid cyst of the breast. *SMJ* 2003;482:52-3.
5. Michel-Behcet Y. A rare case of axillary tumor. *Mars Chir* 1963;15:381-3.
6. Remignon M, Febvey M, Anglade JP. Apropos of a rare localization of hydatidosis. *Bull. Mens. Soc. Med. Mil. Fr* 1965;59:525-6.
7. Lamotte M, Perrotin J, Julliard A, Timsit G. Hydatid cysts of the soft tissues. Apropos of a case of hydatid cyst of the axilla. *Ann Chir* 1967;21:1463-7.
8. Mayol Martinez J, Gonzalez Noguera PJ, Peromingo Fresneda R, Alvarez Fernandez-Represa J. Mass localized in the axilla. *Rev Clin Esp* 1994;194:199-200.
9. Sapunar J, Bahamondes L. Hydatidosis of the humerus complicated with fracture, bacterial infection, fistula, and extraosseous localization. *Bol. Chil. Parasitol* 1995;50:37-41.
10. Zamfir T, Bălănescu R, Pătrăcuş T, Nicolau S, Dănilă V, Lascu M, et al. The diagnosis and surgical treatment in the case of 2 rare sites of hydatid cyst in children. *Chirurgia (Bucur)* 1997;92:413-5.
11. Navarro Martin LM, Pardo Lledias J, Galindo Perez I, Querol Prieto R. Diagnostico incidental de masa de localización subcutánea en región axilar. *Rev. Clin. Esp.* 1998;198:703-4.
12. Unal AE, Ulukent SC, Bayar S, Demirkan A, Akgül H. Primary hydatid cyst of the axillary region: report of a case. *Surg Today* 2001;319:803-5. [\[CrossRef\]](#)
13. Losanoff J, Richman B, Jones J. Primary hydatid cyst of the axilla. *ANZ J Surg* 2004;74:393-4. [\[CrossRef\]](#)
14. Giuffrè G, Mondello P, Inferrera A, Furchi A, Gentile HM, Speciale G. Unexpected cytological diagnosis of two cases of echinococcosis. *Pathologica* 1993;85:747-53.
15. Saenz-Santamaria J, Moreno-Casado J, Nuñez C. Role of fine-needle biopsy in the diagnosis of hydatid cyst. *Diagn Cytopathol* 1997;16:93.
16. Mohammed AE, Yaawy MI, Al Karawi MA. Combined albendazole and praziquantel versus albendazole alone in the treatment of hydatid disease. *Hepato-Gastroenterology* 1998;45:1690-4.
17. Akhan O, Gumus B, Akinci D, Karcaaltincaba M, Ozmen M. Diagnosis and Percutaneous Treatment of Soft-Tissue Hydatid Cysts. *Cardiovasc Intervent Radiol* 2007;30:419-25. [\[CrossRef\]](#)
18. Prousalidis J, Tzardinoglou K, Sgouradis L, Katsolis C, Aletras H. Uncommon sites of hydatid disease. *World J Surg* 1998;22:17-22. [\[CrossRef\]](#)