

Fibro-Osseous Pseudotumor of the Digits

Parmakların Fibro-Osseöz Psödötümörü

Ufuk USTA, Murat BAŞ, Nasuhi Engin AYDIN, Servet GÜREŞÇİ

Submitted / Başvuru tarihi: 13.09.2006 Accepted/ Kabul tarihi : 22.09.2006

Fibro-osseous pseudotumor of the digits is a conflicting and rare benign lesion leading to serious problems and conflicts in differential diagnosis, especially with extraskeletal osteosarcoma. A 57-year-old man presented with a painful swelling in the proximal phalange of his left index finger. Direct radiography taken on admission revealed a soft tissue swelling with suspicious calcification in the proximal phalange palmar aspect of the index finger of left hand. The excised specimen of, 2x1.5x0.7 cm was gray-white with a rough, somewhat irregular outer surface. Microscopic examination revealed a mesenchymal tumorous lesion with a partially degenerated and partially calcified/ossified myxoid stroma. There were cellular areas composed of fibroblastic spindle cells, with mild-moderate nuclear atypia and moderate mitotic activity. Those cellular areas also contained osteoclast like multinucleated giant cells forming disordered groups. The final diagnosis based on histopathologic, radiographic and clinical findings was fibro-osseous pseudotumor of the digits.

Key Words: Bone diseases/pathology; diagnosis, differential; fingers; osteosarcoma.

Parmakların fibro-osseöz psödötümörü özellikle iskelet dışı osteosarkom ile karışabilen ve ayırıcı tanıda ciddi sorunlara ve çelişkilere neden olabilen nadir bir benign lezyondur. Sol el işaret parmağında ağrılı şişme ile kliniğimize başvuran 57 yaşında erkek hastanın direkt radyografisinde sol el işaret parmağı proksimal falanks palmar bölgede şüpheli kalsifiye alanlar içeren yumuşak doku şişliği görüldü. Cerrahi olarak çıkartılan 2x1.5x0.7 cm boyutlarındaki biyopsi örneğinin gri beyaz renkte olduğu ve nispeten düzenli dış yüzeye sahip olduğu izlendi. Mikroskopik olarak mezenchimal nitelikler izlenen lezyon kısmen dejenere, kısmen kalsifiye/ossifiye mikroid stromaya sahipti. Hafif-orta derecede nükleer atipi ve nispeten sık mitoz bulunan hücresel fibroblastik alanlar ve bu alanların arasında düzensiz gruplar oluşturan osteoklast benzeri dev hücreler izlendi. Histopatolojik, radyografik ve klinik bulgular ışığında son tanı olarak olguya parmakların fibro-osseöz psödötümörü tanısı konuldu.

Anahtar Sözcükler: Kemik hastalıkları/patoloji; ayırıcı tanı; parmak; osteosarkom.

Fibro-osseous pseudotumor of the digits is a conflicting and rare benign lesion leading to serious problems in differential diagnosis, especially with extraskeletal osteosarcoma.^[1,2] It is considered to be an extraskeletal, nonmalignant, fibroblastic proliferation with foci of osseous differentiation of the soft tissue.^[3]

CASE REPORT

A 57-year-old right-hand dominant man presented with a painful swelling in the palmar aspect of the proximal phalange of his left index finger which continued since 2 years. There were no local signs of infection. Laboratory

studies revealed a normal white blood cell count and erythrocyte sedimentation rate and C-reactive protein concentration. There was no known history of a previous trauma. On palpation, the mass was hard and appeared fixed to the surrounding tissues. A plain radiogram taken on admission revealed a soft tissue swelling with suspicious calcification in the proximal phalange of the index finger of the left hand. The mass did not show any association with the underlying bone neither surgically, nor radiographically and was removed surgically with 0.3 cm safety margins (Fig. 1). The flexor tendon of the finger was also intact.

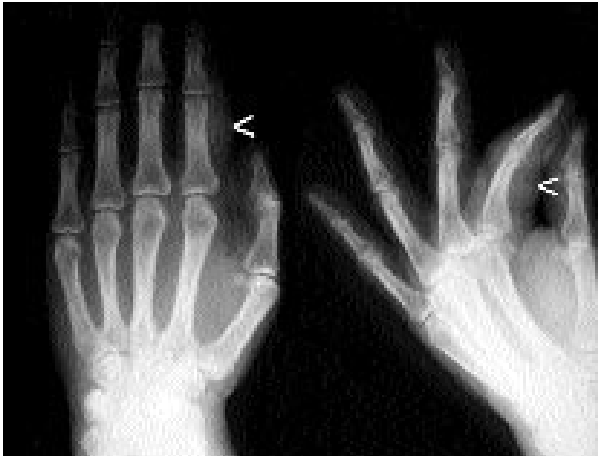

Fig. 1. Soft tissue swelling (arrow heads) in the index finger of left hand. There is no periosteal reaction in the underlying bone.

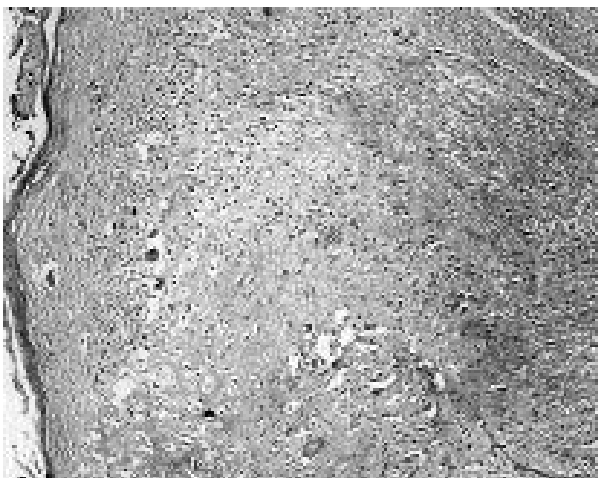

Fig. 2. Partially degenerated and partially calcified/ossified mesenchymal lesion with well defined borders (H-E x 40).

The specimen which was 2x1.5x0.7 cm in size, was gray-white with a rough, somewhat irregular outer surface. Its cut surfaces were heterogeneous, rubbery and had a gray-white color. Five micrometer-thick sections were obtained from the formalin fixed and paraffin embedded tissues and stained with hematoxylin and eosin.

Microscopic examination revealed a mesenchymal tumorous lesion with a partially degenerated and partially calcified/ossified myxoid stroma (Fig. 2). The randomly distributed cellular areas showed occasional lobular architecture. These cellular areas were composed of fibroblastic spindle cells, with mild nuclear atypia and moderate mitotic activity (Fig. 3). These areas also contained osteoclast-like multinucleated giant cells, either dispersed or forming disordered groups (Fig. 4).

Immunohistochemically, the spindle cells showed diffuse positivity for vimentin and focal and weak positivity for α -smooth muscle actin. Positive nuclear staining with Ki-67, a proliferation marker, was observed in 20% of the spindle cells. The lesion was uniformly negative for AE1/AE3, EMA, desmin and S-100 protein. The lesion was microscopically 0.1 cm away from the nearest surgical margin.

DISCUSSION

Ossifying pseudotumor of the digits, a synonym for fibro-osseous pseudotumor of the digits, was first described by Dupree and Enzinger^[1] as a

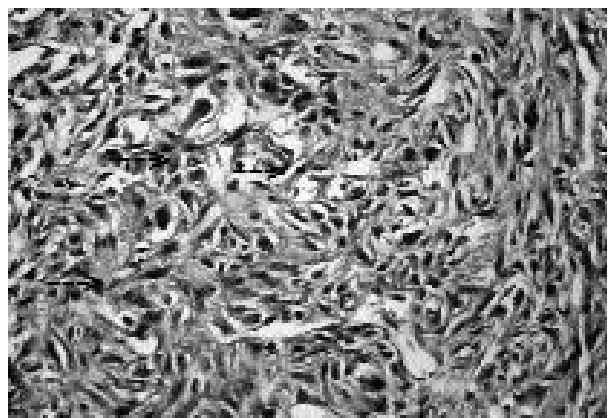


Fig. 3. Cellular fibroblastic area. Note mitotic figures (arrows), nuclear hyperchromasia and mild atypia in the nuclei of the spindle cells (H-E x 400).

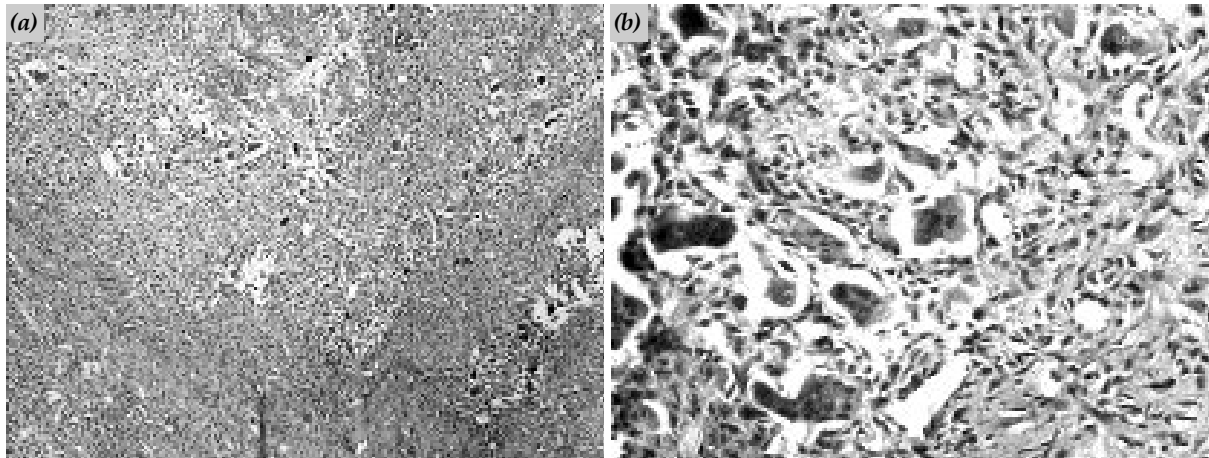


Fig. 4. Multinucleated giant cells intermingling with the spindle shaped, hyperchromatic, mesenchymal cells. (a) Panoramic view (H-E x 40) (b) Cellular details of the spindle shaped and multinucleated cells (H-E x 400).

unifying term. It is an unusual extraskeletal soft tissue process, histologically characterized by fibroblastic proliferation with reactive/metaplastic osteoid formation and calcification.^[4] The osteoid formation can be florid and immature, mimicking the appearance of malignant osteoid-forming neoplasms, thus the most common misdiagnosis is parosteal or extraskeletal osteosarcoma.^[3,5]

Microscopically, these tumor-like lesions closely resemble myositis ossificans, but unlike this process, they mainly involve the subcutaneous tissue and adjacent fibrous structures and are marked by an irregular multinodular growth pattern without the typical zoning of myositis ossificans.^[1] Fibroblastic proliferation showing varying degrees of cellular atypia is included among the histological characteristics of fibro-osseous pseudotumor of the digits.^[3]

In the presented case, soft tissue chondroma, extraskeletal osteosarcoma, low grade chondrosarcoma, tenosynovial giant cell tumor and borderline and benign histiocytic lesions were taken into consideration in the differential diagnosis. The localization of the lesion, absence of association with underlying bone, absence of atypical mitotic figures and absence of tumor necrosis were the key points for the exclusion of malignant lesions.

Thus, we regarded the lesion as benign. However, the nuclear atypia and moderate num-

ber of mitotic figures led us to exclude a benign neoplastic lesion. Immunohistochemically, the lesion proved to be mesenchymal without neuronal or muscular differentiation. Finally, we thought the lesion should be a reactive one and among the sought reactive lesions our final diagnosis, based on histopathologic, radiographic and clinical characteristics, was ossifying pseudotumor of the digits.

Follow-up information indicates that this lesion behaves in a nonaggressive fashion and is curable by complete local excision.^[1] But incomplete resection may lead to rapid recurrence of the mass with destruction of adjacent structures, including bone.^[5] There are several case reports in which the lesion was initially incorrectly diagnosed and the patient was treated by unnecessary radical surgery.^[2] Thus correct diagnosis excluding the probable malignant lesions is of extreme importance in cases of fibro-osseous pseudotumor of the digits.

We present this interesting and diagnostically difficult lesion because of the wide range of probable diagnoses and its importance in differential diagnosis.

REFERENCES

1. Dupree WB, Enzinger FM. Fibro-osseous pseudotumor of the digits. *Cancer* 1986;58:2103-9.
2. Nishio J, Iwasaki H, Soejima O, Naito M, Kikuchi M. Rapidly growing fibro-osseous pseudotumor of the digits mimicking extraskeletal osteosarcoma. *J Orthop Sci* 2002;7:410-3.

3. Takahashi A, Tamura A, Ishikawa O. A case of fibro-osseous pseudotumour of the digits. *Br J Dermatol* 2001;144:1274-5.
4. Sleater J, Mullins D, Chun K, Hendricks J. Fibro-osseous pseudotumor of the digit: a comparison to myositis ossificans by light microscopy and immunohistochemical methods. *J Cutan Pathol* 1996;23:373-7.
5. Chan KW, Khoo US, Ho CM. Fibro-osseous pseudotumor of the digits: report of a case with immunohistochemical and ultrastructural studies. *Pathology* 1993;25:193-6.