

Müllerian Cyst in Posterior Mediastinum in a Young Woman

Jung Eun Lee¹, Yoon Ki Cha¹, Jeung Sook Kim¹, Jin-ho Choi², Kang Min Han³

¹Department of Radiology, Dongguk University Ilsan Hospital, Goyang, South Korea

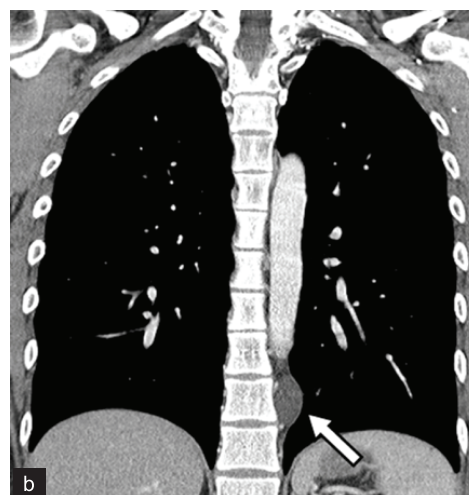
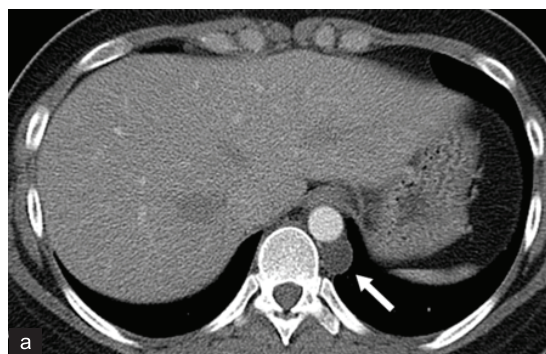
²Department of Thoracic and Cardiovascular Surgery, Dongguk University Ilsan Hospital, Goyang, South Korea

³Department of Pathology, Dongguk University Ilsan Hospital, Goyang, South Korea

A 22-year-old female visited our hospital for a routine checkup, and a mass was incidentally found on chest radiography. She denied any medical or family history and did not complain of any symptoms. Other than obesity, physical examinations and laboratory tests were unremarkable. Contrast-enhanced chest computed tomography (CT) depicted a 2.4 cm, well-defined ovoid thin-walled cyst in the left paravertebral space adjacent to the tenth vertebra (Figure 1a, 1b). Radiologic impression indicated a benign tumour, such as a neurogenic tumour with cystic change or a neurenteric cyst. She underwent tumour resection by video-assisted thoracoscopic surgery. The mass was an ovoid unilocular cyst with a thin, translucent wall containing clear watery fluid (Figure 1c).

At histologic examination, the cyst was lined by flattened, cuboidal or ciliated columnar epithelium supported by underlying fibrous stroma (Figure 1d). The epithelial lining of the cyst consisted of tubal type epithelium, supportive of Müllerian differentiation. On immunohistochemical staining, the epithelial lining was positive for estrogen receptor (ER), progesterone receptor (PR), and Wilm's Tumour 1 (WT1) (Figure 1e-1g). Finally, the cyst was diagnosed as a Müllerian cyst. She was discharged, and there was no recurrence for more than 1-year follow-up. Written informed consent was taken from the patient.

Cysts arising in the mediastinum are relatively rare, accounting for 12–30% of mediastinal masses (1). Müllerian cysts (also known as Hattori's cysts) developing in the mediastinum are even more uncommon, with only a few cases reported since first described in 2005 (2). Most Müllerian cysts in the mediastinum



have occurred in the perimenopausal period. In our case, the Müllerian cyst developed in a young woman, implying that it can be encountered at an earlier age. Obesity, gynecologic

Address for Correspondence: Dr. Yoon Ki Cha, Department of Radiology, Dongguk University Ilsan Hospital, Goyang, South Korea

Phone: 82-31-961-7831 e-mail: sublime256@naver.com

Received: 30 June 2017 Accepted: 27 November 2017 • DOI: [10.4274/balkanmedj.2017.0896](https://doi.org/10.4274/balkanmedj.2017.0896)

Available at www.balkanmedicaljournal.org

Cite this article as: Lee YE, Cha YK, Kim JS, Choi J, Han KM. Müllerian Cyst in Posterior Mediastinum in a Young Woman. *Balkan Med J Epub* February 2018

©Copyright 2017 by Trakya University Faculty of Medicine / The Balkan Medical Journal published by Galenos Publishing House.

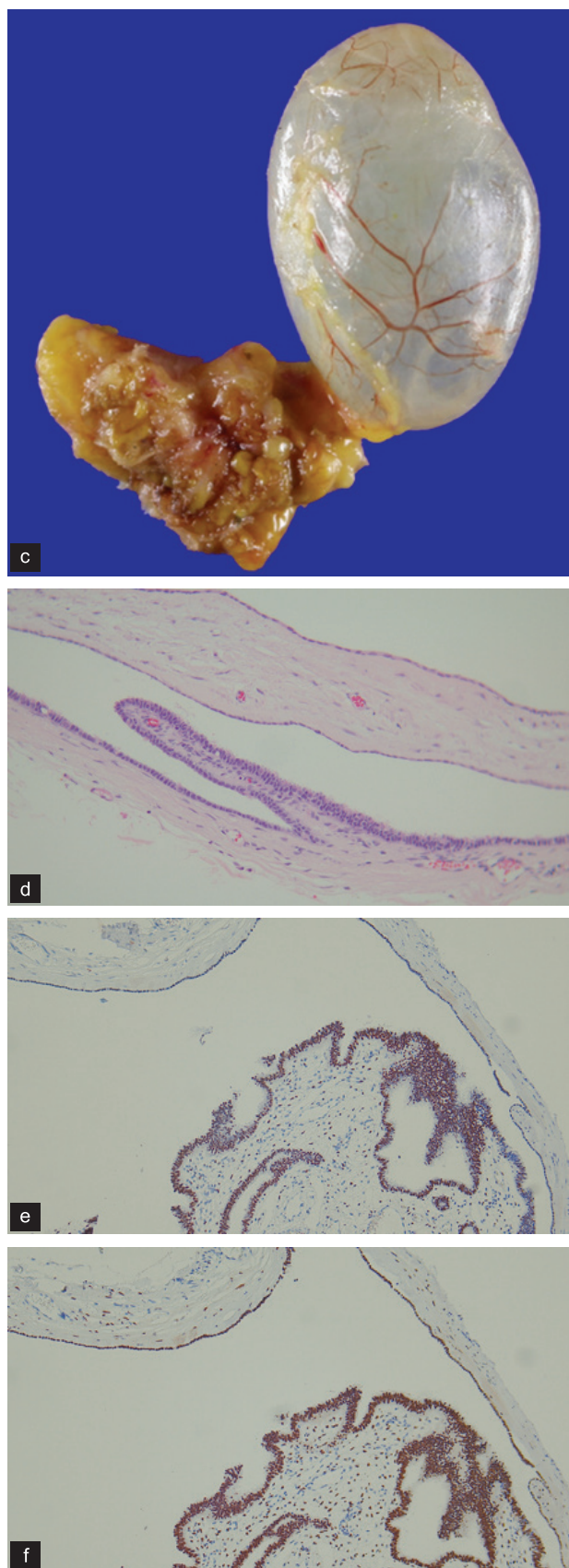

FIG. 1. a-g. Contrast-enhanced axial (a), and coronal (b) chest CT show a well-defined ovoid thin-walled cystic mass without enhancement (arrows) in the left paravertebral space adjacent to the tenth vertebra. The resected specimen (c) demonstrated a cyst with a thin, translucent wall containing clear watery fluid. On histological examination, the inner surface of the cyst was lined with flattened, cuboidal or ciliated columnar epithelium, and was supported by underlying fibrous stroma (d). Immunohistochemical stainings for estrogen receptor (e), progesterone receptor (f), and Wilm's tumour 1 (g) revealed positive nuclear staining (a: haematoxylin and eosin original magnification 200 \times ; b: ER 100 \times ; c: PR 100 \times ; d: WT1 100 \times).

history and hormone replacement therapy have been reported to be frequent in patients with these cysts (3). The origin of mediastinal Müllerian cysts has yet to be firmly described. Several theories have been proposed to explain the histogenesis of Müllerian cysts in the mediastinum. Hattori (2) suggested that the cysts may be derived from misplaced mesothelium and mesenchyme with Müllerian characteristics similar to retroperitoneal Müllerian cysts. However, the fact that cysts in the retroperitoneum often have endocervical differentiation unlike mediastinal cysts implies that mediastinal Müllerian cysts are not simply a counterpart of retroperitoneal Müllerian cyst. Batt et al. (4) insisted that the cysts were directly originated from the primary Müllerian apparatus by adopting Ludwig's theory of the pathogenesis of the Mayer-Rokitansky-Küster-Hauser syndrome (5). Mediastinal Müllerian cysts are seen as homogeneous, thin-walled cysts without enhancement on CT. They are usually located at the posterior mediastinum, especially the paravertebral space (6). However, these findings are not specific for Müllerian cysts and are also encountered for other mediastinal cysts. Final diagnosis can be made by histological findings. Microscopically, ciliated epithelium with Müllerian differentiation confirms a diagnosis. Immunohistochemistry with positive staining for ER, PR, WT1 and PAX-8 may be helpful (7).

Mediastinal Müllerian cysts follow a benign course with no reported recurrence so that surgical excision is the treatment of choice. The mediastinal Müllerian cyst is a recently established type of mediastinal cyst, which should be considered in the differential diagnosis of mediastinal cysts located in the paravertebral space of the posterior mediastinum

in perimenopausal women or even in young women that are obese or have a previous gynecological history or hormonal abnormalities.

Conflict of Interest: No conflict of interest was declared by the authors.

REFERENCES

1. Takeda S, Miyoshi S, Minami M, Ohta M, Masaoka A, Matsuda H. Clinical spectrum of mediastinal cysts. *Chest* 2003;124:125-32.
2. Hattori H. Ciliated cyst of probable mullerian origin arising in the posterior mediastinum. *Virchows Arch* 2005;446:82-4.
3. Thomas-de-Montpreville V, Dulmet E. Cysts of the posterior mediastinum showing mullerian differentiation (Hattori's cysts). *Ann Diagn Pathol* 2007;11:417-20.
4. Batt RE, Mhaweche-Fauceglia P, Odunsi K, Yeh J. Pathogenesis of mediastinal paravertebral mullerian cysts of Hattori: developmental endosalpingiosis-mullerianosis. *Int J Gynecol Pathol* 2010;29:546-51.
5. Ludwig KS. The Mayer-Rokitansky-Kuster syndrome. An analysis of its morphology and embryology. Part II: Embryology. *Archives of gynecology and obstetrics* 1998;262:27-42.
6. Simmons M, Duckworth LV, Scherer K, Drew P, Rush D. Mullerian cysts of the posterior mediastinum: report of two cases and review of the literature. *J Thorac Dis* 2013;5:E8-E10.
7. Lee SJ, Hwang CS, Park DY, Huh GY, Lee CH. A ciliated cyst with mullerian differentiation arising in the posterior mediastinum. *Korean J Pathol* 2014;48:401-4.