

Original Article

Hirschsprung's Diseases Complicated by Sigmoid Volvulus: A Systematic Review

Ufuk Uylas¹, Orgun Gunes², Cüneyt Kayaalp³

¹Department of Gastroenterology Surgery, Gaziantep Dr. Ersin Arslan Training and Research Hospital, Gaziantep, Turkey

²Department of Gastroenterology Surgery, Inonu University Faculty of Medicine, Malatya, Turkey

³Department of Gastrointestinal Surgery, Inonu Universitesi Faculty of Medicine, Malatya, Turkey

Address for Correspondence: Ufuk Uylas, Department of Gastroenterology Surgery, Gaziantep Dr. Ersin Arslan Training and Research Hospital, Gaziantep, Turkey
ufukuylas@hotmail.com

Received: 20.04.2020

Accepted: 26.08.2020

DOI: [10.4274/balkanmedj.galenos.2020.2020.4.131](https://doi.org/10.4274/balkanmedj.galenos.2020.2020.4.131)

Cite this article as: Uylas U, Gunes O, Kayaalp C. Hirschsprung's Diseases Complicated by Sigmoid Volvulus: A Systematic Review. *Balkan Med*

Background: Hirschsprung's disease and sigmoid volvulus can sometimes be seen in the same patient.

Aims: A systematic review of the literature was conducted to find out conditions suggesting underlying Hirschsprung's disease in patients with sigmoid volvulus and to discuss the diagnostic and treatment modalities.

Study Design: Systematic Review

Methods: This systematic review has been reported in line with PRISMA (preferred reporting items for systematic reviews and meta-analyses) and AMSTAR (assessing the methodological quality of systematic reviews) guidelines. PubMed and Scopus databases were scanned using the keywords "Hirschsprung* volvulus*" and "congenital aganglionic megacolon volvulus*". The reference list of selected studies was reviewed for cross-checking. Two reviewers independently screened the available literature. Only Hirschsprung's disease cases involving sigmoid volvulus were accepted, and volvulus in other sites was excluded. No restriction was used in the publication language and type of writing. The primary outcome was morbidity and mortality.

Results: A total of 31 cases were analyzed in 22 articles. Ninety-seven percent of the patients were under 40 years of age. Ninety percent of the patients were male. In patients suspected to have Hirschsprung's disease accompanying sigmoid volvulus and treated appropriately, a postoperative emergency relaparotomy was not performed, whereas this ratio was 37.5% in patients whose Hirschsprung's disease was misdiagnosed ($p = 0.02$). Likewise, in patients with sigmoid volvulus with missed Hirschsprung's disease, the post-treatment mortality rate was 25%, while in patients whom Hirschsprung's disease was suspected, mortality was not observed ($p = 0.08$).

Conclusion: If a sigmoid volvulus patient is under 40 years of age and complaints of constipation occurring since childhood, Hirschsprung's disease should be excluded with rectal biopsy.

Keywords: colon, ileus, acute abdomen, anastomosis, bowel, constipation

INTRODUCTION

Hirschsprung's disease and sigmoid volvulus are bowel diseases that are accompanied by chronic constipation. Both are more common in males (1). Hirschsprung's disease is more prevalent in newborns and in childhood, but a less aggressive form of a short-segment Hirschsprung's disease can be diagnosed in adolescence or in adulthood (2). Sigmoid volvulus is seen patients at older ages, and it is rarely encountered in children (3). Sometimes both pathologies may occur in the same individual. Hirschsprung's disease is a congenital disease and sigmoid volvulus is a complication of Hirschsprung's disease. It is important to diagnose an underlying Hirschsprung's disease in sigmoid volvulus cases.

The basis of treatment of Hirschsprung's disease is resection of the aganglionic segment and construction of coloanal anastomosis between the normal colon and anal canal. In order to achieve this goal, various treatment modalities have been developed (4). The management approach of sigmoid volvulus includes the derotation of the sigmoid colon by endoscopic, enema, or surgical approaches in cases with viable bowel. Following this step, elective surgery can be planned for cases with acceptable anesthesia and operative risk. In patients with a failed derotation attempt, findings of the acute abdomen, or gangrenous bowel, emergency surgery is indicated (5,6). If the associated Hirschsprung's disease is overlooked the outcomes of the treatment of sigmoid volvulus alone are not clear. The aim of this study is to provide clarity with a comprehensive systematic review of the literature.

MATERIALS AND METHODS

This systematic review was prepared based on the preferred reporting items for systematic reviews and meta-analyses (PRISMA).

Search Strategy

PubMed and Scopus databases were scanned using the keywords "Hirschsprung* volvulus*" and "congenital aganglionic megacolon volvulus*". The final screening took place on May 13, 2020. The reference list of selected studies was reviewed for cross-checking.

Selection Criteria and Intervention(s)

No restriction was used in the publication language and type of articles. Only Hirschsprung's disease cases involving sigmoid volvulus were included, and other volvulus cases (cecum, transverse, or splenic) were excluded. An e-mail was sent to the authors to obtain the missing data (such as surgical outcome, gender, and age) in their articles.

Data Extraction and Study Quality

The methodological quality of systematic reviews (AMSTAR) was used to assess the quality of this review (7). The *Cochrane Handbook for Systematic Reviews of Interventions* (the *Handbook*) was used for the risk of bias of included studies in this review (8). This systematic review was registered in an international database (PROSPERO, CRD42020166692). The majority of the studies reporting concomitant Hirschsprung's disease and sigmoid volvulus mainly include isolated case reports or small amounts of case series because this entity is a rare event. Year of publication, country of publication, age, gender, presence of gangrene, surgical or non-surgical treatments, and outcomes were reviewed. The data were evaluated separately by two researchers (UU, CK). A total of 31 cases were included in the analysis in 22 studies that met the defined inclusion criteria (Figure 1). Patients were grouped according to age groups: 0-2 newborn and infant, 2-17 pediatric, and $18 \leq$ adults.

Statistical Analysis

Statistical analyses were performed using SPSS v22.0 (IBM, Armonk, NY, USA).

Quantitative variables were expressed as mean \pm SD, median, min-max, and interval.

Qualitative variables were reported as numbers and percentages (%). The Shapiro-Wilk test was used to assess the normality distribution of quantitative variables. While the mean and standard deviations were used for homogenous distributions, median and range were given for heterogeneous distributions. Fisher's Chi-Square test was used to compare qualitative variables. The Mann-Whitney U test was used for heterogeneous distributions and Student's t-test was used for homogeneous distributions. A p-value below 0.05 was considered statistically significant.

RESULTS

Publications included 16 cases from Asia, 8 cases from Europe, 4 cases from Africa, and 3 cases from North America (9-26). The age distribution of the patients was not homogeneous (Shapiro-Wilk test, $p < 0.05$). The age range was 4 hours and 82 years (median 10 years). Median age for newborn/infant, child, and adult was 1 day (1-42 days), 7 years (3-12), and 24 years (18-82) respectively. Ninety-seven percent of the patients were under 40 years of age and 90% were male (Table 1).

Non-operative detorsion was attempted in 14/25 (56%) of the patients (seven with the enema, two with the rectal tube, and five with endoscopy), and the success of nonoperative detorsion was 9/14 (64.3%). A total of 11 patients (five failed non-operative derotation and in six patients a non-operative intervention was not attempted) underwent surgical detorsion.

In 19 (70.4%) patients, Hirschsprung's disease was diagnosed or suspected during treatment of sigmoid volvulus (Table 2). In these 19 patients, the treatment of Hirschsprung's disease was successfully performed in a single procedure or step-wise surgical intervention. In the remaining eight patients in whom the Hirschsprung's disease diagnosis was overlooked, three patients required early relaparotomy after the first operation, and two of these patients resulted in mortality. There was a difference in the necessity for relaparotomy (37.5% vs. 0%, $p = 0.02$) between patients who were scheduled for sigmoid volvulus therapy with the suspicion of Hirschsprung's disease and patients who were treated without suspicion of Hirschsprung's disease. While mortality was not observed in 19 patients who were suspected

to have Hirschsprung's disease, mortality was observed in two of the eight patients who had only sigmoid volvulus treatment without considering Hirschsprung's disease (25% vs 0%, $p=0.08$). In four patients, there was no data on this issue.

Intraoperative bowel gangrene was observed in only 3 (9.7%) patients. In one case, gangrene was observed in the entire colon. The surgical procedures performed for Hirschsprung's disease showed heterogeneity. The Soave procedure was performed in six patients, Swenson procedure in 11, sphincterotomy in one patient, and restorative proctocolectomy in one patient. Mortality was observed in a total of two (8%) patients, where one was of pediatric age, and the other one was an adult. Both patients did not have gangrene. However, neither of the patients had undergone definitive surgery for Hirschsprung's disease because of unawareness of a Hirschsprung's disease diagnosis. One of these patients underwent only surgical detorsion, and the cause of death was unknown. Resection and anastomosis with transverse colostomy were performed in the other patient. After the closure of the colostomy, relaparotomy was necessary due to massive abdominal distension. There was anastomotic leakage, and primary repair and a transverse colostomy were performed. Hirschsprung's disease was detected in a rectal biopsy, but the patient died from the septic shock of fecal peritonitis. No mortality was seen in patients undergoing definitive surgery for Hirschsprung's disease.

DISCUSSION

The incidence of Hirschsprung's disease is approximately one in 5000 live births (27, 28). The incidence may change among ethnic groups. The incidence of Hirschsprung's disease is 1.5 in 10000 live births in Northern Europe, 2.1 in African-American, and 2.8 in Asian populations (29). In this analysis, most patients with sigmoid volvulus combined with Hirschsprung's disease, 50% of the cases (15/30), were reported from Asia, and the lowest rate was from the United States, with 10% of the cases (3/30). The incidence of Hirschsprung's disease varies between genders as well. The male-to-female ratio is approximately 4:1 (1, 30). This study found a similarly high incidence of the disease in males (90%).

Approximately 95% of patients with Hirschsprung's disease are diagnosed before the age of five (31). Mild cases can be diagnosed after age 10 and are called as adult Hirschsprung's disease (32-34). The actual incidence of patients with adult Hirschsprung's disease is unknown because Hirschsprung's disease is often overlooked in adult patients. There are cases of Hirschsprung's disease even at the ages of 74 and 82 (26, 35). About half of the adult patients with Hirschsprung's disease are under 30 years of age (2). In our study, 93% of the patients were under the age of 30, and 97% were under 40 years of age.

Hirschsprung's disease is seen in 0.6-3% of sigmoid volvulus cases (15, 23). Hirschsprung's disease frequency rises to 17% in the sigmoid volvulus cases under the age of 18 (3). In a study by Ghaemi et al., Hirschsprung's disease was detected in approximately 1/3 of sigmoid volvulus patients whose ages ranged between 14 and 30 years (20). The aganglionic segment in Hirschsprung's disease starts from the distal rectum, and the extent of the proximal diseased part varies. In 80% of individuals, aganglionosis is restricted to the rectosigmoid colon (short-segment disease); in 15%-20% of the cases aganglionosis extends proximally to the sigmoid colon (long-segment disease); in about 5%, aganglionosis affects the entire large intestine (total colonic aganglionosis). Rarely, the aganglionosis extends into the small bowel or even more proximally to encompass the entire bowel (total intestinal aganglionosis). Most of late-diagnosed Hirschsprung's disease affects the short-segment of the bowel. In these patients, prolonged constipation increases the likelihood of developing sigmoid volvulus (27).

Rectal biopsy for the diagnosis of Hirschsprung's disease is a worldwide accepted entity. The rectal biopsy is recommended from 1-3 cm above the dentate line (36). Although frequently applied as a result of consensus, routine use of anorectal manometry or barium enema in Hirschsprung's disease is not necessary (37). Anorectal manometry was reported to be more

useful for neurogenic achalasia of the internal anal sphincter rather than for Hirschsprung's disease (37). It is difficult to detect the presence of Hirschsprung's disease using radiological evaluation techniques in a patient with sigmoid volvulus. In the same consensus, it was decided that barium enema is not necessary to confirm the diagnosis of Hirschsprung's disease, but it aids in the determination of the extent of involved aganglionic bowel segment to guide the operative strategy (37).

On rectal examination, a massive discharge of flatus and stool is expected in Hirschsprung's disease, but this physical examination may not be observed when sigmoid volvulus is present. The majority of patients (97%) in the present study were under 40 years of age, which suggests that Hirschsprung's disease should be suspected in patients under 40 years of age with cases of sigmoid volvulus (Figure 2). Previously published guidelines from Salas et al. on the management of sigmoid volvulus with suspected Hirschsprung's disease do not mention age or colon viability (3). Therefore, it is our recommendation that in patients who have signs of suspected Hirschsprung's disease (complaints of constipation since childhood and patients under 40 years of age) at the time of sigmoid volvulus diagnosis, rectal biopsy should be performed. This is more recommendable if the patient is male.

During the evaluation of patients with sigmoid volvulus together with megacolon, physicians should not only consider Hirschsprung's disease but also consider degenerative myopathies such as Bantu's pseudo-Hirschsprung's disease or isolated hypoganglionosis. Degenerative myopathies are inherited diseases like Hirschsprung's disease, and there are also adult forms that can be seen patients in the 30-34 age range. In these patients, diagnoses can be made by rectal biopsy as well (38-41).

In sigmoid volvulus patients with suspected Hirschsprung's disease, a rectal biopsy is needed before sigmoid resection. Definitive surgery should be planned according to the result of the rectal biopsy. In the first stage, detorsion should be performed by endoscopic, enema, or surgical means. When Hirschsprung's disease is excluded by an intraoperative frozen biopsy, the surgeon can continue definitive surgery. In this study, only 4 of the 21 (19.0%) patients were diagnosed through an intraoperative frozen biopsy. A colostomy was performed, and definitive surgery was performed in a second the session in those three cases. In the remaining one patient, due to gangrene in the entire colon, a total colectomy with J pouch ileoanal anastomosis was performed in the initial operation.

In this study, the incidence of sigmoid gangrene was lower in sigmoid volvulus patients with Hirschsprung's disease (9.7%). We think that the presence of gangrene is not an obstacle to rectal biopsy. In these patients, resection is essential, and this colon resection can make definitive surgery more difficult. Three cases of gangrene were reported in the literature, and only one of them had a rectal biopsy. Hartmann's procedure was performed in a 12-year-old male patient with gangrenous sigmoid volvulus (17). A 38-year-old male patient with gangrenous sigmoid volvulus was diagnosed with a gangrenous sigmoid colon extending to the transverse and ascending colon. This patient underwent proctocolectomy ileal pouch-anal anastomosis (19). An 82-year-old man was initially followed-up conservatively. Laparotomy was performed due to evolving acute abdominal findings. Hartmann's procedure was performed since a gangrenous sigmoid colon was observed during the exploration (26).

When Hirschsprung's disease is suspected in patients with sigmoid volvulus, colostomy as the first-step surgical procedure is more appropriate if a sigmoid resection is necessary. If the patient has overlooked Hirschsprung's disease, the risk of anastomotic leakage is high due to the distal aganglionic segment. If there is suspicion of Hirschsprung's disease in a patient and anastomosis was performed, a rectal tube placement may be recommended.

Limitations of this study are that the majority of studies included in this study were case reports, and the operations performed for Hirschsprung's disease were heterogeneous.

Sigmoid volvulus association with Hirschsprung's disease is a rare event. For this reason, this

review is not appropriate for meta-analysis, or randomized controlled trials are needed to make it appropriate. Although there is a low risk of bias for the included studies, this review suggests us a low-quality recommendation, but we think that the recommendations are easily applicable and will assist in avoiding mortality and morbidity.

CONCLUSION

In a patient with constipation since childhood, especially in those with sigmoid volvulus under 40 years of age, it should be kept in mind that an underlying Hirschsprung's disease may be present; and this diagnosis should be excluded before resection and anastomosis of colon.

Acknowledgement

The authors would like to thank Ilse Van Horebeek for her contributions via e-mail.

REFERENCES

1. Puri P. Hirschsprung's disease. In: Puri P, editor. *Newborn Surgery*. London: Arnold; 2003. p. 513-33.
2. Miyamoto M, Egami K, Maeda S, Ohkawa K, Tanaka N, Uchida E et al.. Hirschsprung's disease in adults: report of a case and review of the literature. *J Nippon Med Sch* 2005;72:113-20.
3. Salas S, Angel CA, Salas N, Murillo C, Swischuk L. Sigmoid volvulus in children and adolescents. *J Am Coll Surg* 2000;190:717-23.
4. Huang WK, Li XL, Zhang J, Zhang SC. Prevalence, Risk Factors, and Prognosis of Postoperative Complications after Surgery for Hirschsprung Disease. *J Gastrointest Surg* 2018;22:335-43.
5. Atamanalp SS. Treatment of sigmoid volvulus: a single-center experience of 952 patients over 46.5 years. *Tech Coloproctol* 2013;17:561-9.
6. Lou Z, Yu ED, Zhang W, Meng RG, Hao LQ, Fu CG. Appropriate treatment of acute sigmoid volvulus in the emergency setting. *World J Gastroenterol* 2013;19:4979-83.
7. Shea BJ, Reeves BC, Wells G, Thuku M, Hamel C, Moran J et al.. AMSTAR 2: a critical appraisal tool for systematic reviews that include randomised or non-randomised studies of healthcare interventions, or both. *BMJ*. 2017 Sep 21;358:j4008.
8. Higgins JPT, Green S (editors). *Cochrane Handbook for Systematic Reviews of Interventions* Version 5.1.0 [updated March 2011]. The Cochrane Collaboration, 2011. Available from www.handbook.cochrane.org.
9. Dean GO, Murry JW. Volvulus of the sigmoid colon. *Ann Surg* 1952;135:830-40.
10. Zeng M, Amodio J, Schwarz S, Garrow E, Xu J, Rabinowitz SS. Hirschsprung disease presenting as sigmoid volvulus: a case report and review of the literature. *J Pediatr Surg* 2013;48:243-6.
11. Buts JP, Claus D, Beguin JC, Otte JB. Acute and chronic sigmoid volvulus in childhood: report of three cases. *Z Kinderchir* 1980;29:29-36.
12. McCalla TH, Arensman RM, Falterman KW. Sigmoid volvulus in children. *Am Surg* 1985;51:514-9.
13. Erdener A, Ulman I, Ozcan C, Genc K. A case of sigmoid volvulus secondary to Hirschsprung's disease. *Pediatr Surg Int* 1995;10:409-10.

14. Venugopal KS, Wilcox DT, Bruce J. Hirschsprung's disease presenting as sigmoid volvulus in a newborn. *Eur J Pediatr Surg* 1997;7:172-3.
15. Sarioğlu A, Tanyel FC, Büyükpamukçu N, Hiçsönmez A. Colonic volvulus: a rare presentation of Hirschsprung's disease. *J Pediatr Surg* 1997;32:117-8.
16. Rachid K, Jaafar A, Mdaghri J, El Mansari O, Ouanani M, Echarrab M et al. Hirschsprung's disease in an adult presenting as a sigmoid volvulus. *Lyon Chir* 1997;93:193-4.
17. Puneet, Khanna R, Gangopadhyay AN, Shahoo SP, Khanna AK. Sigmoid volvulus in childhood: report of six cases. *Pediatr Surg Int* 2000;16:132-3.
18. Bach O, Rudloff U, Post S. Modification of mesosigmoidoplasty for nongangrenous sigmoid volvulus. *World J Surg* 2003;27:1329-32.
19. Tan FL, Tan YM, Heah SM, Seow-Choen F. Adult Hirschsprung's disease presenting as sigmoid volvulus: a case report and review of literature. *Tech Coloproctol* 2006;10:245-8.
20. Ghaemi M, Bahar MM, Motie MR, Hiradfar M, Soltani E, Saremi E. Late presentation of Hirschsprung's disease as sigmoid colon volvulus: report of four cases and review of the literature. *Colorectal Dis* 2010;12:704-5.
21. Alagumuthu M, Jagdish S, Kadambari D. Hirschsprung's disease in adults presenting as sigmoid volvulus: a report of three cases. *Trop Gastroenterol* 2011;32:343-5.
22. Ibrahim A, Ibrahim and Mohamed A, Osman. Transcolostomy-site endorectal pullthrough for Hirschsprung's disease. *Ann Pediatr Surg* 2013;9:11-15.
23. Khalayleh H, Koplewitz BZ, Kapuller V, Armon Y, Abu-Leil S, Arbell D. Neonatal sigmoid volvulus. *J Pediatr Surg* 2016;51:1782-5.
24. Ranjan A, Jain V, Sharma S, Gupta DK. Sigmoid volvulus: an uncommon complication of Hirschsprung's disease. *BMJ Case Rep*. 2016.
25. Von Horebeek I, Hoffman I, Witters P. A coffee bean in an infant: call the endoscopist. *J Paediatr Child Health* 2017;53:515-19.
26. Wu S, Sun X, Yu Y, Shen Y. Hirschsprung's Disease-Related Giant Sigmoid Volvulus Complicated by Refractory Hypertension in an Elderly Man. *Am J Case Rep* 2018;19:467-71.
27. Badner JA, Sieber WK, Garver KL, Chakravarti A. A genetic study of Hirschsprung disease. *Am J Hum Genet* 1990;46:568-80.
28. Parisi MA, Kapur RP. Genetics of Hirschsprung disease. *Curr Opin Pediatr* 2000;12:610-7.
29. Torfs C. An epidemiological study of Hirschsprung disease in a multiracial California population. *Evian, France: The Third International Meeting: Hirschsprung Disease and Related Neurocristopathies*; 1998.
30. Langer JC. Hirschsprung disease. In: Holcomb GW 3rd, Murphy JP, Ostlie DJ, editors. *Ashcraft's pediatric surgery*. 6th edition. Philadelphia: Saunders Elsevier; 2010. p. 474-91.
31. Ikeda K, Goto S. Diagnosis and treatment of Hirschsprung's disease in Japan. An analysis of 1628 patients. *Ann Surg* 1984;199:400-5.
32. Fairgrieve J: Hirschsprung's disease in the adult. *Br J Surg* 1963;50:506-14.
33. McCready RA, Beart RW Jr. Adult Hirschsprung's disease: Results of the surgical treatment at Mayo Clinic. *Dis Colon Rectum* 1980;23:401-7.
34. Barnes PR, Lennard-Jones JE, Howley PR, Todd IP: Hirschsprung's disease and idiopathic megacolon in adults and adolescents. *Gut* 1986;27:534-41.
35. Rich AJ, Lennard TW, Wilsdon JB. Hirschsprung's disease as a cause of chronic constipation in the elderly. *Br Med J (Clin Res Ed)* 1983;287:1777-8.

36. Burki T, Sinha CK, Yamataka A. Hirschsprung's Disease. In: Sinha C, Davenport M (eds) Handbook of Pediatric Surgery. Springer, London. 2010; pp117-24.
37. Martucciello G, Pini Prato A, Puri P, Holschneider AM, Meier-Ruge W, Jasonni V et al. Controversies concerning diagnostic guidelines for anomalies of the enteric nervous system: a report from the fourth International Symposium on Hirschsprung's disease and related neurocristopathies. *J Pediatr Surg* 2005;40:1527-31.
38. Qadir I, Salick MM, Barakzai A, Zafar H. Isolated adult hypoganglionosis presenting as sigmoid volvulus: a case report. *J Med Case Rep* 2011;5:445.
39. Gabbani T, Marsico M, Marocchi M, Biagini MR. Isolated hypoganglionosis in young man with autism. *Dig Liver Dis* 2017;49:104.
40. Rode H, Moore SW, Kaschula ROC, Brown RA, Cywes S. Degenerative leiomyopathy in children. A clinico-pathological study. *Pediatr Surg Int* 1992;7:23-29.
41. Katz A. Pseudo-Hirschsprung's disease in Bantu children. *Arch Dis Child* 1996;41:152.

TABLE 1. Reports of 31 Hirschsprung's diseases complicated by sigmoid volvulus in chronological order

Author	Country	Year	Age	Gender	Perioperative Findings
Dean ⁹	USA	1952	4 years	Male	SV
Shepherd ^{10a}	Uganda	1969	12 years	Male	SV
Ciardimi et al. ^{10a}	Italy	1977	3 years	Male	SV
Ciardimi et al. ^{10a}	Italy	1977	5 years	Male	SV
Buts et al. ¹¹	Belgium	1980	10 years	Female	SV
Valla et al. ^{10a}	France	1982	5 days	Male	SV
Valla et al. ^{10a}	France	1982	5 years	Male	SV
McCalla et al. ¹²	USA	1985	2 days	Male	SV
Henales et al. ^{10a}	Spain	1993	5 years	Male	SV
Erdener et al. ¹³	Turkey	1995	3 years	Male	SV
Venugopal et al. ¹⁴	UK	1997	4 hours	Male	SV
Sarioglu et al. ¹⁵	Turkey	1997	11 years	Male	SV
Rachid ¹⁶	Morocco	1997	Adult ^b	Male ^b	SV
Puneet et al. ¹⁷	India	2000	12 years	Male	Gangrenous SV
Bach et al. ¹⁸	Malawi	2003	Adult ^c	n/a	SV
Tan et al. ¹⁹	Singapore	2006	38 years	Male	Gangrenous SV ^d
Ghaemi et al. ²⁰	Iran	2010	18 years	Female	SV
Ghaemi et al. ²⁰	Iran	2010	21 years	Male	SV
Ghaemi et al. ²⁰	Iran	2010	19 years	Male	SV
Ghaemi et al. ²⁰	Iran	2010	24 years	Male	SV
Alagumuthu et al. ²¹	India	2011	33 years	Male	SV
Alagumuthu et al. ²¹	India	2011	18 years	Female	SV
Alagumuthu et al. ²¹	India	2011	24 years	Male	SV
Zeng et al. ¹⁰	USA	2012	12 years	Male	SV
Ibrahim et al. ²²	Egypt	2013	7 years	Male	SV
Khalayleh et al. ²³	Israel	2016	1.25 days	Male	SV
Khalayleh et al. ²³	Israel	2016	1.25 days	Male	SV
Khalayleh et al. ²³	Israel	2016	1 days	Male	SV
Ranjan et al. ²⁴	India	2016	11 years	Male	SV
Van Horebeek et al. ²⁵	Belgium	2017	42 days	Male ^e	SV
Wu ²⁶	China	2018	82 years	Male	Gangrenous SV

SV: Sigmoid volvulus, **a:** Reference found in cited review article, **b:** From Scopus, **c:**

Adulthood of the patient was understood from picture in the article, **d:** Gangrenous

sigmoid colon, duskiness involving entire colon, **e:** The author of the study reported by e-mail.

TABLE 2. Reports of surgical approach for 31 Hirschsprung's diseases complicated by sigmoid volvulus in chronological order

Author	Derotation	Biopsy	Surgery	Doubt on HD	Outcome
Dean ⁹	Enema/Yes	n/a	Surgical details are not available	n/a	Recovered
Shepherd ^{10a}	Surgery/Yes	n/a	Only derotation	No	Died
Ciardimi et al. ^{10a}	n/a	n/a	Surgical details are not available	n/a	n/a
Ciardimi et al. ^{10a}	n/a	n/a	Surgical details are not available	n/a	n/a
Buts et al. ¹¹	Enema/Failed	Yes	First sigmoidopexy later Swenson	No	Recovered
Valla et al. ^{10a}	Surgery/Yes	n/a	Only sigmoidectomy	No	Recovered
Valla et al. ^{10a}	Surgery/Yes	n/a	Only sigmoidectomy	No	Recovered
McCalla et al. ¹²	Surgery/Yes	Yes	First only derotation, relaparotomy ^b , later Soave	No	Recovered
Henales et al. ^{10a}	Surgery/Yes	n/a	Enterostomy and sphincterotomy	Yes	Recovered
Erdener et al. ¹³	Surgery/Yes	Yes	First colostomy later Soave	Yes	Recovered
Venugopal et al. ¹⁴	Enema/Yes	Yes	Soave	Yes	Recovered
Sarioglu et al. ¹⁵	Surgical/Yes	Yes	First colostomy later Swenson	Yes	Recovered
Rachid ¹⁶	n/a	n/a	Surgical details are not available	n/a	n/a
Puneet et al. ¹⁷	n/a	Yes	Hartmann's procedure	No	Recovered
Bach et al. ¹⁸	n/a	Yes	First mesosigmoidoplasty, second relaparotomy ^c	No	Recovered
Tan et al. ¹⁹	Surgical/Yes	Yes	Restorative proctocolectomy	Yes	Recovered
Ghaemi et al. ²⁰	Endoscopy/Yes	Yes	Swenson	Yes	n/a
Ghaemi et al. ²⁰	Endoscopy/Failed	Yes	First derotation later Swenson	Yes	n/a
Ghaemi et al. ²⁰	Endoscopy/Failed	Yes	First derotation later Swenson	Yes	n/a
Ghaemi et al. ²⁰	Endoscopy/Failed	Yes	First derotation later Swenson	Yes	n/a
Alagumuthu et al. ²¹	Surgical/Yes	Yes ^d	Anastomosis and colostomy ^e and relaparotomy	No	Died
Alagumuthu et al. ²¹	Surgical/Yes	Yes	First colostomy ^f later Swenson	Yes	Recovered

Alagumuthu et al. ²¹	Rectal tube/Yes	Yes	Soave ^g	Yes	Recovered
Zeng et al. ¹⁰	Rectal tube/Yes	Yes	Surgical details are not available	Yes	Recovered
Ibrahim et al. ²²	Enema/Failed	Yes	First colostomy later Soave ^g	Yes	Recovered
Khalayleh et al. ²³	Enema/Yes ^h	Yes	Swenson	Yes	Recovered
Khalayleh et al. ²³	Enema/Yes	Yes	Swenson	Yes	Recovered
Khalayleh et al. ²³	Enema/Yes	Yes	Swenson	Yes	Recovered
Ranjan et al. ²⁴	n/a	n/a	Soave ⁱ	Yes	Recovered
Van Horebeek et al. ²⁵	Endoscopy/Yes	Yes	Swenson ^j	Yes	Recovered
Wu ²⁶	Surgical/Yes	Yes	First Hartmann's procedure later none	Yes	Recovered
<p>a: Reference found in cited review article, b: After 12 days emergency laparotomy and colostomy, c: Relaparotomy but surgical technique not definition, d: Second transvers colostomy, e: Transvers colostomy done. After one week of colostomy closure; primer repair, transvers colostomy plus rectal biopsy due to perforation, f: Double barrel colostomy, g: Modified Soave, h: Derotation with enema due to two times recurrent, i: Primary Scott Boley's, j: The author was reached via mail.</p>					

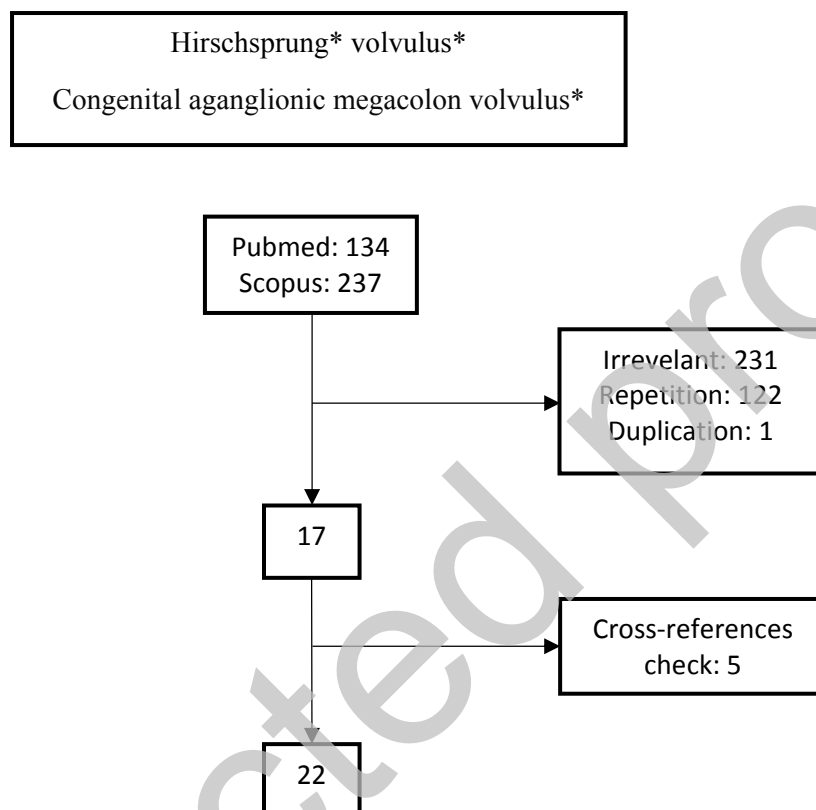
FIG. 1. Flowchart of systematic review

FIG. 2. Management of Hirschsprung's disease complicated by sigmoid volvulus