

A Rare Cause of Acute Abdomen: Torsion of Subserous Uterine Fibroid in a Postmenopausal Woman

So Yamashita¹, Hirohisa Fujikawa^{2,3}, Toru Yoshizawa¹

¹Department of Obstetrics and Gynecology, Suwa Central Hospital, Nagano, Japan

²Department of Medical Education Studies, International Research Center for Medical Education, Graduate School of Medicine The University of Tokyo, Tokyo, Japan

³Department of Internal Medicine, Suwa Central Hospital, Chino, Nagano, Japan

To the Editor,

Uterine fibroids, the most common tumors in reproductive-aged women, are found in 20%-30% of women aged ≥ 30 years.¹ However, they rarely become symptomatic after menopause, and emergency operation is usually unnecessary.² Herein, we report a rare case of uterine fibroid torsion in a 60-year-old postmenopausal woman. The patient presented to an emergency department with a history of intermittent diffuse lower abdominal pain that started 3 days earlier. Previously, she had no episodes of vomiting, diarrhea, or vaginal bleeding. Upon examination, she was afebrile and tachycardiac (103 beats/min) and had diffuse lower abdominal tenderness with peritoneal signs. Laboratory testing revealed a white blood cell count of 9.6 (normal 3.5-9.1) $\times 10^9/l$ and a C-reactive protein level of 117 (normal 0-3) mg/l. Peritonitis was suspected, and pelvic and abdominal contrast-enhanced computed tomography (CT) showed a mass cranial to the uterus with a dark fan sign but no sign of appendicitis or other bowel etiologies (Figure 1a-c). Emergency transvaginal ultrasonography revealed a pelvic mass suggestive of a uterine fibroid (Figure 1d). Pelvic magnetic resonance imaging also suggested a uterine fibroid (Figure 1e) and confirmed bilateral intact ovaries, excluding the possibility of ovarian torsion. Signs of peritonitis and imaging findings indicated uterine fibroid torsion. Intraoperative examination confirmed the diagnosis of necrotic pedunculated subserous uterine fibroid twisted by 360° with slight bleeding (Figure 2a). Given the prominent intrapelvic inflammation and strong edematous change to the uterus, hysterectomy was avoided to minimize the risk of unnecessary complications due to heavy bleeding. Necrotic fibroid myomectomy was successfully performed, and no postoperative complications were observed. Histology confirmed a benign necrotic leiomyoma with no sign of malignancy (Figure 2b).

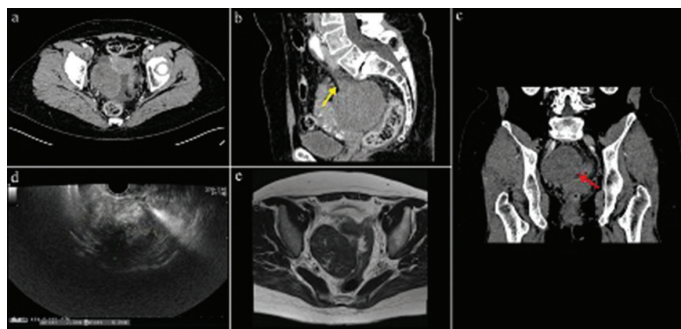


FIG. 1. Radiological findings of the patient. (a-c) Contrast-enhanced computed tomography scan of the abdomen and pelvis showing a dark fan sign (fan-shaped poor contrast enhancement within the uterus next to the fibroid) (red arrow), indicating the necrotic pedicle of the uterine fibroid (yellow arrow) (a, axial view; b, sagittal view; c, coronal view). (d) Transvaginal ultrasound image showing a pelvic mass suggestive of 70 x 60-mm uterine fibroids. (e) Magnetic resonance imaging suggesting a uterine fibroid with a twisted pedicle.

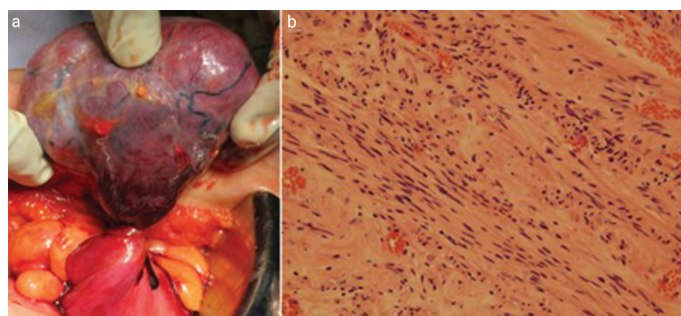


FIG. 2. Per-operative and histopathological findings of the patient. (a) Twisted uterine fibroid with necrosis and bleeding. (b) Histopathological examination indicating a leiomyoma (hematoxylin and eosin staining, original magnification x200).



Corresponding author: So Yamashita, Department of Obstetrics and Gynecology, Suwa Central Hospital, Nagano, Japan
e-mail: so.yama81@gmail.com

Received: April 26, 2022 Accepted: June 06, 2022 Available Online Date: September 09, 2022 • DOI: 10.4274/balkanmedj.galenos.2022.2022-4-98

Available at www.balkanmedicaljournal.org

ORCID iDs of the authors: S.Y. 0000-0002-5585-6004; H.F. 0000-0002-8195-1267.

Cite this article as: Yamashita S, Fujikawa H, Yoshizawa T. A Rare Cause of Acute Abdomen: Torsion of Subserous Uterine Fibroid in a Postmenopausal Woman. *Balkan Med J.*; 2022; 39(5):378-9.

Copyright@Author(s) - Available online at <http://balkanmedicaljournal.org/>

Fibroid torsion as a cause of uterine fibroid-derived acute abdomen is extremely rare, and one study reported an incidence of less than 0.25% among surgically diagnosed uterine fibroids.³ Given the lack of specific symptoms and imaging findings, there is a challenge in establishing the diagnosis before surgical exploration, and ovary torsion and fibroid degeneration are among the major differential diagnoses.¹ Few case reports have suggested that fibroid torsion could be distinguished from ovarian torsion with its subacute and intermittent presentation, whereas the high C-reactive protein level and “dark fan sign” proposed by Ohgiya et al. observed in contrast-enhanced CT may aid in differentiating it from fibroid degeneration, which does not require surgical intervention.^{3,4} In our case, the intraoperative evaluation also revealed signs of bleeding at the twisted sight. If left untreated, the bleeding could have led to fibroid autoamputation, resulting in morbidity.^{1,5} Misdiagnosing torsions with the more common fibroid degeneration can lead to fatal complications. Thus, for timely surgical intervention, the possibility of uterine fibroid torsion should always be considered even after menopause.

Informed Consent: Written informed consent was obtained from the patient.

Author Contributions: Concept- S.Y., H.F., T.Y.; Design- S.Y., H.F., T.Y.; Data Collection or Processing- S.Y., H.F., T.Y.; Analysis or Interpretation- S.Y., H.F., T.Y.; Literature Search- S.Y., H.F., T.Y.; Writing- S.Y., H.F., T.Y.

Conflict of Interest: No conflict of interest was declared by the authors.

REFERENCES

1. Gupta S, Manyonda IT. Acute complications of fibroids. *Best Pract Res Clin Obstet Gynaecol.* 2009;23:609-617. [\[CrossRef\]](#)
2. Sankaran S, Manyonda IT. Medical management of fibroids. *Best Pract Res Clin Obstet Gynaecol.* 2008;22:655-676. [\[CrossRef\]](#)
3. Lai YL, Chen YL, Chen CA, Cheng WF. Torsion of pedunculated subserous uterine leiomyoma: A rare complication of a common disease. *Taiwan J Obstet Gynecol.* 2018;57:300-303. [\[CrossRef\]](#)
4. Ohgiya Y, Seino N, Miyamoto S, et al. CT features for diagnosing acute torsion of uterine subserosal leiomyoma. *Jpn J Radiol.* 2018;36:209-214. [\[CrossRef\]](#)
5. Suganuma I, Mori T, Takahara T, et al. Autoamputation of a pedunculated, subserosal uterine myoma presenting as a giant peritoneal loose body. *Arch Gynecol Obstet.* 2015;291:951-953. [\[CrossRef\]](#)