



Supernumerary Testis (Polyorchidism)

Şenay Bengin Ertem¹, Mustafa Reşorlu¹, Koray Öz²

¹Department of Radiology, Çanakkale Onsekiz Mart University Faculty of Medicine, Çanakkale, Türkiye

²Clinic of Radiology, Defne State Hospital, Hatay Türkiye

A 32-year-old man presented to our hospital's urology department with intermittent pain and a palpable mass in the left testis. Physical examination revealed a painless, palpable mass in the left scrotum. However, there were no indications of such as local warmth or erythema. Blood tests, including tumor markers, were normal. The urine test was normal, and the urine culture was negative. The patient was referred to our clinic for a testicular ultrasound (US).

Testicular US revealed an oval-shaped supernumerary testis contiguous with the normal testis in the left scrotum, showing similar echogenicity and vascularity to the normal testis (Figure 1a). The right testicle size measured 46 × 25 × 36 mm, the left testicle measured approximately 28 × 22 × 28 mm, and the third testicle located adjacent to the lateral side of the left testicle was measured as 28 × 20 × 23 mm. His pelvic magnetic resonance imaging (MRI) was performed following the detection of polyorchidism, which revealed a supernumerary testis contiguous with the normal testis in the left scrotum. The signal intensities of all three testes were normal (intermediate signal on T1-weighted images and high signal on T2-weighted images) (Figure 1b), and each possessed its own epididymis and vas deferens (Figure 1c) (Bergholz et al.¹ type A1 polyorchidism).

The patient exhibited no findings of torsion or malignancy, and orchiectomy of the supernumerary testicle was recommended owing to an increased risk of malignancy. However, the patient refused to undergo surgery and was discharged with the recommendation of undertaking annual US.

Polyorchidism is a rare genital system anomaly characterized by the presence of more than two testes. Approximately 200-250 cases (90

of which were histologically proven) have been reported to date.¹⁻³ The etiology of polyorchidism is not yet fully understood although embryonic division anomalies have been implicated.^{3,5} Triorchidism is the most common form of polyorchidism, with the accessory testis being most frequently localized in the scrotal pouch.³ Localization in the abdomen and inguinal region is rare.³ Supernumerary testes can be unilateral or bilateral. The supernumerary testis was located on the left side in approximately two-thirds of all cases reported to date.⁴ Polyorchidism can mimic testicular neoplasias, spermatoceles, varicoceles, and hydroceles, because of which physical examination may be insufficient for differential diagnosis.³ Several cases have been incidentally detected during surgery, as reported in the literature.⁶ Presently, in cases involving clinical suspicion, diagnosis is usually made with Doppler US and supported by MRI.

Mittal et al.⁷ and Leung⁸ divided polyorchidism into four groups based on the anatomical variations. More recently, Bergholz et al.¹ proposed a new anatomical classification based on the functional taxonomy of polyorchidism so as to standardize the diagnosis and management of extra testes according to the reproductive potential (Table 1).

The preferred treatment for polyorchidism remains controversial, with orchiopexy and orchiectomy being debated options. The risk of malignancy and the contribution to the reproduction of the supernumerary testis pose a dilemma in making a final decision. The most widely accepted view involves preserving the supernumerary testis although orchiectomy is recommended if malignancy is suspected.⁹



Corresponding author: Şenay Bengin Ertem, Department of Radiology, Çanakkale Onsekiz Mart University Faculty of Medicine, Çanakkale, Türkiye

e-mail: benginertem@gmail.com

Received: October 23, 2024 **Accepted:** November 28, 2024 **Available Online Date:** March 03, 2025 • **DOI:** 10.4274/balkanmedj.galenos.2024.2024-10-81

Available at www.balkanmedicaljournal.org

ORCID iDs of the authors: Ş.B.E. 0000-0002-7237-6061; M.R. 0000-0002-2941-8879; K.Ö. 0000-0001-5422-6492.

Cite this article as: Ertem ŞB, Reşorlu M, Öz K. Supernumerary Testis (Polyorchidism). *Balkan Med J.*; 2025; 42(2):168-9.

Copyright@Author(s) - Available online at <http://balkanmedicaljournal.org/>

TABLE 1. Classification of Polyorchidism by Bergholz et al.¹

Type	Drainage status of the supernumerary testis	Subtype	Relation to the epididymis and ipsilateral adjacent testis
A	Drained by VD	A1	has its own epididymis and VD
		A2	has its epididymis but shares a common VD with the adjacent testis
		A3	shares a common epididymis and VD with the adjacent testis
B	Not drained by a VD	B1	has its epididymis
		B2	does not have its epididymis

VD, vas deferens.

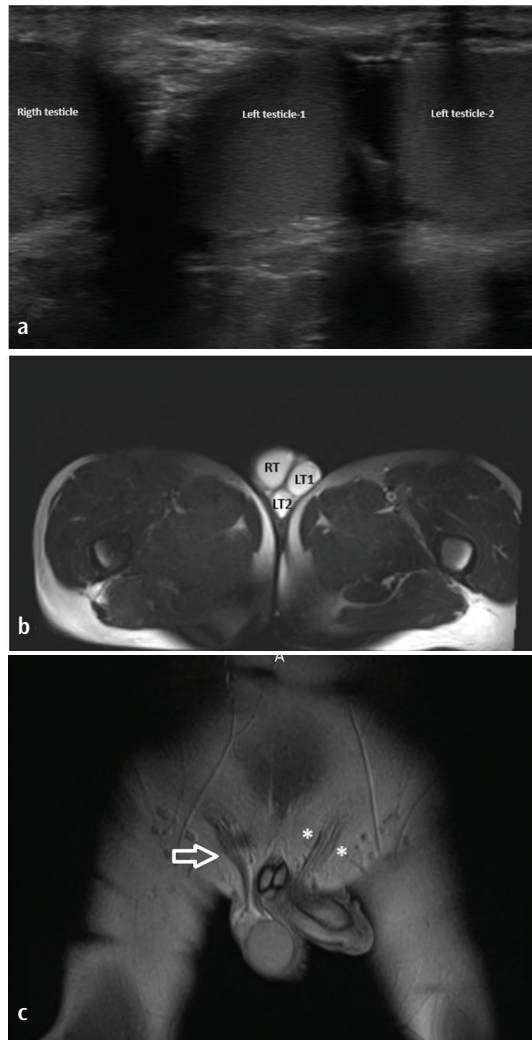


FIG. 1. (a) Testicular ultrasound reveals an oval-shaped supernumerary testicle adjacent to the normal testicle in the left scrotum, with similar echogenicity and vascularity to the normal testicle and its epididymis. (b) In the axial T2-weighted pelvic MRI shows an extra testicle adjacent to a normal testicle on the left side of the scrotum. The signal intensities of all three testicles were normal high signal. (c) In the coronal T1-weighted pelvic MRI sequence, each testicle shows its own epididymis and vas deferens (white arrow: right vas deferens, white stars: vas deferens of the left normal and supernumerary testis).

MRI, magnetic resonance imaging; RT, right testicle; LT1 and LT2, left normal and supernumerary testicles, respectively.

Informed Consent: Informed consent was obtained from the patient.

Authorship Contributions: Concept- Ş.B.E., M.R., K.Ö.; Design- Ş.B.E., M.R., K.Ö.; Supervision- Ş.B.E., M.R., K.Ö.; Fundings- Ş.B.E., M.R., K.Ö.; Materials- Ş.B.E., M.R., K.Ö.; Data Collection and/or Processing- Ş.B.E., M.R., K.Ö.; Analysis and/or Interpretation- Ş.B.E., M.R., K.Ö.; Literature Search- Ş.B.E., M.R., K.Ö.; Writing- Ş.B.E., M.R., K.Ö.; Critical Review- Ş.B.E., M.R., K.Ö.

Conflict of Interest: No conflict of interest was declared by the authors.

REFERENCES

- Bergholz R, Koch B, Spieker T, Lohse K. Polyorchidism: a case report and classification. *J Pediatr Surg.* 2007;42:1933-1935. [CrossRef]
- Artul S, Habib G. Polyorchidism: two case reports and a review of the literature. *J Med Case Rep.* 2014;8:464. [CrossRef]
- Kanbar A, Dabal C, El Khoury J, et al. Diagnosis and management of polyorchidism: a case report and literature review. *Case Rep Urol.* 2023;2023:1620276. [CrossRef]
- Sheah K, Teh HS, Peh OH. Supernumerary testicle in a case of polyorchidism. *Ann Acad Med Singap.* 2004;33:368-370. Erratum in: *Ann Acad Med Singapore.* 2004;33:547. [CrossRef]
- Nocks BN. Polyorchidism with normal spermatogenesis and equal sized testes: a theory of embryological development. *J Urol.* 1978;120:638-640. [CrossRef]
- Kumar B, Sharma C, Sinha DD. Supernumerary testis: a case report and review of literature. *J Pediatr Surg.* 2008;43: E9-E10. [CrossRef]
- Mittal PG, Peters NJ, Malik MA, Samujh R. Intraoperative dilemmas in polyorchidism: to pex or not to pex!! *J Indian Assoc Pediatr Surg.* 2020;25:175-177. [CrossRef]
- Leung AK. Polyorchidism. *Am Fam Physician.* 1988;38:153-156. [CrossRef]
- Bergholz R, Wenke K. Polyorchidism: a meta-analysis. *J Urol.* 2009;182:2422-2427. [CrossRef]