



## Half-and-Half Nails and Terry's Nails: Distinct Nail Manifestations of the Same Underlying Chronic Kidney Disease

✉ Marta Szepletowska<sup>1,2</sup>, ✉ Bartosz Lisicki<sup>3</sup>, ✉ Andrzej K. Jaworek<sup>1</sup>, ✉ Magdalena Krajewska<sup>4,5</sup>,  
✉ Jacek C. Szepletowski<sup>6,7</sup>

<sup>1</sup>Department of Dermatology, Jagiellonian University Medical College, Cracow, Poland

<sup>2</sup>Doctoral School of Medical and Health Sciences, Jagiellonian University Medical College, Cracow, Poland

<sup>3</sup>Lower Silesia Oncology, Pulmonology and Hematology Center, Wroclaw, Poland

<sup>4</sup>Division of Nephrology, Transplantation Medicine and Clinical Immunology, Faculty of Medicine, Wroclaw University of Science and Technology, Wroclaw, Poland

<sup>5</sup>Clinical Department of Transplant Surgery and Liver Surgery, 4<sup>th</sup> Military Hospital, Wroclaw, Poland

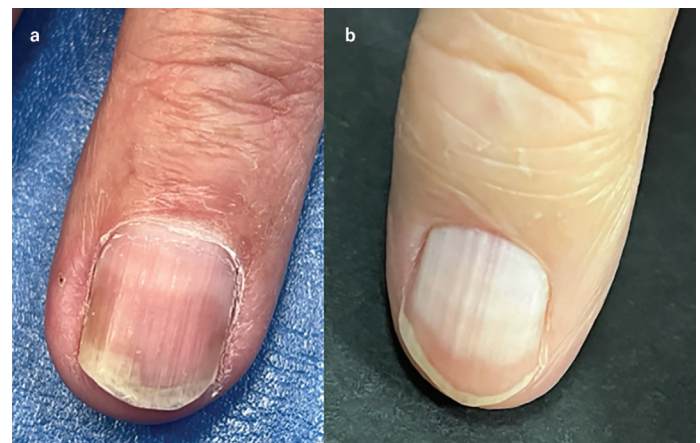
<sup>6</sup>Division of Dermatology, Venereology and Clinical Immunology, Faculty of Medicine, Wroclaw University of Science and Technology, Wroclaw, Poland

<sup>7</sup>Department of Dermato-Venereology, 4<sup>th</sup> Military Hospital, Wroclaw, Poland

A 68-year-old man undergoing maintenance hemodialysis, who was routinely screened for skin abnormalities, presented with nail discoloration. He had developed chronic renal failure secondary to type II diabetes mellitus and had been on hemodialysis for the past 3 years. Examination revealed that all fingernails and toenails were affected. The distal portion of the nails (50–60% of the nail length) showed a sharply demarcated brownish band. In most nails, particularly the fingernails, the lunula was clearly visible. Additionally, mild longitudinal ridging was observed. A diagnosis of half-and-half nails was made (Figure 1a). The patient was unaware of any nail abnormalities.

Another 53-year-old man had a long history of glomerulonephritis that had progressed to chronic renal insufficiency. Renal replacement therapy had been initiated 42 months before presentation, and he had been maintained on hemodialysis up to the time of examination. All of the patient's fingernails and toenails were affected. The nails appeared white and pale, with only a narrow distal band of normal pinkish-brown coloration. The nail plates exhibited a ground-glass appearance. The lunula was absent in all nails (Figure 1b). A diagnosis of Terry's nails was established. Although the patient could not specify the onset of the nail changes, he associated their appearance with the period of hemodialysis treatment.

Cutaneous manifestations are common in patients with chronic kidney disease (CKD). These include CKD-associated pruritus, xerosis, skin discoloration, calciphylaxis, acquired perforating dermatosis, pseudoporphyria, bullous disease of hemodialysis, and nephrogenic systemic fibrosis.<sup>1</sup> In contrast, nail abnormalities associated with CKD



**FIG. 1.** Nail abnormalities in maintenance hemodialysis patients: half-and half nails (a) and Terry's nails (b).



**Corresponding author:** Jacek C. Szepletowski, Division of Dermatology, Venereology and Clinical Immunology, Faculty of Medicine, Wroclaw University of Science and Technology; Department of Dermato-Venereology, 4<sup>th</sup> Military Hospital, Wroclaw, Poland

**e-mail:** jacek.szepletowski@pwr.edu.pl

**Received:** January 21, 2026 **Accepted:** February 10, 2026 **Available Online Date:** June 1, 2026 • **DOI:** 10.4274/balkanmedj.galenos.2026.2026-1-208

Available at [www.balkanmedicaljournal.org](http://www.balkanmedicaljournal.org)

**ORCID iDs of the authors:** M.S. 0000-0002-4843-4073; B.L. 0009-0005-6900-1903; A.K.J. 0000-0002-7779-2785; M.K. 0000-0002-2632-2409; J.C.S. 0000-0003-0766-6342.

**Cite this article as:** Szepletowska M, Lisicki B, Jaworek AK, Krajewska M, Szepletowski JC. Half-and-Half Nails and Terry's Nails: Distinct Nail Manifestations of the Same Underlying Chronic Kidney Disease. *Balkan Med J.* 2026;43:343-344

Copyright@Author(s) - Available online at <http://balkanmedicaljournal.org/>

have received relatively little attention in the literature.<sup>2</sup> The most frequently reported CKD-related nail abnormalities include half-and-half nails, absent lunula, Terry's nails, splinter hemorrhages, and Muehrcke's nails.<sup>2,3</sup>

Half-and-half nails, also known as Lindsay's nails, are characterized by a sharp chromatic demarcation between the proximal whitish nail bed and a distinctly demarcated reddish-brown to brown discoloration of the distal nail bed, typically involving 20–60% of the nail length.<sup>3,4</sup> Although strongly associated with renal disease, half-and-half nails are not specific to CKD and have been observed in other systemic conditions and in healthy older adults.<sup>3</sup> The pathogenesis of half-and-half nails remains incompletely understood. However, the distal nail bed discoloration is believed to be predominantly pigmentary in nature, resulting from increased melanin deposition rather than purely vascular changes. This hypothesis is supported by the clinical observation that the distal reddish-brown to brown band does not blanch under pressure, indicating a lack of significant vascular contribution. Uremic toxins and metabolic disturbances associated with CKD may stimulate melanocyte activity in the nail matrix or nail bed, leading to melanin accumulation in the distal portion of the nail.<sup>3,4</sup> Terry's nails present as bilaterally symmetrical, diffuse whitening of the nail bed involving all fingernails, with a narrow distal band measuring approximately 1–2 mm that retains a pinkish color. The lunula is absent.<sup>3</sup> The characteristic diffuse white, ground-glass appearance of the nail bed in Terry's nails is thought to result primarily from vascular and hemodynamic alterations, including reduced perfusion of the nail bed, increased connective tissue, and changes in nail bed vascularity. These hemodynamic alterations are consistent with the systemic conditions most commonly associated with Terry's nails, including

CKD, chronic liver disease, congestive heart failure, and aging.<sup>3,5,6</sup> In conclusion, careful nail examination may provide valuable clinical information in patients with CKD. The present cases illustrate that the same underlying disease, CKD, can manifest with different nail abnormalities, reflecting distinct pathophysiological mechanisms. Awareness of this variability may help clinicians recognize subtle signs of renal disease and underscores the importance of nail examination in patients with CKD.

**Informed Consent:** Informed consent was obtained from both patients for the presentation and publication of their clinical data and photographs.

**Authorship Contributions:** Concept- M.S., B.L., J.C.S.; Design- M.S., B.L., J.C.S.; Supervision- A.K.J. M.K. J.C.S.; Data Collection or Processing- M.S., B.L.; Analysis and/or Interpretation- M.S., B.L.; Literature Review- M.S., B.L.; Writing- M.S.; Critical Review- M.S., B.L., A.K.J. M.K., J.C.S.

**Conflict of Interest:** No conflict of interest was declared by the authors.

## REFERENCES

1. Glennon CM, Nigwekar SU, Kroshinsky D, Tucker JK. Skin disorders in kidney disease: core curriculum 2026. *Am J Kidney Dis.* 2026;87:102-114. [\[CrossRef\]](#)
2. Salem A, Al Mokadem S, Attwa E, Abd El Raouf S, Ebrahim HM, Faheem KT. Nail changes in chronic renal failure patients under haemodialysis. *J Eur Acad Dermatol Venereol.* 2008;22:1326-1331. [\[CrossRef\]](#)
3. Iorizzo M, Starace M, Pasch MC. Leukonychia: what can white nails tell us? *Am J Clin Dermatol.* 2022;23:177-193. [\[CrossRef\]](#)
4. Raja SM. Chronic kidney disease entertained from Lindsay's nails: a case report and literature review. *Clin Case Rep.* 2021;9:e04426. [\[CrossRef\]](#)
5. Holzberg M, Walker HK. Terry's nails: revised definition and new correlations. *Lancet.* 1984;1:896-899. [\[CrossRef\]](#)
6. Nia AM, Ederer S, Dahlem KM, Gassanov N, Er F. Terry's nails: a window to systemic diseases. *Am J Med.* 2011;124:602-604. [\[CrossRef\]](#)