

Case Report / Olgu Sunumu

Neonatal Forearm Compartment Syndrome: Case Report

Neonatal Kompartman Sendromu

Atakan AYDIN, Ahmet BİÇER, Karaca BAŞARAN, Barış KEKLİK

Department of Plastic and Reconstructive Surgery, Division of Hand Surgery, İstanbul Medical Faculty of İstanbul University, İstanbul

Submitted / Başvuru tarihi: 06.09.2008 **Accepted / Kabul tarihi:** 14.10.2008

Neonatal compartment syndrome is a rare condition mainly involving the upper extremity with ulcerated and necrotic lesions. It should be evaluated in detail due to the similarity with other conditions like necrotizing fasciitis, neonatal gangrene, and congenital varicella, etc. Early diagnosis and treatment have a paramount importance for the best outcome. To emphasize this, we would like to present a newborn with the forearm compartment syndrome diagnosed promptly and treated surgically.

Key words: Neonatal; compartment syndrome; forearm.

Neonatal kompartman sendromu çoğu zaman üst ekstremitede ülserasyon, nekroz ve doku kaybıyla seyreden nadir bir durumdur. Nekrotizan fasiit, neonatal gangren, konjenital varisella ve buna benzer klinik tablolarla karışması nedeniyle detaylı bir araştırma gerektirmekte ve iyi sonuç açısından da erken tanı ve tedavi önemli olmaktadır. Bunu vurgulamak amacıyla erken tanı koyup, cerrahi olarak tedavi ettiğimiz bir neonatal kompartman sendromu olgusunu sunduk.

Anahtar sözcükler: Neonatal; kompartman sendromu; önkol.

Compartment syndrome, first described by Richard von Volkmann is an entity characterized by the increased pressure within a confined anatomic space resulting in ischemia and necrosis.^[1] Although commonly observed in adults with pre-existing etiologies like fractures, burns, crush injuries and external compressions, congenital form has been described, as well.^[2,3] The importance of the newborn form lies on its similarity with other entities, where a definite diagnosis may be confusing. In addition, the urgency of the treatment, mainly fasciotomy, makes this subject more important.^[4] In this paper, we'd like to present an interesting case of a newborn forearm compartment syndrome which was diagnosed and treated promptly.

CASE REPORT

An emergency call was made from the newborn unit for a 10-hour-old 2900 g infant baby born with unusual

swelling and patchy necrosis on his right forearm (Fig. 1). The history revealed no metabolic or circulatory problems. The delivery and perinatal periods were eventless. No prior injection to the affected extremity was made. On examination, his right forearm and hand were swollen, red, and the whole extremity was immobile. A necrotic skin lesion on the dorsal aspect of the proximal one thirds of the forearm was visible. His radial pulse was absent. A dermatology consultation was requested together with pediatric and surgical evaluation. Viral and bacterial cultures were negative. His intracompartmental pressure was measured as 36 mm Hg with a Whitesides device. The diagnosis of neonatal compartment syndrome was made with no apparent underlying cause. Early debridement of the necrotic lesions with full excision of the skin deep to the level of fascia plus fasciotomy were performed initially. Muscles, nerves and other vital components were found

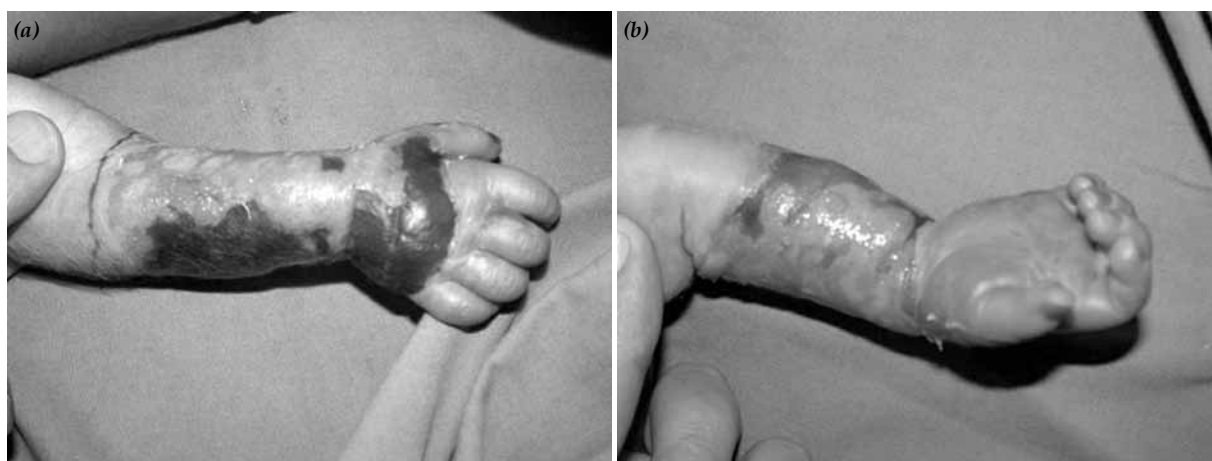


Fig. 1. (a) Appearance of the infant's forearm with necrosis and edema (dorsal aspect). (b) Volar aspect of the forearm at birth.

to be viable and left intact. Later skin grafting was done for the granulated open wound (Fig. 2). Physiotherapy and splinting were other measures taken, aiming to prevent contracture and spastic posture seen due to the first motor neuron damage observed during follow-up. He was at 8 months of age with mild mental retardation and spastic posture at the last examination. Minimal contracture and hypertrophic scar were noted, as well (Fig. 2).

DISCUSSION

Neonatal compartment syndrome manifests as tissue necrosis, bullae and edema, most commonly observed in upper extremity.^[5] Lesions have been rarely examined histologically previously and mainly coagulative and subcutaneous fat necrosis were observed.^[3] Although eliminating the underlying cause, elevation, immobilization of the affected limb, surgical debridement and fasciotomy are treatment options for adults, the literature lacks in correct definition and rational approach to the rare neonatal form of this syndrome.

From the etiologic point of view, Cham et al.^[2] reported cases of neonatal compartment syndromes with

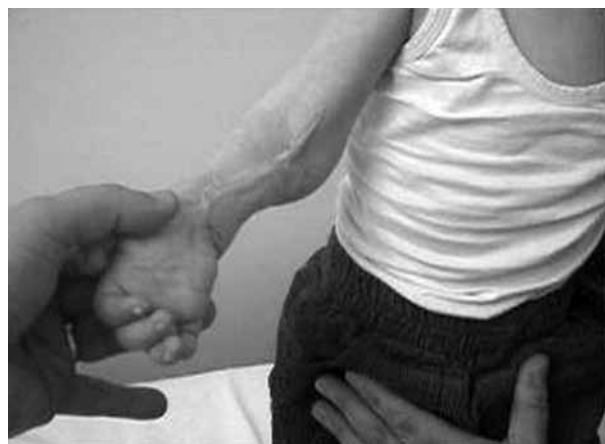

Fig. 2. At 4 months of age, following debridement and fasciotomy. Note the hypertrophic scar.

proposed causes including: oligohydramnios, death of a co-twin, gestational diabetes, excessive maternal weight gain, prematurity, etc. In the case he reported, unusual placement of the hand of the affected limb was suggested as a causative factor. However, all of these factors are unproven.

In addition, the condition needs to be distinguished from other entities like cutis aplasia, constriction band syndrome, neonatal gangrene, subcutaneous fat necrosis, necrotizing fasciitis, congenital varicella and epidermolysis bullosa, etc.^[2,6,7] Despite the requirement of early diagnosis and prompt intervention, the treatment option, whether surgical or medical, may vary. Therefore, a detailed work up with a team of plastic surgeons, neonatologists and dermatologists is mandatory for the definitive diagnosis.

Delayed intervention, improper treatment may lead to a devastating sequelae: Volkmann-Lesser ischemic contracture with permanent contracture of the joints, tissues loss, skeletal changes, muscle fibrosis and nerve dysfunctions. Treatment becomes much more complex with this condition including tendon and functional muscle transfers, arthrotomies, arthrodesis, tenodesis, corrective osteotomies and even amputations.^[8] Therefore, early detection of the condition and prompt transportation of the patient to an institution with adequate neonatology critical care and hand surgery departments are mandatory for the best outcome.

REFERENCES

1. Trice M, Colwell CW. A historical review of compartment syndrome and Volkmann's ischemic contracture. *Hand Clin* 1998;14:335-41.
2. Cham PM, Drolet BA, Segura AD, Esterly NB. Congenital Volkmann ischaemic contracture: a case report and review. *Br J Dermatol* 2004;150:357-63.
3. Raimer L, McCarthy RA, Raimer D, Colome-Grimmer M. Congenital Volkmann ischemic contracture: a case report. *Pediatr Dermatol* 2008;25:352-4.

4. Ragland R 3rd, Moukoko D, Ezaki M, Carter PR, Mills J. Forearm compartment syndrome in the newborn: report of 24 cases. *J Hand Surg [Am]* 2005;30:997-1003.
5. Silfen R, Amir A, Sirota L, Hauben DJ. Congenital Volkmann-Lesser ischemic contracture of the upper limb. *Ann Plast Surg* 2000;45:313-7.
6. Hernández-Martín A, de Unamuno P, Fernández-López E. Congenital ulcerated subcutaneous fat necrosis of the newborn. *Dermatology* 1998;197:261-3.
7. Fenniche S, Daoud L, Benmously R, Ben Ammar F, Khelifa I, Chaabane S, et al. Subcutaneous fat necrosis: report of two cases. *Dermatol Online J* 2004;10:12.
8. Gulgonen A. Compartment syndrome. In: Green DP, Hotchkiss RN, Pederson WC, editors. *Green's operative hand surgery*. Vol. 2, 5th ed. Philadelphia: Elsevier/Churchill Livingstone; 2005. p. 1985-2005.