

Reconstruction of the Chest Wall Defects with Mammary Dermoglandular Advancement Flaps in Female Complicated Cases

Komplike Kadın Olgularda Toraks Duvarı Defektlerinin Meme İlerletme Flepleri ile Onarımı

Atakan AYDIN, Erdem GÜVEN, Barış KEKLİK, Karaca BAŞARAN, Berker ÖZKAN¹

Departments of Plastic and Reconstructive Surgery and ¹Thoracic Surgery, İstanbul Medical Faculty of İstanbul University, İstanbul

Submitted / Başvuru tarihi: 23.08.2008 **Accepted / Kabul tarihi:** 08.10.2008

Objectives: There are several myocutaneous flaps used for chest wall reconstruction. However, in some cases, usage of these flaps is not suitable. If the patient is female, we aimed to show that use of the breast tissue while saving its lateral and medial pedicles is an option for the reconstruction.

Patients and Methods: Our study included four female patients who presented with recurrence of cancer (50-year-old with malign thymoma, 60-year-old with left lung cancer, 41-year-old with chondrosarcoma, and 49-year-old with a history of intraductal carcinoma). Mammary tissue can be elevated either to its lateral or medial pedicles and used as an advancement flap.

Results: Breast tissue was used for the reconstruction as an advancement flap on either its lateral or medial pedicles on all patients. In the follow-up of the patients, there was no circulatory problem of the flaps or necrosis. The first three patients have died due to their primary diseases. The fourth patient is being followed up by the oncology department with no local recurrence yet.

Conclusion: In selected female patients, breast tissue is a good choice for reconstruction due to its rich blood supply and easy accessibility.

Key words: Chest wall reconstruction; flap; breast.

Amaç: Toraks duvarı defektlerinin rekonstrüksiyonunda miyokütan flepler kullanılmaktadır. Fakat bazı hastalarda bu fleplerin kullanımı uygun olmayabilir. Eğer hasta bayansa, meme dokusunun lateral veya medial pedikülleri korunarak ilerletme flebi şeklinde rekonstrüksiyon amaçlı kullanılabileceğini göstermek amacındayız.

Hastalar ve Yöntemler: Çalışmamıza göğüs cerrahisine kanser nüksü nedeniyle başvurmuş dört kadın hasta dahil edildi (50 yaşında malin timoma, 60 yaşında sol akciğer kanseri, 41 yaşında kondrosarkom, 49 yaşında intraduktal karsinom nüksü). Meme dokusu lateral veya medial pediküllerine baze ilerletme flebi olarak kullanılabilir. bilmektedir.

Bulgular: Tüm hastalarda rekonstrüksiyon meme dokusunun medial veya lateral pediküllerine baze ilerletme flebi şeklinde kullanımıyla yapılmıştır. Takiplerinde flep dolaşımıyla ilgili bir soruna veya nekroza rastlanmamıştır. İlk üç hasta primer hastalıkları nedeniyle kaybedilmiştir, dördüncü hasta onkoloji tarafından takiptedir ve lokal nüks yoktur.

Sonuç: Seçilmiş kadın olgularda zengin kanlanması ve kolay ulaşılabilir olması nedeniyle meme dokusu rekonstrüksiyon için iyi bir seçenek olabilmektedir.

Anahtar sözcükler: Göğüs duvarı rekonstrüksiyonu; flep; meme.

There are two general categories of chest wall defects: acquired and congenital. Acquired defects are tumors (primary or recurrent), infections, radiation injuries, and trauma.

Patients occasionally require major chest wall reconstruction. There are several flaps used for chest wall reconstruction, including latissimus dorsi, rectus abdominis, pectoralis major myo-

cutaneous flaps and omental flap.^[1] However, in some cases, usage of these flaps are not suitable for patients with history of previous ipsilateral chest wall surgery or high-dose radiation therapy to the chest wall or axilla. The general medical condition or the existence of comorbid diseases (diabetes mellitus, vascular pathologies, etc.) limits the usage of common procedures for the reconstruction. In these situations, if the patient is female, use of the breast tissue is an option for the reconstruction.

PATIENTS AND METHODS

The blood supply of medial to central parts of the breast comes from perforating branches of the internal mammary artery (60%); whereas to the lateral part of the breast from the lateral thoracic artery and intercostal perforators. By the means of this rich blood supply, mammary tissue can be elevated either to its lateral or medial pedicles and used as an advancement flap.

Case I was a 50-year-old woman who had undergone treatment for invasive malign thymoma in the thoracic surgery department. A month after the tumor resection, due to osteomyelitis of the sternum, mediastinal debridement was done. Due to the dehiscence of the sternum, the thoracic surgeons performed hemisternectomy, also the defect was closed by an omental flap (Fig. 1a). The use of pectoralis major myocutaneous flap had been planned, however during the operation, it was understood that the pedicle of the muscle was damaged due to previous surgical procedures and infections. Because of the

patient's current general medical condition, a more advanced reconstructive procedure such as free flap could not be done. However, during the operation, it was realized that the breast tissue of the patient was large enough to sufficiently cover the defect. Thus, right breast of the patient was split from the medial part to the areola. The breast was dissected above the pectoralis muscle and transposed over the defect (Fig. 1b).

Case II was a 60-year-old woman with a history of left lung inferior lobe malignancy. Left inferior lobectomy had been performed by thoracic surgeons. One year after this operation, the metastatic tumoral formation on the sternum was detected. The dimensions of the tumor were 10x10 cm. Thoracic surgeons resected tumor by 2 cm safe margin. The first four ribs were partially resected due to the invasion of the tumor. However, rigid tissue reconstruction could not be done because of the widespread dissemination of fibrosis. During the surgery, we noted -like the previous case- the presence of infection and fibrosis; and the history of previous surgery limits the use of the musculocutaneous flaps, free flaps, or the other advanced reconstructive options in this case. The gender of the patient supplies us with a robust and easy accessible flap with its own blood supply. In this case, we used bilateral mammary tissues as advancement flaps to cover the defect.

Case III was a 41-year-old woman with a history of chondrosarcoma of the head of the humerus. Head of the humerus and scapula had

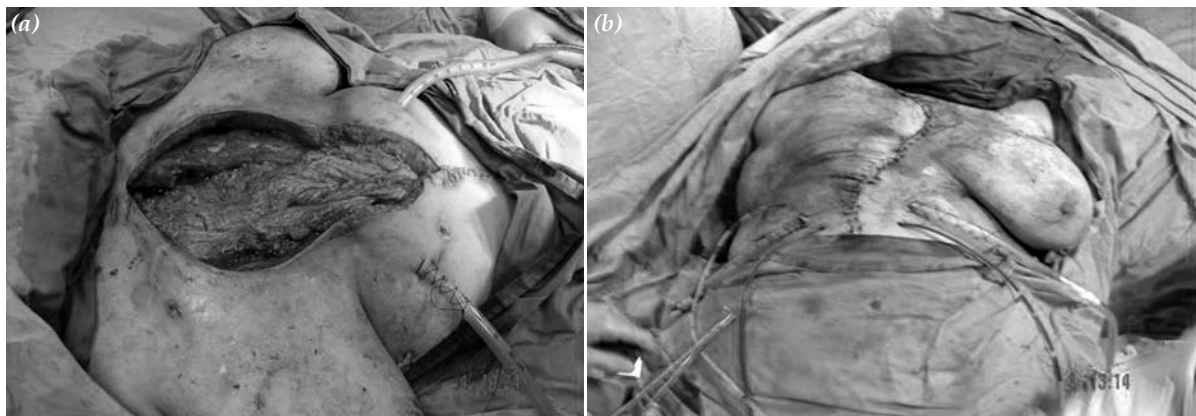


Fig. 1. (a) Defect after the tumor resection. (b) Defect reconstructed by mamarian advancement flap.

been resected two years before. In the follow-up of the patient, she had a second operation due to the recurrence, however, six months after the second operation she had a recurrence again. After three courses of chemotherapy and one course of radiotherapy, tumor progressed. Because of the progression, thoracic surgeons decided to perform a curative surgery. They performed right scapulothoracic disarticulation and partial resection of the first and second ribs. Due to the previous operations, radiotherapy, and also because of the high morbidity of the operation, it was hard to make a decision of flap surgery. During the operations, right breast tissue had been protected. We elevated the breast tissue by the lateral side and used it as an advancement composite flap to cover the defect on the lateral and posterolateral side of the body.

Case IV was a 49-year-old female patient with a history of intraductal carcinoma. She had a mastectomy and postoperative adjuvant chemo- and radiotherapy. In follow-up of the patient, chemo- and radiotherapy had been performed twice because of local recurrences. In 2007, she was referred to the department of thoracic surgery due to sternum and skin invasions (Fig. 2a). Partial sternectomy, partial anterior rib and unblock metastatic tumor resections were performed (Fig. 2b). During the surgery, bilateral internal mammary vessels were spared. The chest wall defect was reconstructed by placing two steel pectus bars and elevating the breast

tissue, starting from its medial border, staying over the pectoral fascia till to its lateral pedicle, and advancing through the defect (Fig. 2c).

RESULTS

In all of the patients, breast tissue was used for the reconstruction as an advancement flap on either its lateral or medial pedicles. In the follow-up of the patients, there was no circulatory problem of the flaps or necrosis. The first three patients died due to their primary diseases. The fourth patient is being followed by the oncology department and there has been no local recurrence yet.

DISCUSSION

There are several ways for reconstruction of the chest wall defects. Traditionally, soft tissue coverage has been performed by using skin flaps such as deltopectoral flap.^[2] However, by clinical use of musculocutaneous flaps, these became preferred instead of coverage. Latissimus dorsi musculocutaneous flap for reconstruction of the anterior chest wall defects was first described in 1906 by Tansini^[3] and in the second half of the century, it became a common flap for the chest wall defects. However, previous thoracotomy or axillary incisions could have made possible damage to the pedicle. Other muscles that can be used for reconstruction are rectus, pectoralis, and serratus muscles. They have been well described in the past for chest wall reconstruction.^[4] Free tissue transfer was infrequently

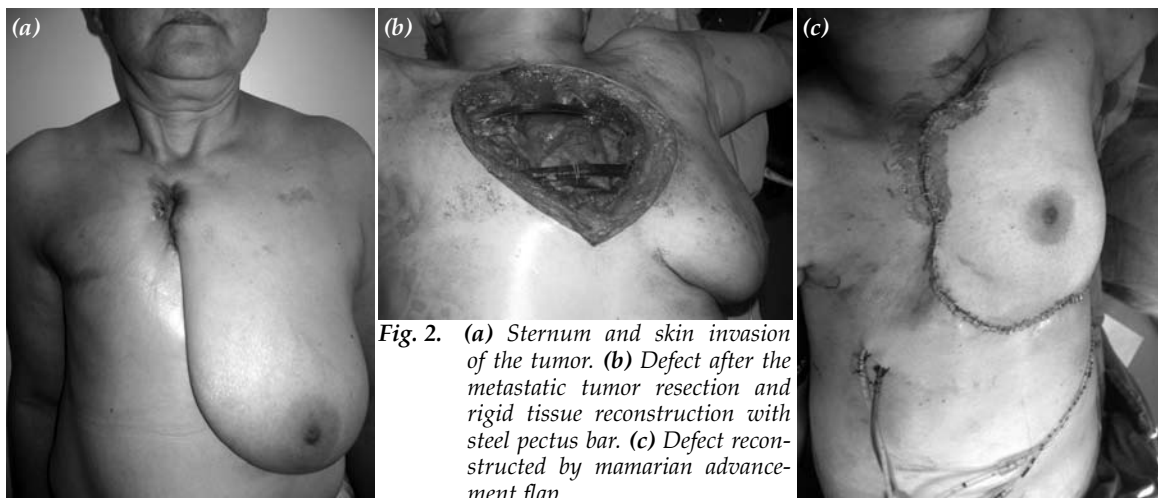


Fig. 2. (a) Sternum and skin invasion of the tumor. (b) Defect after the metastatic tumor resection and rigid tissue reconstruction with steel pectus bar. (c) Defect reconstructed by mammary advancement flap.

used and reserved for the conditions where the regional flaps failed or were unavailable.

Although the reconstructive algorithms can be used as a guide, the method which will be used for reconstruction should be individualized. The general medical condition, comorbidity of the patient, presence of a previous surgery, infection, history of radiation therapy limit the use of flaps or more advanced reconstruction methods. In these conditions, especially if the patient is female, mammary tissue is a wise choice.

There are several examples in which breasts have been used for chest wall reconstruction. An example of usage of breast tissue is cyclops flaps. This flap allows the breast to be elevated on its lateral pedicle and a large breast will allow advancement to the contralateral anterior axillary line.^[5] Split breast flap is another example for the breast reconstruction. A superior-based reduction mammoplasty is performed and the excess inferior part is dissected, based on its medial perforators and rotated to contralateral side.^[6] Kolodziejcki et al.^[7] introduced 13 consecutive patients with local chest wall recurrence, subsequent to mastectomy for breast malignancy who underwent full-thickness chest wall resection. In five of these patients, contralateral breasts were used for reconstruction.

The usage of the breast tissue is an option for reconstruction in selected female patients for

whom regional musculocutaneous or free flaps are unsuitable due to the general medical condition, the existence of comorbid diseases (diabetes mellitus, vascular pathologies, etc.), infection in the operative area, complications during the surgery (damage to the pedicle of flap), and previous radiation therapy, we think that mammary dermoglandular advancement flap procedure is a good alternative in selected patients to cover chest wall defects.

REFERENCES

1. Reece GP, Goldberg D. Chest wall reconstruction. In: Evans GRD, editor. Operative plastic surgery. 1st ed. New York: McGraw-Hill; 2000. p. 698-718.
2. Bakamjian VY. A two-stage method for pharyngoesophageal reconstruction with a primary pectoral skin flap. *Plast Reconstr Surg* 1965;36:173-84.
3. Abbes M, Huss M. Breast and chest wall reconstruction by latissimus dorsi myocutaneous flap (238 cases). *The Breast* 1995;4:33-9.
4. Jones G, Jurkiewicz MJ, Bostwick J, Wood R, Bried JT, Culbertson J, et al. Management of the infected median sternotomy wound with muscle flaps. The Emory 20-year experience. *Ann Surg* 1997;225:766-76.
5. Hughes KC, Henry MJ, Turner J, Manders EK. Design of the cyclops flap for chest-wall reconstruction. *Plast Reconstr Surg* 1997;100:1146-51.
6. Schoeller T, Bauer T, Haug M, Otto A, Wechselberger G, Piza-Katzer H. A new contralateral split-breast flap for breast reconstruction and its salvage after complication: an alternative for select patients. *Ann Plast Surg* 2001;47:442-5.
7. Kolodziejcki LS, Wysocki WM, Komorowski AL. Full-thickness chest wall resection for recurrence of breast malignancy. *Breast J* 2005;11:273-7.