

Measurement of Temporomandibular Joint Mobility with an Inclinometer in Turkish Males and Females^{1*}

Türk Erkek ve Kadınlarda Temporomandibular Eklem Hareketlerinin İnklinometre ile Değerlendirilmesi

Ali YILMAZ¹, Levent ELEVLİ¹, Recep MESUT¹, Hakan TUNA²

Departments of ¹Anatomy and ²Physical Medicine and Rehabilitation, Medical Faculty of Trakya University, Edirne

Submitted / Başvuru tarihi: 30.07.2008 **Accepted / Kabul tarihi:** 18.08.2008

Objectives: The purpose of this study was to determine the range of motion (ROM) of the temporomandibular joint (TMJ) in males and in females by using digital inclinometer and its correlation with the interincisial distance.

Patients and Methods: One hundred and five healthy (50 males, 55 females) volunteers who were studying at our university participated in this study. Maximum opening, right-left excursion and protraction degrees were determined with electronic digital inclinometer which was extremely sensitive but practicable. Besides, interincisial distance was measured by using vernier caliper during maximum mouth opening.

Results: The average values for males and females were found as follows: maximum mouth opening 30.58°, 27.16°; right excursion 4.96°, 6.85°; left excursion 5.40°, 7.43° and protraction 13.38°, 11.85°, respectively. Interincisial distances were measured as 52.4 mm in males and 52.2 mm in females.

Conclusion: The evaluation of ROM values for the TMJ are important in the diagnostic and treatment of the musculoskeletal and neurological diseases affecting joint movement. We conclude that interincisial distance measurements may be a practical method for the evaluation of the derangements in this joint.

Key Words: Biomechanics; temporomandibular joint; range of motion.

Amaç: Çalışmamızda dijital elektronik inklinometre kullanarak erkek ve kadınlarda temporomandibular eklem (TME) eklem hareket açıklığı (EHA) değerlerinin belirlenmesini ve interinsizal mesafe ile korelasyonunu araştırmayı amaçladık.

Hastalar ve Yöntemler: Üniversitemizin farklı bölümlerinde okuyan toplam 105 öğrenci (55 kadın, 50 erkek) gönüllü olarak deneye katıldı. Son derece hassas olmasına karşın kolay uygulanabilen bir alet olan elektronik dijital inklinometre ile maksimal açılma, sağ-sol ekskursiyon ve protraksiyon dereceleri belirlendi. Ayrıca maksimum ağız açıklığı esnasında interinsizal mesafe kayan kaliper yardımıyla ölçüldü.

Bulgular: Ölçümlerimiz sonucunda erkek ve kadınlarda sırasıyla maksimum açılma derecesi 30.58°, 27.16°; sağ ekskursiyon 4.96°, 6.85°; sol ekskursiyon 5.40°, 7.43° ve protraksiyon ise 13.38°, 11.85° olarak bulundu. İnterinsizal mesafe ise erkek deneklerimizde 52.4 mm, kadınlarda 52.2 mm olarak ölçüldü.

Sonuç: Eklem hareketlerini etkileyen romatizmal hastalıklar ve nörolojik kas hastalıklarının tanı ve tedavisinde TME'nin EHA değerleri önemli bir yer işgal etmektedir. Sonuç olarak, bu eklemle ilgili rahatsızlıklarda tanıya en kısa sürede ulaşmak için interinsizal mesafe ölçümlerinin de kullanılabileceği kanaatindeyiz.

Anahtar sözcükler: Biyomekanik; temporomandibular eklem; hareket açıklığı.

*Vⁿ Balkan Congress of Otorhinolaryngology, Head and Neck Surgery, September 7-10, 2006 Edirne, Turkey (5. Balkan Kulak Burun Boğaz Hastalıkları ve Baş-Boyun Cerrahisi Kongresi'nde sunulmuştur, 7-10 Eylül, 2006 Edirne, Turkey).

Correspondence (İletişim adresi): Dr. Ali Yılmaz, Trakya Üniversitesi Tıp Fakültesi Anatomi Anabilim Dalı, 22030 Edirne.

Tel: 0284 - 235 59 35 Fax (Faks): 0284 - 235 59 35 e-mail (e-posta): ayz51@yahoo.com

© Trakya Üniversitesi Tıp Fakültesi Dergisi. Ekin Tıbbi Yayıncılık tarafından basılmıştır. Her hakkı saklıdır.

© Medical Journal of Trakya University. Published by Ekin Medical Publishing. All rights reserved.

The morphology of temporomandibular joint (TMJ), which is a functional part of the stomatognathic system, varies between individuals. Many activities such as speaking, chewing, blowing and kissing are possible with a healthy TMJ.^[1,2]

Temporomandibular joint is a combination of ginglymus and planar joint types, articular eminence and mandibular fossa of the temporal bone and head of the mandible (condyloid process) providing its articular surfaces. The articular surfaces of the articular eminence and anterior part of the mandibular fossa are covered with fibrocartilage in contrast to the other synovial joints. Type I collagen fibres, major component of its structure, can not absorb compressive loads but they have great tensile strength.^[3-6]

The joint capsule is funnel-shaped, extending from the articular eminence and borders of the mandibular fossa above to the neck of the mandible below. Posterior part of the capsule is longer than the anterior and it also has more elastic fibres.^[7] The ligaments of the TMJ are not elastic. They do not have an active role in joint functions but constrain the joint movements. This joint has three functional and two assist ligaments. The first ones of the functional ligaments are discal ligaments connecting medial and lateral sides of the disc to the mandibular condyle. The discal ligaments, preventing the disc to move away from the condyle, provide the passive movements of the disc together with the condyle during its anterior and posterior movements. The capsular ligaments surrounding the joint prevent the joint surfaces from being disengaged. They provide proprioceptive feedback about the joint motion and position as they are heavily innervated.^[4,5] The thickened portion of the capsular ligaments, called temporomandibular ligament, is composed of oblique and horizontal parts. The oblique part controls the movement of the condyle. The horizontal part limits the posterior displacement of the condyle, so it protects the external acoustic meatus. Stylomandibular ligament, extending from the styloid process to the angle of the mandible limits the anterior movement of the mandible. Sphenomandibular ligament has no limiting role on the functional movement.^[2]

PATIENTS AND METHODS

One hundred and five 105 (50 males, 55 females) volunteers who were students of our university participated in our study. Randomized sampling method was used in the selection of participants and it was taken into consideration that the participants had no orthopaedic problems. The measurements were performed with "Electronic Digital Inclinometer" (Fig. 1a). Maximum range of motion (ROM) values were recorded for maximum mouth opening, right-left excursion and protraction, recording for each movement being performed three times. Interincisial distance was measured by using "vernier caliper" during maximum mouth opening.

Maximum mouth opening

Recordings were performed by placing the inclinometer's probe parallel to the body of the mandible while the participant was sitting on a chair, his/her vertebral column erect, neck being hyperextended (Fig. 1b).

Right-left excursion

Recordings were performed by placing the probe parallel to the right ramus of the mandible; the participant was requested to move his/her mandible to the right without opening his/her mouth while he/she was sitting erect, face looking forward. The same procedure was followed for the left side (Figure 1c, d).

Protraction

The inclinometer's probe was placed between the upper lip and mental protuberance and then the participant was requested to protract his/her mandible without opening his/her mouth (Fig. 1e).

Interincisial distance

The distance between the upper and lower incisors was measured using a ruler during maximum mouth opening (Fig. 1f).

Statistical analysis

Results are expressed as mean \pm SD. The one-sample Kolmogorov-Smirnov test was used to assess the normality distribution of continuous data. Independent samples t-test and Mann-

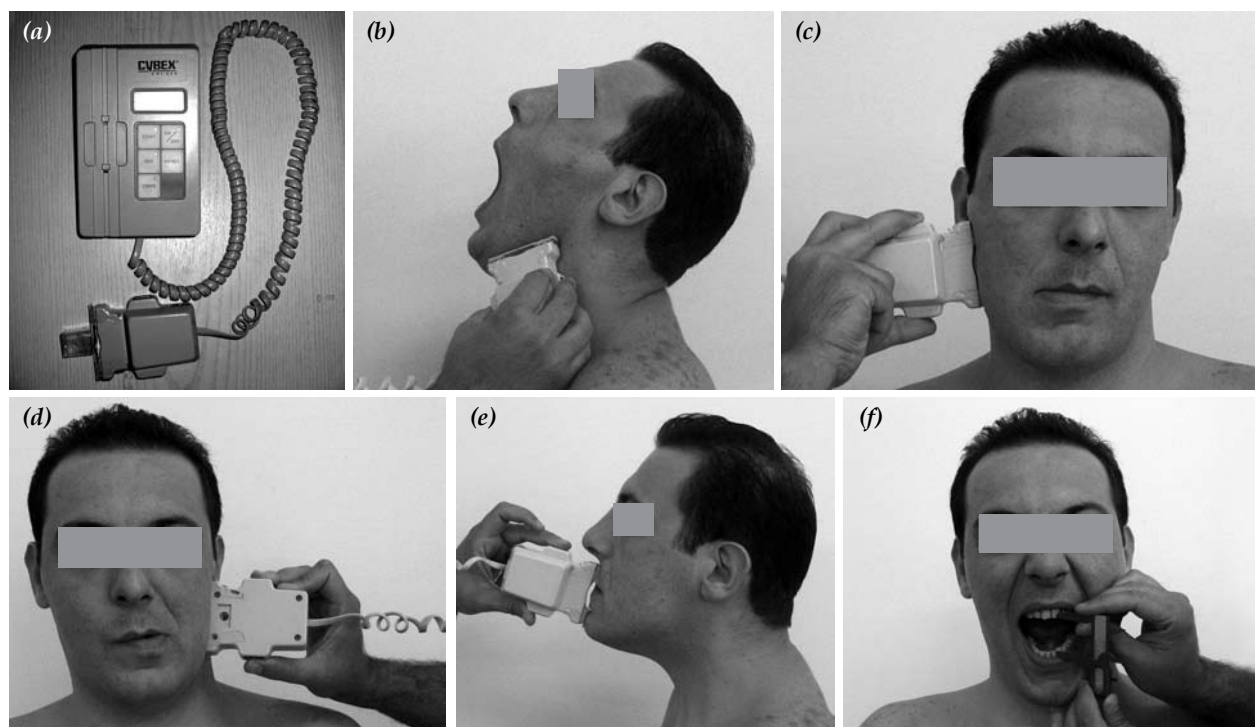


Fig. 1 (a) Cybex electronic digital inclinometer. (b) Maximum mouth opening. (c) Right excursion. (d) Left excursion. (e) Protraction. (f) Interincisal distance.

Whitney U test were used for comparison between genders for normal and non-normal distributed data, respectively. Spearman correlation analysis was used for relationships between variables.

In order to remove the effect of confounding factors ANCOVA test was used in comparison of variables between gender, the Bonferroni post-hoc test was used for multiple comparisons when significant result was obtained. STATISTICA 7.0 was used for statistical analysis. P value less than 0.05 was considered statistically significant.

RESULTS

We measured higher maximum mouth opening and protraction values ($30.58^{\circ} \pm 3.03$ and $13.38^{\circ} \pm 2.04$, respectively) in our male subjects compared to females. Right-left excursion movements are relatively higher in our female subjects ($6.85^{\circ} \pm 1.23$, $7.43^{\circ} \pm 1.39$, respectively). Interincisal distances are close to each other ($52.4 \text{ mm} \pm 0.41$; $52.2 \text{ mm} \pm 0.59$, respectively), (Table 1).

DISCUSSION

Temporomandibular joint is a complex joint and used in a myriad of daily activities. Its disorders are accompanied by muscular and facial pain, earache and headache.^[8,9] Therefore it has been thoroughly studied by the clinicians. Radiological and anthropometric methods are used in its evaluation.^[10-12] Landes et al.^[13] reported that ultrasonography is faster and has greater influence than MRI and axiography. The ratios of the ROM values of the TMJ in the horizontal and frontal planes is also used in its functional evaluation. Dijkstra et al.^[14] measured these ratios for the right and left sides as 6:1 and 6.6:1, respectively. Kim et al.^[12] stated the importance of the movements of the TMJ in the horizontal and frontal planes in the diagnosis of its diseases. Hochstedler et al.^[15] calculated the ratio of the maximum mouth opening and the lateral excursion movement as 4.4:1 in their 75 subjects. The electronic digital inclinometer we used differs from the other methods in that it allows the measurement of angular joint motion values and it's easy to use.^[16] The mean age of our

Table 1. Range of motion values of temporomandibular joint motions and correlations of interincisal distance with temporomandibular joint motions in Turkish males and females

	Males		Females	
	Mean±SD	Correlation of interincisal distance (r)	Mean±SD	Correlation of interincisal distance (r)
Age	21.26±1.68	–	19.41±1.168	–
Maximum opening (°)	30.58±3.03	0.791	27.16±3.87	0.764
Right excursion (°)	4.96±1.30	-0.072	6.85±1.23	0.102
Left excursion (°)	5.40±1.30	0.071	7.43±1.39	0.002
Protraction (°)	13.38±2.04	0.093	11.85±1.94	0.313
Interincisal distance (mm)	52.4±0.41	1	52.2±0.59	1

male subjects was 21.26±1.68 years while it was 19.41±1.18 years for the female subjects. There is a significant difference ($p=0.001$) between the two groups' mean ages. We used ANCOVA test to eliminate this difference. We found that the angular values for maximum mouth opening and protraction were higher in males than in females ($p=0.001$). This may be due to the longer posterior part of the articular capsule which allows the anterior displacement of the mandibular condyle during mouth opening and also to the capsule's higher elastic fibre content. In right-left excursion movements, females have statistically significant ($p=0.001$) higher values than males.

Yilmaz and Mesut^[3] reported angular values for maximum mouth opening, right-left excursion and protraction as 31.5°, 5.0°, 5.2° and 13.9°, respectively, in their study on 30 male subjects.

Naeije^[17] studied the relationship between the maximum mouth opening and kinematic and anthropometric factors in healthy subjects. He measured the maximum mouth opening as 34.7° in his study. Ferrario et al.^[18] measured the maximum mouth opening as 34.46° for the male subjects and 31.55° for the female subjects. The differences between the values in these studies may be attributed to the methods used in these studies.

Maximum interincisal distance measurements may be used in the evaluation of joint movement. In our study we did not find statistically significant difference in the interincisal distance between our male and female

subjects ($p=0.368$). The minimum value for this distance was reported as 35 mm by Demir and Güray^[19] which we found as 52.4 mm and 52.2 mm, respectively for males and females. There is difference between our values obtained from normal subjects and these patient-based studies. Ferrario et al.^[18] reported values of 55.68±5.39 mm and 45.60±7.03 mm for the male and female subjects, respectively.

In this study, another subject we focused on is the relationship of interincisal distance with TMJ movements. Therefore we investigated the correlation between the mean values for each of the TMJ movements and the mean interincisal distance values. In our correlation analysis, interincisal distance has the most influence on maximum mouth opening (0.79) in our male subjects. There is no correlation for right excursion (-0.072), left excursion (0.071) and protraction (0.093) movements. In female subjects, while maximum mouth opening has a strong correlation (0.76) there is a weaker correlation for protraction movement (0.37). There is no correlation for right-left excursion movements (0.102 and 0.002).

Rivera-Morales et al.^[20] measured the maximum mouth opening, right-left excursion and the protraction movements and compared them with mandibular kinesiography. They found the highest correlation between the maximum mouth opening and the mandibular kinesiography.

Temporomandibular joint movements are performed with the contraction-relaxation of

all masticatory muscles in a coordinated manner. Temporomandibular joint capsule and ligaments have an influence on joint motions in a passive manner. The evaluation of ROM values for the TMJ are important in the diagnostic and therapeutic measures of the musculoskeletal and neurological diseases affecting joint movement. We conclude that interincisal distance measurements may be a practical method for the evaluation of the derangements in this joint.

REFERENCES

1. Komiyama O, Asano T, Suzuki H, Kawara M, Wada M, Kobayashi K, et al. Mandibular condyle movement during mastication of foods. *J Oral Rehabil* 2003;30:592-600.
2. Aksoy C. Temporomandibular ağrı ve disfonksiyon. In: Beyazova M, Gökçe Y, editörler. Fiziksel tıp ve rehabilitasyon. Ankara: Güneş Kitabevi; 2000. s. 1391-425.
3. Yılmaz A, Mesut R. Temporomandibüler eklem hareketlerinin inklinometre ile değerlendirilmesi. *Trakya Univ Tıp Fak Derg* 2005;22:27-31.
4. Soames RW. Skeletal system. In: Williams PL, editor. *Gray's anatomy*. 38th ed. New York: Churchill Livingstone; 1995. p. 495-504.
5. Snell RS, editor. *Clinical anatomy for medical students*. 4th ed. Boston: Little, Brown and Company; 1992.
6. Bermejo-Fenoll A, Panchón-Ruíz A, González-González JM, González Sequeros O. A study of the movements of the human temporomandibular joint complex in the cadaver. *Cranio* 2002;20:181-91.
7. Kang QS, Updike DP, Salathe EP. Kinematic analysis of the human temporomandibular joint. *Ann Biomed Eng* 1993;21:699-707.
8. Akhter R, Hassan NM, Nameki H, Nakamura K, Honda O, Morita M. Association of dietary habits with symptoms of temporomandibular disorders in Bangladeshi adolescents. *J Oral Rehabil* 2004;31:746-53.
9. Bailey JO Jr, McCall WD Jr, Ash MM Jr. Electromyographic silent periods and jaw motion parameters: quantitative measures of temporomandibular joint dysfunction. *J Dent Res* 1977;56:249-53.
10. Chirani RA, Jacq JJ, Meriot P, Roux C. Temporomandibular joint: a methodology of magnetic resonance imaging 3-D reconstruction. *Oral Surg Oral Med Oral Pathol Oral Radiol Endod* 2004; 97:756-61.
11. Braun S, Hicken JS. Ultrasound imaging of condylar motion: a preliminary report. *Angle Orthod* 2000; 70:383-6.
12. Kim K, Kim HS, Kim YK, Chung SC. A study on the rotational torque movement of mandible in patients with TMJ closed lock. *Cranio* 1999;17:189-95.
13. Landes C, Walendzik H, Klein C. Sonography of the temporomandibular joint from 60 examinations and comparison with MRI and axiography. *J Craniomaxillofac Surg* 2000;28:352-61.
14. Dijkstra PU, Kropmans TJ, Stegenga B, de Bont LG. Ratio between vertical and horizontal mandibular range of motion. *J Oral Rehabil* 1998;25:353-7.
15. Hochstedler JL, Allen JD, Follmar MA. Temporomandibular joint range of motion: a ratio of interincisal opening to excursive movement in a healthy population. *Cranio* 1996;14:296-300.
16. Cybex EDI 320 - Inclinator, Handbook. 1988.
17. Naeije M. Measurement of condylar motion: a plea for the use of the condylar kinematic centre. *J Oral Rehabil* 2003;30:225-30.
18. Ferrario VF, Sforza C, Lovecchio N, Mian F. Quantification of translational and gliding components in human temporomandibular joint during mouth opening. *Arch Oral Biol* 2005;50:507-15.
19. Demir A, Güray E. 6-19 yaş grubu Türk çocuklarında temporomandibular eklem disfonksiyonu eğiliminin araştırılması. *C.Ü. Diş Hekimliği Fakültesi Dergisi* 2001;4:89-92.
20. Rivera-Morales WC, Goldman BM, Jackson RS. Simplified technique to measure mandibular range of motion. *J Prosthet Dent* 1996;75:56-9.