



Non-coronary Aortic Cusp Rupture in a Child with Ventricular Septal Defect and Aortic Valve Prolapse

Betül Çınar^{ID}, Fatma Sevinç Şengül^{ID}, Pelin Ayyıldız^{ID}, Alper Güzeltaş^{ID}, Sertaç Haydin^{ID}

Clinic of Pediatric Cardiology, University of Health Sciences Turkey, İstanbul Mehmet Akif Ersoy Thoracic and Cardiovascular Surgery Center and Research Hospital, İstanbul, Turkey

A 12-year-old female patient with a large ventricular septal defect (VSD), aortic valve prolapse, and aortic regurgitation was referred to our clinic. She was asymptomatic at admission, which is why her parents delayed follow-up. Her weight and height percentiles were below the normal range (-4 SDS for weight and -3.5 SDS for height). She had a loud, continuous murmur on anterior chest wall auscultation with a blood pressure of 110/44 mmHg and a heart rate of 100 bpm. The electrocardiogram (ECG) depicted no significant changes, and the chest X-ray revealed mild lung congestion and cardiomegaly. Transthoracic echocardiography showed dilated left heart chambers with a sub-arterial VSD of 10 mm complicated by

a ruptured aortic noncoronary cusp connecting to the right ventricle (Videos 1-3). The ventricular systolic functions were preserved. After detailing the anatomy with transesophageal echocardiography (Videos 4, 5), the VSD and aneurysm rupture were surgically repaired (Video 6). The postoperative course was uneventful. Aortic cusp rupture is rarely encountered in the pediatric population. We suggest that this rare pathology can concomitantly exist with additional congenital cardiac defects that may be the underlying causes of hemodynamic changes due to the Venturi effect on the aortic valve. Physical examination and continuous murmur detection are crucial, as patients may present without significant symptoms or

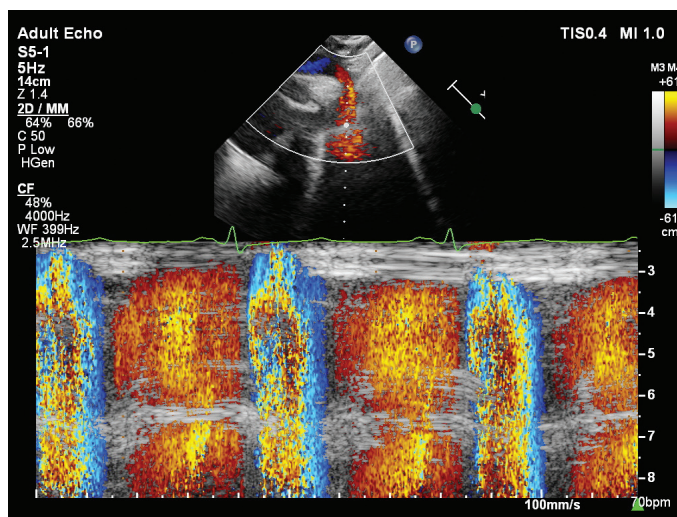


FIG. 1. Holodiastolic flow reversal seen in the proximal descending thoracic aorta by colour M-mode (coloured in red).

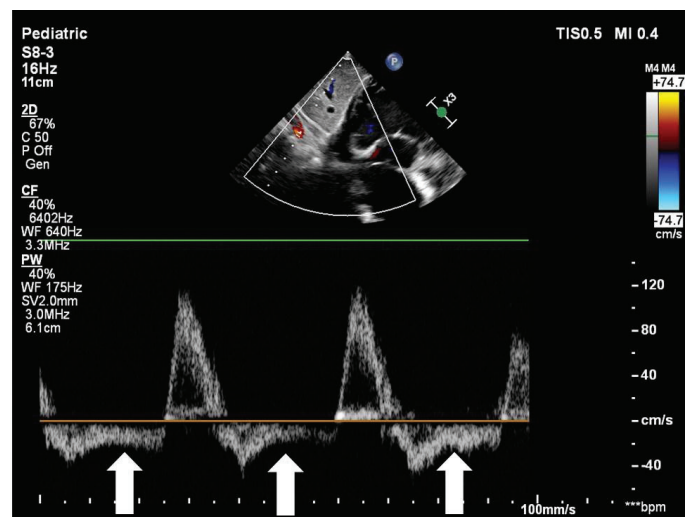


FIG. 2. Pulsed-wave Doppler image of the abdominal aorta showing obvious holodiastolic flow reversal/run-off phenomenon (white arrows).



Corresponding author: Betül Çınar, Clinic of Pediatric Cardiology, University of Health Sciences Turkey, İstanbul Mehmet Akif Ersoy Thoracic and Cardiovascular Surgery Center and Research Hospital, İstanbul, Turkey
e-mail: cinar_betul@hotmail.com

Received: February 01, 2023 Accepted: March 09, 2023 Available Online Date: May 08, 2023 • DOI: 10.4274/balkanmedj.galenos.2023.2023-1-75

Available at www.balkanmedicaljournal.org

ORCID iDs of the authors: B.Ç. 0000-0001-6795-3824; F.S.Ş. 0000-0001-6791-3777; P.A. 0000-0002-1811-3658; A.G. 0000-0003-1924-9036; S.H. 0000-0003-4198-212X.

Cite this article as:

Çınar B, Şengül FS, Ayyıldız P, Güzeltaş A, Haydin S. Non-coronary Aortic Cusp Rupture in a Child with Ventricular Septal Defect and Aortic Valve Prolapse. *Balkan Med J*; 2023; 40(3):224-5.

Copyright@Author(s) - Available online at <http://balkanmedicaljournal.org/>

ECG changes. This pathology may go unnoticed in the presence of VSD as color flow. Doppler images may merge. Therefore, detailed echo screening is essential for achieving the diagnosis.

Informed Consent: Informed consent was obtained from the patient's parents.

Authorship Contributions: Concept- B.Ç., F.S.Ş., P.A., A.G., S.H.; Design- B.Ç.; Supervision-- F.S.Ş., P.A., A.G., S.H.; Data Collection or Processing- B.Ç., P.A.; Literature Search- F.S.Ş.; Writing- B.Ç.; Critical Review- F.S.Ş., P.A., A.G., S.H.

Conflict of Interest: No conflict of interest was declared by the authors.



Video 1. Transthoracic apical four-chamber view demonstrating severe dilation of the left-sided cardiac chambers.

10.4274/balkanmedj.galenos.2023.2023-1-75.video1



Video 2. Two-dimensional transthoracic echocardiography in parasternal short axis demonstrating prolapsus of aortic non-coronary cusp into the right ventricle.

10.4274/balkanmedj.galenos.2023.2023-1-75.video2



Video 3. Transthoracic short axis with colour compare view demonstrating non-coronary aortic cusp prolapse into the right ventricle through the VSD and related shunt across the rupture of the cusp.

10.4274/balkanmedj.galenos.2023.2023-1-75.video3



Video 4, 5. Midesophageal long axis view demonstrates non-coronary aortic cusp prolapse into the VSD, resulting in a voluminous aneurysm of the leaflet in the right ventricle (Video 4). Colour Doppler shows turbulent jet passing through both VSD and ruptured cusp at different times during the cardiac cycle.

10.4274/balkanmedj.galenos.2023.2023-1-75.video4

10.4274/balkanmedj.galenos.2023.2023-1-75.video5



Video 6. Intraoperative demonstration of “wind-sock” like deformity and consequential rupture of the aortic non-coronary cusp through aortotomy.

10.4274/balkanmedj.galenos.2023.2023-1-75.video6