



# Role of Fetal Blood Sampling in the Prenatal Diagnosis of Thalassemia

Xing-Mei Xie<sup>1</sup>, Dong-Zhi Li<sup>1</sup>

Prenatal Diagnostic Center, Guangzhou Women and Children's Medical Center, Guangzhou, China

To the Editor,

Thalassemias and hemoglobinopathies pose a serious health concern in Turkey. To address this issue, a national hemoglobinopathy prevention program focusing on premarital screening and prenatal diagnosis was initiated in the provinces with high prevalence since 2000s.<sup>1</sup> Recently, Yenilmez et al.<sup>2</sup> used fetal blood testing as the diagnostic method to report their findings in prenatal diagnosis. They retrospectively evaluated the hematological parameters in 129 fetuses aged 17-25 weeks of gestation with  $\alpha$ -thalassemia,  $\beta$ -thalassemia, or a normal genotype. The authors concluded that the hematological data provided valuable information to clinicians about the fetus, helping families make informed decisions during prenatal diagnosis.

Their study was performed between 2010 and 2020. Had fetal blood sampling been the main invasive approach during that period? Otherwise, what proportion did it account for in the total number of prenatal diagnoses? Indeed, cordocentesis used to be the only approach for fetal thalassemia diagnosis, as per our center's experience, in the 1990s, before the emergence of DNA diagnosis.<sup>3</sup> Fetal blood was analyzed using hemoglobin electrophoresis to determine the levels of HbA or Hb Bart's for the diagnosis  $\beta$ -thalassemia and  $\alpha$ -thalassemia, respectively. However, since the 2000s, reliable molecular assays for rapid thalassemia genotyping have been developed and made commercially available. Therefore, cordocentesis has been seldom preferred as a method for the diagnosis of thalassemia. For instance, at our center, out of 1,568 fetal diagnoses for thalassemia performed between 2020 and 2022, only 50 were via cordocentesis (Figure 1). Furthermore, all cordocentesis procedures were conducted in fetuses exhibiting sonographic signs indicative of homozygous  $\alpha$ -thalassemia (Bart's disease). Dündar Yenilmez and Tuli<sup>2</sup> performed molecular diagnosis in all fetal blood samples. Given the relatively high procedure-related complications

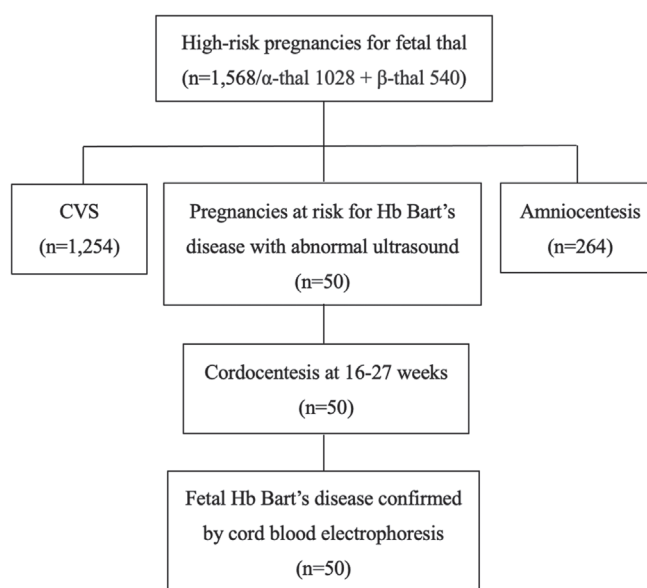


FIG. 1. Flowchart showing the invasive procedures performed in the Prenatal Diagnosis Unit of Guangzhou Women and Children's Medical Center between 2020 and 2022 along with the indication for cordocentesis. CVS, chorionic villus sampling; Hb, hemoglobin; thal, thalassemia.

for cordocentesis, it is unclear why these cases were not offered amniocentesis with amplification refractory mutation system and multiplex PCR.

Upon comparison of the hematological parameters among fetuses with different  $\beta$ -thalassemia genotypes, the authors reported a hemoglobin level of  $5.8 \pm 1.5$  g/dl for  $\beta^0/\beta^0$  fetuses compared with



Corresponding author: Dong-Zhi Li, Prenatal Diagnostic Center, Guangzhou Women and Children's Medical Center, Guangzhou, China  
e-mail: 540539135@qq.com

Received: May 29, 2023 Accepted: June 16, 2023 Available Online Date: September 07, 2023 • DOI: 10.4274/balkanmedj.galenos.2023.2023-5-92

Available at [www.balkanmedicaljournal.org](http://www.balkanmedicaljournal.org)

ORCID iDs of the authors: X-M.X. 0009-0004-2411-5010; D-Z.L. 0000-0002-4583-6800.

Cite this article as:

Xie X-M, Li DZ. Role of Fetal Blood Sampling in the Prenatal Diagnosis of Thalassemia. *Balkan Med J.*; 2023; 40(5):380-1.

Copyright@Author(s) - Available online at <http://balkanmedicaljournal.org/>

the level of  $11.7 \pm 0.6$  g/dl for normal fetuses. Although we have no evidence of hematological parameters for individuals before birth, we believe a  $\beta^0/\beta^0$  fetus would have a comparable hemoglobin value to that of a normal fetus because a fetus with such a low hemoglobin level would have presented with hydropic features at mid gestation.<sup>4</sup> Unlike the  $\alpha$  globin gene, the  $\beta$  globin gene remains silenced throughout prenatal life. Consequently, defects in the two  $\beta$  genes do not have a hematological effect on fetuses because HbF ( $\alpha_2\gamma_2$ ) constitutes the major hemoglobin during fetal life, which is gradually replaced by adult hemoglobin (HbA,  $\alpha_2\beta_2$ ) during infancy.<sup>5</sup> This is supported by the finding that HbF (%) was  $80.4 \pm 6.1$  and  $80.6 \pm 3.5$  in  $\beta^0/\beta^0$  fetuses and normal fetuses, respectively.

Despite our concerns regarding the results of their study, we agree with Dündar Yenilmez and Tuli<sup>2</sup> that fetal blood analysis is an option for fetal genetic diagnosis. However, in this molecular era, the emergence of novel, effective laboratory techniques has considerably decreased the need for fetal blood sampling for genetic diagnostic purposes, even during later pregnancy.

**Authorship Contributions:** Design- D-Z.L.; Data Collection and Processing- X-M.X.; Analysis or Interpretation- D-Z.L.; Writing- X-M.X.

**Conflict of Interest:** No conflict of interest was declared by the authors.

## REFERENCES

1. Canatan D. Thalassemias and hemoglobinopathies in Turkey. *Hemoglobin*. 2014;38:305-307. [\[CrossRef\]](#)
2. Dündar Yenilmez E, Tuli A. Cord Blood Hematological Parameters of Fetuses Detected Different Thalassemia Genotypes in the Second Trimester of Pregnancy. *Balkan Med J*. 2023;40:279-286. [\[CrossRef\]](#)
3. Liao C, Wei J, Li Q, Li L, Li J, Li D. Efficacy and safety of cordocentesis for prenatal diagnosis. *Int J Gynaecol Obstet*. 2006;93:13-17. [\[CrossRef\]](#)
4. Mari G, Deter RL, Carpenter RL, et al. Noninvasive diagnosis by Doppler ultrasonography of fetal anemia due to maternal red-cell alloimmunization. Collaborative Group for Doppler Assessment of the Blood Velocity in Anemic Fetuses. *N Engl J Med*. 2000;342:9-14. [\[CrossRef\]](#)
5. Stamatoyannopoulos G. Control of globin gene expression during development and erythroid differentiation. *Exp Hematol*. 2005;33:259-271. [\[CrossRef\]](#)