



A Novel Modified Mini-Crush Technique for Complex Coronary Bifurcation Lesions: Controlled Balloon-Crush

● Fatih Uzun[#], ● Ahmet Güner[#], ● Ahmet Yaşar Çizgici, ● Koray Çiloğlu, ● İbrahim Faruk Aktürk

Department of Cardiology, Mehmet Akif Ersoy Thoracic and Cardiovascular Surgery Training and Research Hospital, İstanbul, Türkiye

[#]These authors contributed equally.

A 58-year-old male presented to our emergency department with signs and symptoms of non-ST-elevation myocardial infarction. The patient underwent invasive coronary angiography, which revealed a non-left main bifurcation disease, involving the left anterior descending (LAD) and first diagonal (D1) arteries, as well as critical stenosis of the left circumflex artery (Figure 1a, Supplementary Video 1). After passing the proximal LAD artery lesion with a guidewire, intravascular ultrasound (IVUS) revealed severe calcification in the LAD artery (Figure 1b). Although the D1 artery was successfully

predilated (Figure 1c), the LAD artery was not optimally predilated (Figure 1d). Thereafter, the lesion was successfully prepared using the wire-cutting technique (Figure 1e, Supplementary Video 2), and a 2.5 × 31 mm drug-eluting stent [(DES); Firehawk, MicroPort Scientific Inc., Shanghai, China] was implanted from the D1 artery to the LAD artery with minimal protrusion (1-2 mm) (Figure 1f, Supplementary Video 3). The proximal side-branch optimization technique was applied by gently retracting the D1 stent balloon (Figure 2a), and kissing balloon inflation (KBI) was performed (Figure 2b,

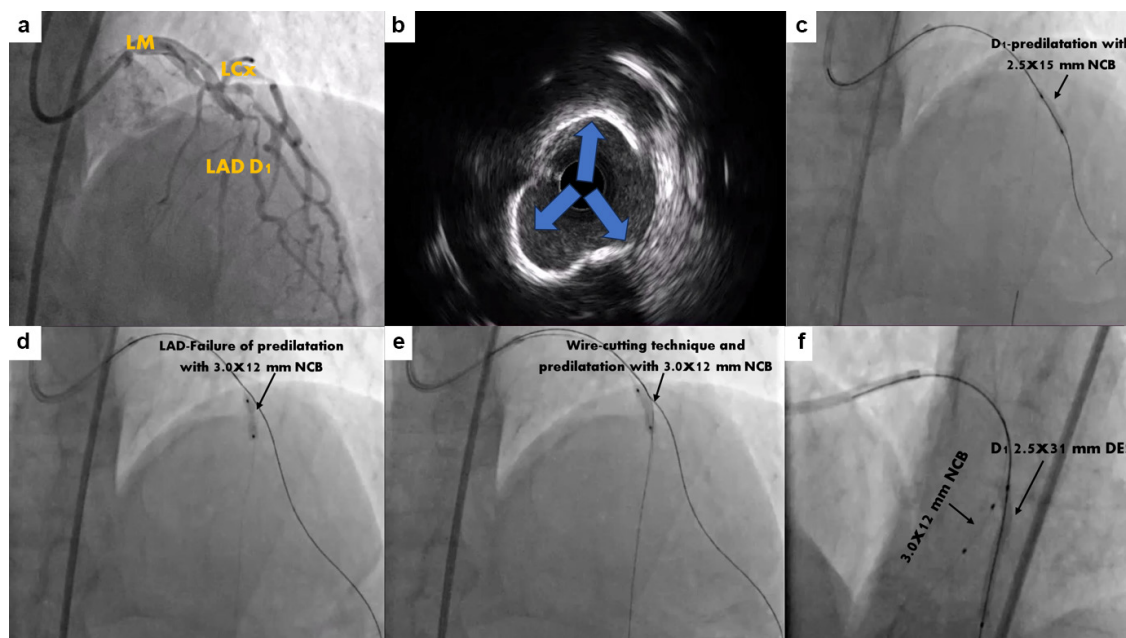


FIG. 1. (a) Critical stenosis of the LAD-D1 bifurcation. (b) IVUS showing severe calcification in the LAD artery. (c-e) Wiring and predilatation of the LAD and D1 arteries. (f) Implantation of a 2.5 × 31 mm DES in the D1 artery using the minicrush approach.

DES, drug-eluting stent; D1, first diagonal artery; IVUS, intravascular ultrasound; LAD, left anterior descending artery; LCx, left circumflex artery; LM, left main coronary artery; NCB, non-compliant balloon.



Corresponding author: Ahmet Güner, Department of Cardiology, Mehmet Akif Ersoy Thoracic and Cardiovascular Surgery Training and Research Hospital, İstanbul, Türkiye

e-mail: ahmetguner488@gmail.com

Received: November 25, 2024 **Accepted:** November 29, 2024 **Available Online Date:** May 05, 2025 • **DOI:** 10.4274/balkanmedj.galenos.2024.2024-11-80

Available at www.balkanmedicaljournal.org

ORCID iDs of the authors: F.U. 0000-0001-9252-735X; A.G. 0000-0001-6517-7278; A.Y.Ç. 0000-0002-3579-2306; K.Ç. 0000-0003-2501-2289; İ.F.A. 0009-0009-1296-9752.

Cite this article as: Uzun F, Güner A, Çizgici AY, Çiloğlu K, Aktürk İF A Novel Modified Mini-Crush Technique for Complex Coronary Bifurcation Lesions: Controlled Balloon-Crush. *Balkan Med J.*; 2025; 42(3):266-8.

Copyright©Author(s) - Available online at <http://balkanmedicaljournal.org/>

Supplementary Video 4). Thereafter, the D1 stent balloon was slowly deflated, and the D1 stent was crushed in a controlled manner (Figure 2c, Supplementary Video 5). Optimal crushing and coverage of the D1 stent were confirmed via IVUS (Figure 2d, Supplementary Video 6, 7) and ClearStent (Siemens, Germany) (Figure 2e). For the LAD artery lesion, a 3.0×38 mm DES was implanted at 12 atm (Figure 2f). The proximal optimization technique (POT) was performed (Figure 3a, b), and after rewiring, the 1.5×20 mm semi-compliant balloon

was easily advanced into the D1 artery (Supplementary Video 8). After the final KBI and re-POT (Figure 3c, d), the stent position was assessed using ClearStent and IVUS. The stent apposition was found to be optimal (Figure 3e, f, Supplementary Video 9). Thus, the procedure was completed (Figure 3g, Supplementary Video 10, 11). The same technique was successfully performed in two other patients (Supplementary Figure 1, 2).

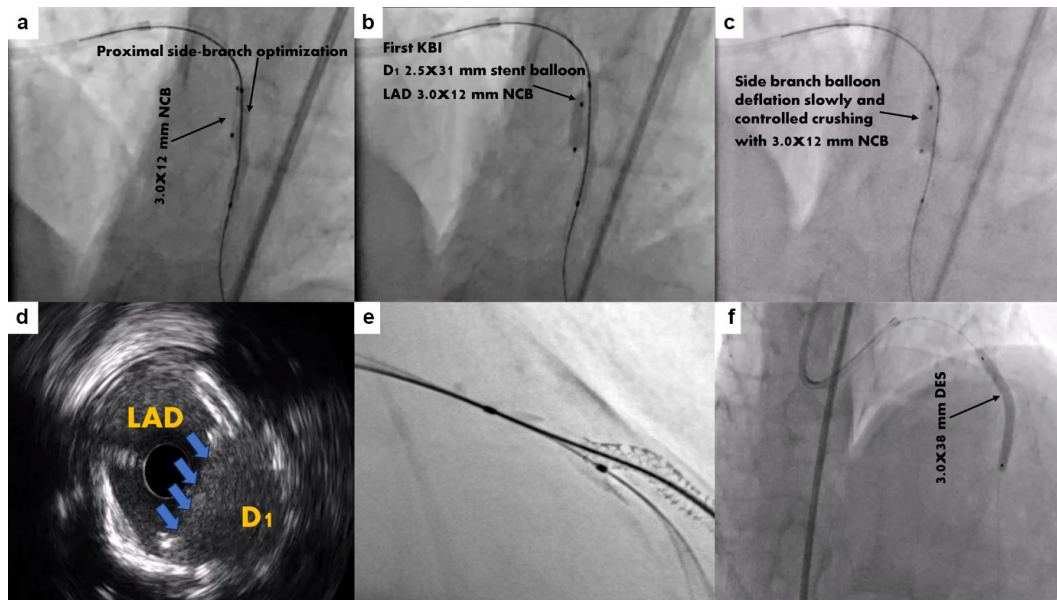


FIG. 2. (a) Proximal side-branch optimization technique for balloon stenting. (b) Kissing balloon inflation (D1: stent balloon, LAD: 3.0×12 mm NCB). (c) The D1 stent balloon was slowly deflated, and the D1 stent was crushed in a controlled manner. (d, e) IVUS and ClearStent images showing optimal coverage of the D1 artery and appropriate crushing of the D1 stent. (f) A 3.0×38 mm DES was implanted in the LAD.

DES, drug-eluting stent; D1, first diagonal artery; IVUS, intravascular ultrasound; KBI, kissing balloon inflation; LAD, left anterior descending artery; NCB, non-compliant balloon.

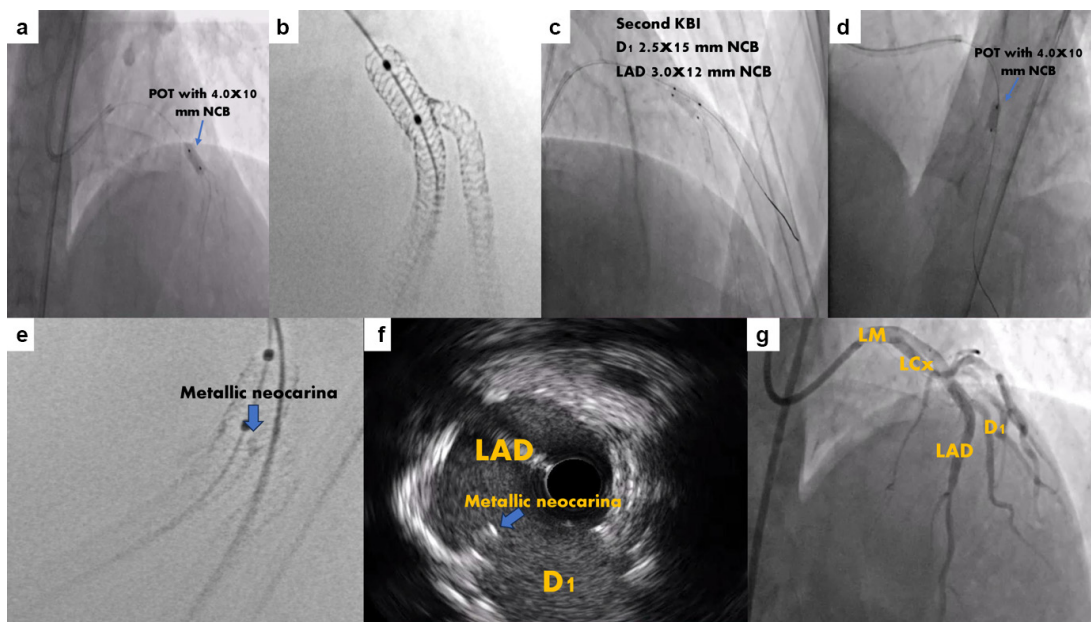


FIG. 3. (a-d) POT, final KBI, and re-POT. (e, f) ClearStent and IVUS images showing adequate stent apposition and metallic neo-carina. (g) Final result. DES, drug-eluting stent; D1, first diagonal artery; IVUS, intravascular ultrasound; KBI, kissing balloon inflation; LAD, left anterior descending artery; LCx, left circumflex artery; LM, left main coronary artery; NCB, non-compliant balloon; POT, proximal optimization technique.

The crush technique is one of the leading double-stent techniques frequently performed by numerous interventional cardiologists for treating complex bifurcation lesions.¹ It remains popular with several iterations having emerged in the past two decades. However, the most important challenges of the crush techniques are the rewiring and advancement of a side-branch balloon after the main branch stent has been implanted.^{2,3} Therefore, we believe that our novel approach may overcome these disadvantages.

Informed Consent: A detailed written informed consent was obtained from the patient for the publication of this case and images.

Authorship Contributions: Concept- F.U., A.G., A.Y.Ç.; Design- F.U., A.G.; Supervision- F.U.; Materials- A.G.; Data Collection and/or Processing- A.Y.Ç., K.Ç.; Literature Search- F.U., A.G., A.Y.Ç.; Writing- F.U., A.G.; Critical Review- İ.F.A.

Conflict of Interest: No conflict of interest was declared by the authors.

SUPPLEMENTARY FIG 1 AND FIG 2. <https://balkanmedicaljournal.org/uploads/pdf/1SUPLEMENT-FIG.pdf>

REFERENCES

1. Moroni F, Shue-Min Yeh J, Attallah A, et al. Crush techniques for percutaneous coronary intervention of bifurcation lesions. *EuroIntervention*. 2022;18:71-82. [CrossRef]
2. Güner A, Uzun F, Demirci G, et al. Cardiovascular outcomes after mini-crush or double kissing crush stenting techniques for complex bifurcation lesions: the EVOLUTE-CRUSH registry. *Am J Cardiol*. 2023;206:238-246. [CrossRef]
3. Güner A, Uzun F, Çizgici AY, et al. Long-term cardiovascular outcomes after mini-crush or T and minimal protrusion techniques in complex bifurcation lesions: the EVOLUTE-CRUSH III study. *Coron Artery Dis*. 2024;35:641-649. [CrossRef]



SUPPLEMENTARY VIDEO 1. Angiographic image of LAD-D1 bifurcation disease and critical stenosis in the LCx.
LAD, left anterior descending artery; D1, first diagonal artery; LCx, left circumflex artery.



SUPPLEMENTARY VIDEO 2. Wire-cutting technique for a tight calcified lesion in the LAD.
LAD, left anterior descending artery.



SUPPLEMENTARY VIDEO 3. Positioning of D1 stents to protrude 1-2 mm in the LAD.
D1, first diagonal artery; LAD, left anterior descending artery.



SUPPLEMENTARY VIDEO 4. Kissing balloon inflation with D1 stent balloon and 3.0x12 mm NCB.
D1, first diagonal artery; NCB, non-compliant balloon.



SUPPLEMENTARY VIDEO 5. Slowly deflation D1 stent balloon and controlled crushing with 3.0x12 mm NCB.
D1, first diagonal artery; NCB, non-compliant balloon.



SUPPLEMENTARY VIDEOS 6, 7. IVUS record displays optimal coverage and crushing of the D1 stent.
IVUS, intravascular ultrasound; D1, first diagonal artery.



SUPPLEMENTARY VIDEO 8. The fluoroscopy record demonstrates a semi-compliant balloon easily advanced into the D1 stent.
D1, first diagonal artery.



SUPPLEMENTARY VIDEO 9. IVUS record shows metallic neo-carina and optimal coverage of D1 stent.
IVUS, intravascular ultrasound; D1, first diagonal artery.



SUPPLEMENTARY VIDEOS 10, 11. Final angiographic result.