



Rhinoentomophthoromycosis: An Enigma in Itself

Smrithy Sivadas K, Renita Lorina Castelino

Department of Oral Medicine and Radiology, Nitte (Deemed to be University), AB Shetty Memorial Institute of Dental Sciences, Mangalore, Karnataka, India

A patient aged 35 years visited the outpatient department with swelling in the upper lip and nose since 6 years. The swelling had gradually increased in size, resulting in facial disfigurement and social hinderance. The patient had visited another private hospital in 2018 for the swelling. At that time, a biopsy was obtained, and the sample was subjected to histopathological examination. The patient was diagnosed with rhinoentomophthoromycosis. In 2021, crusts were removed from the left inferior turbinate. Extraoral examination revealed a swelling on the nose that had caused an enlargement of the nose mediolaterally and superoinferiorly, resulting in the inferior displacement of the nostrils and flattening of the nasal bridge. Furthermore, obliteration of both nasolabial folds and frontal bossing were observed. Diffuse swelling was also observed on the upper and lower lip, which had caused superior displacement of the philtrum in line with the nostrils. Sagging and drooping of both the right and left commissures were also observed, which had caused eversion of the lower lip. The swelling was woody-hard in consistency, non-tender, and did not exhibit areas of induration (Figure 1a). A lateral cephalogram was obtained, which revealed a baggy soft tissue profile that was created by enlarged soft tissue sagging from the glabella to the menton (Figure 1b). The posteroanterior view of the cephalogram showed no bony pathologies, a normal nasal septum, nasal cavity, and maxillary sinus, and superimposition of the soft tissue over the midline structures (Figure 1c). Magnetic resonance imaging of the face with T1W, T2W, FLAIR, DWI, and postcontrast T1W sequences revealed diffuse hypointense soft tissue thickening in bilateral frontal, nasal, and maxillary regions on the T2 sequences, with no intracranial, intrasinus, or intraorbital extension (Figure 2a, b). Computed tomography of the osteomeatal complex revealed mucosal thickening in the right maxillary and bilateral ethmoid sinus as well as the nasal septum. Furthermore, hypertrophy of the nasal turbinates was observed (Figure 2c).

As the patient was not willing for a repeat biopsy, the diagnosis of rhinoentomophthoromycosis was considered on the basis of

the previous reports. The clinical presentation usually makes the diagnosis unambiguous.

Systemic antifungal therapy (itraconazole, 200 mg) was administered twice a day for 2 months. Subsequently, the patient was referred to the craniofacial department for facial reconstructive surgery for esthetic enhancement. Thereafter, the patient was regularly followed up.

Rhinoentomophthoromycosis (conidiobolomycosis) is a relatively rare, chronic, subcutaneous zygomycosis that is characterized by a painless woody-hard swelling in the rhinofacial region. The condition causes severe facial disfigurement that resembles the facial contours of the hippopotamus. It usually occurs in the tropical rain forests of Africa, South and Central America, and South-East Asia.¹ The condition usually begins in the inferior turbinate and travels via the submucosa to the natural ostia, paranasal sinus, and subcutaneous tissue of the face, ultimately encompassing the upper lip, forehead, and periorbital regions. Although the lesions typically adhere to the

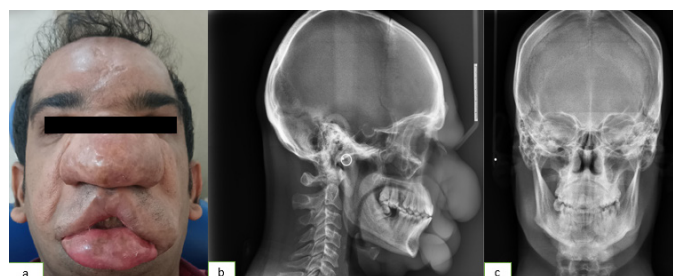

FIG. 1. (a) Swelling seen in the middle one third of face involving the nose, lips and commissures causing facial disfigurement; (b) Lateral cephalogram revealing the soft tissue profile indicating the bagginess created by the enlargement of soft tissues with sagging of the tissues from glabella till menton region; (c) PA Ceph showing soft tissue mass superimposed over the midline structures.



Corresponding author: Renita Lorina Castelino, Department of Oral Medicine and Radiology, Nitte (Deemed to be University), AB Shetty Memorial Institute of Dental Sciences, Mangalore, Karnataka, India

e-mail: renita.castelino@yahoo.com

Received: December 05, 2024 **Accepted:** February 02, 2025 **Available Online Date:** 01.07.2025 • **DOI:** 10.4274/balkanmedj.galenos.2025.2024-12-7

Available at www.balkanmedicaljournal.org

ORCID iDs of the authors: S.S.K. 0009-0001-2676-5349; R.L.C. 0000-0002-8696-549X.

Cite this article as: Sivadas K S, Castelino RL. Rhinoentomophthoromycosis: An Enigma in Itself. *Balkan Med J.*; 2025; 42(4):369-70.

Copyright@Author(s) - Available online at <http://balkanmedicaljournal.org/>

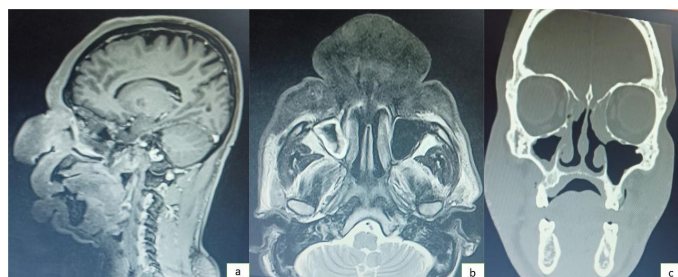


FIG. 2. (a, b) Magnetic resonance imaging of face shows diffuse T2 hypointense soft tissue thickening in frontal, nasal and maxillary regions bilaterally; (c) Computed tomography of the osteo-meatal complex showing mucosal thickening seen in right maxillary and bilateral ethmoid sinus, nasal septum with hypertrophy of nasal turbinates.

underlying tissue, the bone is not compromised, which is consistent with the finding in our patient. Furthermore, the overlying skin remains intact. The disease progresses slowly and is rarely life-threatening.²

Conidiobolus coronatus (*Entomophthora coronata*), a mold of the Entomophthorales order and Zygomycetes class, is the main causative agent of rhinoentomophthoromycosis. Following its initial isolation in 1897, Bras et al.² reported the first human infection with this fungus, which was substantiated with mycologic evidence, in 1965. In warm and damp conditions, the fungus thrives as a saprophyte in soil humus and decomposing plant matter. Additionally, it can parasitize insects and frogs. An infection develops when the fungal spores are inhaled or introduced into the nasal cavity via contaminated hands.³ Patients typically present with stiff and indurated skin and subcutaneous tissues throughout the nasal dorsum, nasolabial area, lips, glabella, and forehead. These lesions may or may not be associated with nasal obstruction. The associated facial deformity gradually advances, resulting in compromised facial esthetics. Systemic dissemination of the condition has been observed in immunocompromised individuals, resulting in the involvement of the orbit and intracranium.^{4,5} The clinical presentation of the infection makes the diagnosis unambiguous, as seen in our case. Nevertheless, histopathological examination of the biopsied tissues reveals fibroblastic growth, persistent granulomatous inflammation, thin-

walled hyphae, and the Splendore-Hoeppli phenomenon, in which the hyphal components are encircled by an eosinophilic sleeve.⁶ The treatment of rhinoentomophthoromycosis may be challenging due to its late diagnosis. However, oral itraconazole (200-400 mg/day), ketoconazole (200-400 mg/day), fluconazole (100-200 mg/day), amphotericin-B, and cotrimoxazole are often effective. Combining azoles and oral potassium iodide (1 gm/ml) ensures immediate and long-lasting results. However, surgical debulking of the lesion could exacerbate the infection. In recent years, cryotherapy has demonstrated moderate success. However, even after successful therapy, recurrence of the condition is common. Furthermore, the facial disfigurement associated with this condition can be addressed via reconstructive surgery.⁷

Informed Consent: Informed consent was obtained from the patient for anonymously publishing their clinical and imaging data.

Authorship Contributions: Concept- S.S.K., R.L.C.; Design- S.S.K., R.L.C.; Supervision- R.L.C.; Data Collection and/or Processing- S.S.K., R.L.C.; Analysis and/or Interpretation- R.L.C.; Literature Review- S.S.K.; Writing- S.S.K.; Critical Review- R.L.C.

Conflict of Interest: No conflict of interest was declared by the authors.

REFERENCES

- Ochoa LF, Duque CS, Velez A. Rhinoentomophthoromycosis. Report of two cases. *J Laryngol Otol*. 1996;110:1154-1156. [\[CrossRef\]](#)
- Bras G, Gordon CC, Emmons CW, Prendegast KM, Sugar M. A case of phycomycosis observed in Jamaica; infection with *entomophthora coronata*. *Am J Trop Med Hyg*. 1965;14:141-145. [\[CrossRef\]](#)
- Richardson MD, Pirkko KK, Gillian SS. Rhizopus, rhizomucor, absidia and other agents of systemic and subcutaneous zygomycoses. In: Patrick RM, Ellen JB, et al., editors. *Manual of Clinical Microbiology*. ASM Press. 2003; p. 1761-1780. [\[CrossRef\]](#)
- Kiatkangwanchon N, Kanjanaumporn J, Wungcharoen P, Meesilpavikkai K, Phuensan P. Conidiobolomycosis: a rare fungal infection in Thailand. *Int J Infect Dis*. 2024;148:107239. [\[CrossRef\]](#)
- Chaiyasate S, Salee P, Sukapan K, Teeranoraseth T, Roongrotwattanasiri K. Rhinofacial entomophthoromycosis case series, the unusual cause of facial swelling. *Ann Med Surg (Lond)*. 2020;57:41-45. [\[CrossRef\]](#)
- Valle AC, Wanke B, Lazéra MS, Monteiro PC, Viegas ML. Entomophthoromycosis by *Conidiobolus coronatus*. Report of a case successfully treated with the combination of itraconazole and fluconazole. *Rev Inst Med Trop Sao Paulo*. 2001;43:233-236. [\[CrossRef\]](#)
- Prabhu RM, Patel R. Mucormycosis and entomophthoromycosis: a review of the clinical manifestations, diagnosis and treatment. *Clin Microbiol Infect*. 2004;10(Suppl1):31-47. [\[CrossRef\]](#)