



# Treatment of Steroid-Resistant Radiation-Induced Cerebral Edema with *Boswellia serrata*

Yusuf Kavuzlu<sup>1</sup>, Serdar Solak<sup>2</sup>, Zafer Koçak<sup>1</sup>

<sup>1</sup>Department of Radiation Oncology, Trakya University Faculty of Medicine, Edirne, Türkiye

<sup>2</sup>Department of Radiology, Trakya University Faculty of Medicine, Edirne, Türkiye

A 57-year-old man presented with a one-week history of visual impairment in the right eye and headaches. His medical history included heavy smoking (approximately 300 pack-years) and liver hemangiomas. Ophthalmological examination revealed no abnormalities, and a brain magnetic resonance imaging (MRI) was recommended.

The initial contrast-enhanced brain MRI revealed two mass lesions in the left cerebral hemisphere: a prominent lesion in the left occipital lobe (30 mm) and a smaller lesion in the frontal lobe (15 mm). Thoracic computed tomography (CT) showed a 20-mm mass in the apicoposterior segment of the upper lobe of the left lung and a subcentimetric hilar lymph node.

Given a possible diagnosis of metastatic lung cancer, fractionated stereotactic radiation therapy (FSRT) using volumetric-modulated arc therapy was planned for the brain lesions. The planned target volume included a 2-mm margin around the gross tumor volume. A single-isocenter treatment plan was generated using Varian Eclipse (Varian Medical Systems, Palo Alto, CA).

The patient received a total dose of 30 Gy (6 Gy per fraction) with Varian TrueBeam 6 MV photons, ensuring that at least 99% of the planning target volume received the full prescription dose. Normal tissue dose constraints were applied as follows: normal brain tissue volume V28 < 7 cc, maximum brainstem dose < 31 Gy, maximum optic nerve/chiasm dose < 25 Gy, and maximum lens dose < 7 Gy.

Positron emission tomography/CT revealed only a mass in the lung, with no additional lesions. Given the patient's good performance status, surgical resection of the lung mass was undertaken. A wedge resection of the left lung with lymph node sampling was performed. Postoperative pathology confirmed acinar adenocarcinoma without lymph node involvement (pT2N0). Molecular analysis showed no expression of PD-L1, EGFR, ALK, or ROS1. The patient subsequently received three cycles of adjuvant carboplatin and paclitaxel.

One year after the diagnosis of brain metastases, new lesions developed in the left frontal gyrus, cingulate gyrus, and temporal lobe. These lesions were treated with FSRT using volumetric-modulated arc therapy, delivering a total dose of 25 Gy in five fractions. The same normal tissue dose constraints described previously were applied. Follow-up MRI showed complete regression of all left cerebral lesions.

Six months later, a new left temporooccipital lesion (Figures 1a, b) was treated again with volumetric-modulated arc therapy, 25 Gy in five fractions. Three months after this treatment, the patient presented with headaches. MRI revealed significant loss of contrast enhancement on axial post-contrast T1-weighted images, while vasogenic edema had slightly progressed on axial fluid-attenuated inversion recovery images (Figures 1c, d). The increase in edema and symptoms was attributed to radiation therapy and classified as grade 2 toxicity according to Common Terminology Criteria for Adverse Events version 5.0.

Dexamethasone was initiated at 12 mg/day. Follow-up imaging demonstrated persistent vasogenic edema despite steroid therapy, while contrast enhancement had resolved (Figures 1e, f). The patient remained steroid-dependent due to recurrent headaches and fatigue upon tapering. Bevacizumab was avoided because of a history of pulmonary embolism.

After reviewing the literature, *Boswellia serrata* was considered. Warnick<sup>1</sup> reported a case series of three patients with refractory radiation-induced cerebral edema or necrosis who responded to 300 mg/day of *Boswellia* extract. *Boswellia* extract [5-Loxin- acetyl-11-keto- $\beta$ -boswellic acid (AKBA)] at 400 mg/day was initiated alongside low-dose steroids. Two months later, MRI demonstrated substantial resolution of vasogenic edema (Figures 1g, h), and the patient's headaches improved. Steroids were subsequently discontinued, and *Boswellia* therapy was continued for an additional two months.

Over the past two decades, advances in radiation delivery techniques have enabled the use of stereotactic radiotherapy to



**Corresponding author:** Zafer Koçak, Department of Radiation Oncology, Trakya University Faculty of Medicine, Edirne, Türkiye

**e-mail:** zaferkocak12@gmail.com

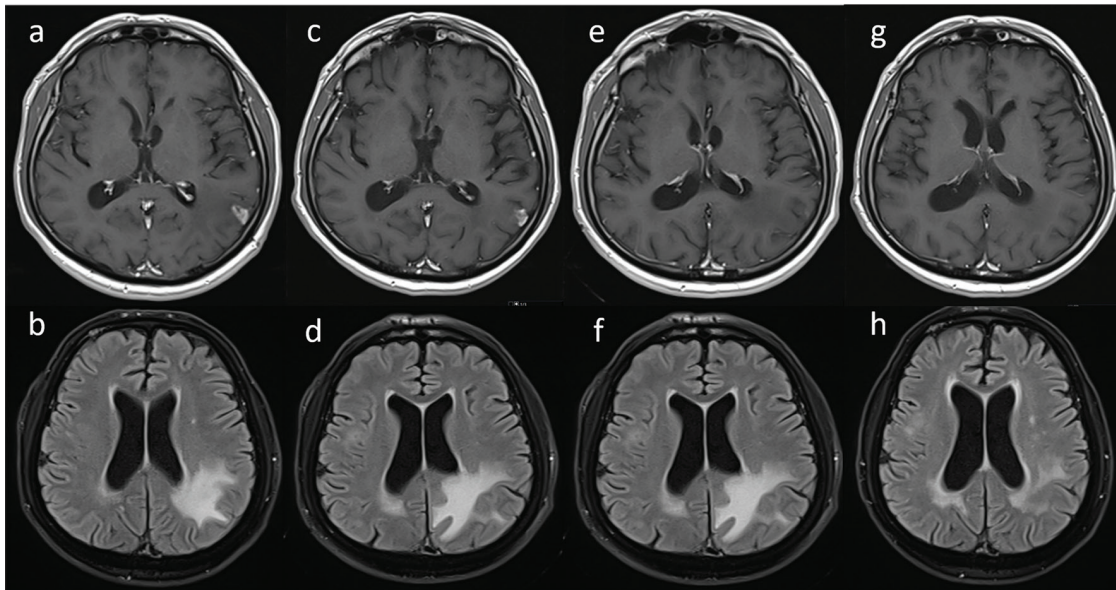
**Received:** November 19, 2025 **Accepted:** December 11, 2025 **Available Online Date:** 30.04.2026 • **DOI:** 10.4274/balkanmedj.galenos.2025.2025-11-168

Available at [www.balkanmedicaljournal.org](http://www.balkanmedicaljournal.org)

**ORCID iDs of the authors:** Y.K. 0000-0003-3651-2510; S.S. 0000-0002-9252-6151; Z.K. 0000-0003-1918-7795.

**Cite this article as:** Kavuzlu Y, Solak S, Koçak Z. Treatment of Steroid-Resistant Radiation-Induced Cerebral Edema with *Boswellia serrata*. *Balkan Med J.* 2026;43:288-290

Copyright© Author(s) - Available online at <http://balkanmedicaljournal.org/>



**FIG. 1.** Imaging findings for steroid-resistant radiation-induced edema and marked improvement in edema with *Boswellia serrata*. In the control magnetic resonance imaging scan 18 months after the diagnosis, axial contrast-enhanced T1 image (a) shows a left temporooccipital metastatic lesion and vasogenic edema around the lesion (b). After fractionated stereotactic radiation therapy, there is a marked loss of contrast enhancement on axial post-contrast T1-weighted images (c), while vasogenic edema is slightly enhanced on axial flair images (d). This edema enhancement is thought to be due to radiation therapy and dexamethasone treatment is initiated. Follow-up images (e, f) shows no contrast enhancement in lesion site while vasogenic edema persists despite steroid therapy. After two months of treatment with *Boswellia serrata*, the resolution of vasogenic edema is seen on axial flair images, while no contrast enhancement is observed on axial post-contrast T1 images (g, h).

deliver higher doses to brain lesions. Consequently, the incidence of radiation-induced brain edema and necrosis has increased. Current treatment options for radiation-induced edema or necrosis include corticosteroids, pentoxifylline with vitamin E, bevacizumab, and surgical resection.<sup>2</sup> Corticosteroids are the first-line therapy; however, their efficacy is sometimes inadequate, and they are associated with significant adverse effects. Moreover, some studies have suggested that corticosteroid use may reduce the efficacy of immunotherapy.<sup>3</sup> Pentoxifylline combined with vitamin E has limited effectiveness due to low response rates. Bevacizumab is an option for steroid-refractory radiation edema or necrosis, with reported clinical and radiographic response rates of 80–90%.<sup>4</sup> However, its high cost, administration challenges, and potential side effects limit widespread use. Surgical resection is generally reserved for select patients due to its invasive nature and risk of complications. These limitations highlight the need for a safe, effective, and easily administered therapeutic agent.

*Boswellia serrata*, commonly known as Indian frankincense, contains the bioactive compound boswellic acid, which exhibits potent anti-inflammatory properties. AKBA, a major active component, is a strong inhibitor of 5-lipoxygenase. AKBA has been proposed as a potential agent for preventing radiation-associated neovascularization and increased vascular permeability.<sup>5</sup>

Streffer et al.<sup>6</sup> provided the first prospective evidence for the use of *Boswellia serrata* in the management of cerebral edema. Twelve patients (11 with glioma and one with brain metastasis) presenting with progressive cerebral edema, either radiotherapy-induced or tumor-related, received 1,200 mg of *Boswellia serrata* three times

daily. Edema was reduced in 2 of 7 patients (29%) with tumor-related edema and in 3 of 5 patients (60%) with treatment-related edema. Corticosteroid doses were reduced or discontinued in one-quarter of the patients. No adverse effects associated with *Boswellia serrata* were reported.

Kirste et al.<sup>7</sup> conducted a placebo-controlled, randomized trial to evaluate the prophylactic effect of *Boswellia serrata* on cerebral edema. A reduction in edema greater than 75% was observed in 60% of patients in the *Boswellia* group, compared with 25% in the placebo group. However, no significant differences in quality of life were noted between the two groups. The largest study investigating *Boswellia serrata* for radiation necrosis was conducted by Upadhyay et al.<sup>8</sup> Patients who developed any degree of radiation necrosis after stereotactic radiosurgery for brain metastases received 4,050–4,500 mg of *Boswellia* daily for at least two months. The median radiation dose was 24 Gy in three fractions. Radiation necrosis was graded as 1, 2, and 3 in 44%, 47%, and 9% of patients, respectively. The overall response rate (complete and partial responses) was 60%. Grade 1 gastrointestinal toxicity occurred in 14% of patients, and grade 2 toxicity in 2%.

A recent systematic review evaluating *Boswellia serrata* for radiation-induced cerebral edema or necrosis reported that approximately half of patients experienced radiographic or clinical improvement, and around one-third were able to reduce or discontinue long-term dexamethasone therapy.<sup>2</sup> The review noted that *Boswellia serrata* was generally well tolerated, with few gastrointestinal adverse effects. However, the authors emphasized that the optimal formulation, timing, and dosage remain unclear, and potential

interactions with other medications require further investigation. In conclusion, *Boswellia serrata* is inexpensive and well tolerated, but clinical evidence remains limited, highlighting the need for well-designed prospective trials.

**Informed Consent:** Written informed consent was obtained from the patient.

**Authorship Contributions:** Concept- Y.K., S.S., Z.K.; Materials- Y.K.; Data Collection or Processing- Y.K.; Literature Review- Y.K.; Writing- Y.K.; Critical Review- Y.K., S.S., Z.K.

**Conflict of Interest:** The authors declare that they have no conflict of interest.

**Peer-Review:** Zafer Koçak is a member of the Editorial Board of the Balkan Medical Journal. However, he was not involved in the editorial decision of the manuscript at any stage.

## REFERENCES

1. Warnick RE. Treatment of adverse radiation effects with *Boswellia serrata* after failure of pentoxifylline and vitamin E: illustrative cases. *J Neurosurg Case Lessons*. 2023;5:CASE22488. [\[CrossRef\]](#)
2. Dejonckheere CS, Scafa D, Käsmann L, et al. *Boswellia serrata* for the management of radiation-induced cerebral edema and necrosis: a systematic meta-narrative review of clinical evidence. *Adv Radiat Oncol*. 2025;10:101732. [\[CrossRef\]](#)
3. Arbour KC, Mezquita L, Long N, et al. Impact of baseline steroids on efficacy of programmed cell death-1 and programmed death-ligand 1 blockade in patients with non-small-cell lung cancer. *J Clin Oncol*. 2018;36:2872-2878. [\[CrossRef\]](#)
4. Levin VA, Bidaut L, Hou P, et al. Randomized double-blind placebo-controlled trial of bevacizumab therapy for radiation necrosis of the central nervous system. *Int J Radiat Oncol Biol Phys*. 2011;79:1487-1495. [\[CrossRef\]](#) Erratum in: *Int J Radiat Oncol Biol Phys*. 2012;84:6. [\[CrossRef\]](#)
5. Lulli M, Cammalleri M, Fornaciari I, Casini G, Dal Monte M. Acetyl-11-keto- $\beta$ -boswellic acid reduces retinal angiogenesis in a mouse model of oxygen-induced retinopathy. *Exp Eye Res*. 2015;135:67-80. [\[CrossRef\]](#)
6. Streffer JR, Bitzer M, Schabet M, Dichgans J, Weller M. Response of radiochemotherapy-associated cerebral edema to a phytotherapeutic agent, H15. *Neurology*. 2001;56:1219-1221. [\[CrossRef\]](#)
7. Kirste S, Treier M, Wehrle SJ, et al. *Boswellia serrata* acts on cerebral edema in patients irradiated for brain tumors: a prospective, randomized, placebo-controlled, double-blind pilot trial. *Cancer*. 2011;117:3788-3795. [\[CrossRef\]](#)
8. Upadhyay R, Elguindy ANM, Salts L, et al. *Boswellia serrata* for cerebral radiation necrosis after radiosurgery for brain metastases. *Int J Radiat Oncol Biol Phys*. 2025;122:1282-1291. [\[CrossRef\]](#)