

Case Report / *Olgu Sunumu*

## Internal Carotid Artery Pseudoaneurysm As a Rare Complication of Labor: a Case Report

*Doğumun Nadir Bir Komplikasyonu Olan İnternal Karotid Arter Psödoanevrizması: Bir Olgu Sunumu*

Sıdıka Deniz MİCOZKADIOĞLU, Cem ÖZER

*Department of Otolaryngology, Medical Faculty of Başkent University, Ankara*

**Submitted / Başvuru tarihi:** 11.09.2008 **Accepted / Kabul tarihi:** 26.10.2008

Pseudoaneurysms of carotid artery are rare. Nearly all aneurysms are acquired and more commonly seen in adults. Internal carotid artery aneurysms (ICA) represent 5.6% of all carotid aneurysms. Labor is a rare cause of ICA aneurysm. Repeated minor hemorrhages from the nose and throat, Horner's syndrome are typical symptoms of a pseudoaneurysm of ICA. A 44-year-old multiparous female presented to our clinic with a complaint of swelling in the neck for one month. The mass in the neck had appeared after her last (11th) labor. Physical examination of the neck revealed a 5x5 cm mass in the left side of the neck. Computed tomography (CT) revealed a pseudoaneurysm originating from the wall of internal carotid artery which was surrounded by a hematoma. The treatment of the pseudoaneurysm of ICA is endovascular intervention or ICA ligation. In our patient endovascular intervention was not successful, therefore ICA was ligated. We report this case because ICA aneurysms are rare, therefore they should be thought in the differential diagnosis of neck masses.

**Key words:** Carotid artery; aneurysm; ligation.

Karotid arter psödoanevrizmaları oldukça nadirdir. Neredeyse tüm anevrizmalar akkizdir ve yetişkinlerde sık olarak görülmektedir. İnternal karotid arter (İKA) anevrizmaları tüm anevrizmaların %5.6'sını oluşturmaktadır. Doğum İKA anevrizmalarının nadir bir sebebidir. İnternal karotid arter anevrizmalarının tipik semptomları burun ve boğazdan mükerrer minör kanamalar, Horner sendromudur. Kırk dört yaşında multipar bayan hasta bir aydır boynunda şişlik şikayeti ile kliniğimize geldi. Boyundaki şişlik son (11.) doğumundan sonra meydana gelmişti. Hastanın fizik muayenesinde boynunun sol tarafında 5x5 cm kitle tespit edildi. Bilgisayarlı tomografisinde İKA duvarından kaynaklanan etrafı hematoma ile çevrili psödoanevrizma görüldü. İnternal karotid arter psödoanevrizmalarının tedavisi endovasküler girişim veya İKA ligasyonudur. Hastamızda endovasküler girişim başarılı olmadığından İKA ligasyonu yapılmıştır. İnternal karotid arter psödoanevrizmasının nadir görülmesi nedeniyle boyun kitlelerinin ayırıcı tanısında düşünülmesi gerektiğinden bu olguyu sunduk.

**Anahtar sözcükler:** Karotid arter; anevrizma; ligasyon.

Pseudoaneurysms of the carotid artery are rarely encountered in clinical practice. They most likely occur secondary to acute neck trauma, and involve the ICA.<sup>[1]</sup> Internal carotid artery aneurysms are rare representing

5.6% of all carotid aneurysms. Nearly all aneurysms are acquired and more commonly seen in adults.<sup>[2]</sup>

The traumatic lesion of the ICA presents depending on the wall injury extension. Intimal lesions (incomplete

*Correspondence (İletişim adresi): Dr. Sıdıka Deniz Micozkadioğlu. Başkent Üniversitesi Adana Uygulama ve Araştırma Merkezi, 01110 Seyhan, Adana. Tel: 0322 - 458 68 68 Fax (Faks): 0322 - 459 26 22 e-mail (e-posta): denizmicozkadioglu@yahoo.com*

© Trakya Üniversitesi Tıp Fakültesi Dergisi. Ekin Tıbbi Yayıncılık tarafından basılmıştır. Her hakkı saklıdır.

© Medical Journal of Trakya University. Published by Ekin Medical Publishing. All rights reserved.

wall tear and thrombus) may be seen as thrombosis, stenosis or thromboembolic phenomena. Adventitial lesions can also occlude the blood flow extrinsically. Dissection occurs when an intimal tear permits penetration of blood into the vessel wall with or without formation of a pseudoaneurysm. Transection occurs when complete wall compromising (adventitia, media and intimal) in a partial or complete circumference of the vessel and present as an acute bleeding. In these cases formation of an arteriovenous fistulae (carotidocavernous if occurs inside the cavernous sinus) or a pseudoaneurysm may develop.<sup>[3]</sup>

### CASE REPORT

A 44-year-old multiparaous female presented to our clinic with a complaint of swelling in the neck for one month. The mass in the neck has appeared following her last (11th) labor. Physical examination of the neck revealed a 5x5 cm mass in the left side of the neck. Also hypertension was detected. The complete blood count test revealed anemia.

Computed tomography revealed a pseudoaneurysm originating from the wall of ICA which was surrounded by a hematoma (Fig. 1). Also a thrombus in the left subclavian vein and jugular vein was detected.

After confirming the presence of pseudoaneurysm, catheterization of the patient was performed with the intend to delineate the location of the mass in the neck and to treat it endovascularly, if appropriate. The patient was systemically heparinized and anti-

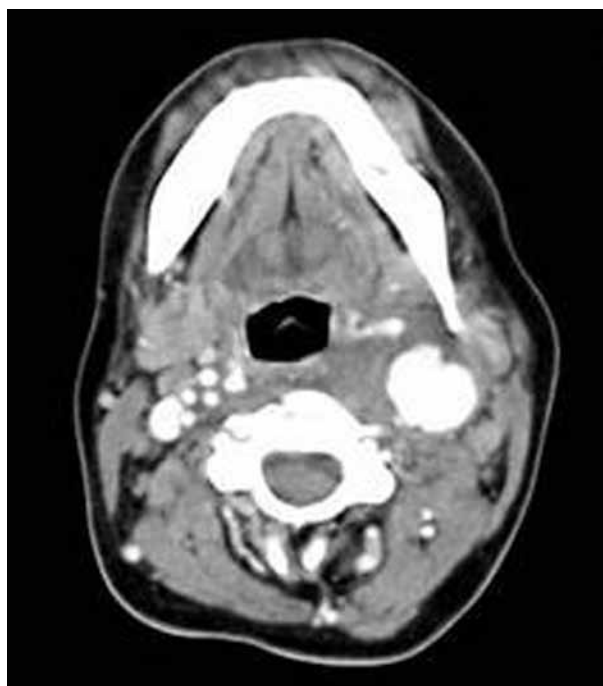


Fig. 1. Computed tomography revealing pseudoaneurysm originating from the wall of left internal carotid artery.

coagulant treatment was applied. There was a pseudoaneurysm 2 cm proximal to the ICA. The endovascular stent placement was planned. But endovascular treatment was not successful because the artery was twisted and stenotic. Therefore ligation of the ICA was planned and the left ICA was ligated without any complication.

### DISCUSSION

Blunt carotid artery injury is an underdiagnosed cause of significant mortality and morbidity with the cervical carotid being the most frequently reported site. This may result in stenosis, occlusion, embolization or a pseudoaneurysm formation. The development of pseudoaneurysm leads to an increased risk of thromboembolic stroke and vessel occlusion.<sup>[4]</sup>

On erosion of an artery either the vessel wall is perforated directly or generally a pseudoaneurysm may form before the rupture of the vessel. Therefore early diagnosis of a pseudoaneurysm of the ICA is very important so that ligation can be done before the fatal rupture. Repeated minor hemorrhages from the nose and throat and Horner's syndrome are typical symptoms of a pseudoaneurysm of the ICA.<sup>[5]</sup> Also dysphagia, respiratory distress and epistaxis were reported.<sup>[2]</sup>

The risk factors for carotid artery pseudoaneurysm are diabetes mellitus, Ehlers-Danlos syndrome type IV, mycotic infection, tonsillitis, pharyngeal abscess, previous radiotherapy to the neck, neck dissection, post-operative staphylococcus aureus infection secondary to accidental pharyngocutaneous fistula, carotid endarterectomy, surgery for malignant carotid body tumor pseudoaneurysm and craniofacial trauma.<sup>[3-8]</sup>

Also in Behçet disease pseudoaneurysms of the arterial system –most commonly aorta and pulmonary artery– may be seen.<sup>[9]</sup>

Carotid injury should be strongly considered if; (i) the patient's neurologic symptoms are not explained by the head CT; (ii) monoparesis, hemiparesis, or Horner syndrome; (iii) cervical soft tissue injury; or (iv) mandibular or basilar skull fractures.<sup>[4]</sup>

Heparin therapy has been shown to be effective in lowering the morbidity and mortality from blunt carotid injury.<sup>[4]</sup> Also our patient underwent anticoagulant treatment.

Definitive diagnosis and treatment is best accomplished with arteriogram and trapping of pseudoaneurysm. Using carotid stent preserves blood flow by restoring the arterial patency and altering the blood flow dynamics resulting in thrombosis and thereby reducing the chance of stroke in young population. Potential complications include embolization, occlusion, stent migration, neointimal proliferation.<sup>[4]</sup> However, the endovascular treatment was not successful in our patient.

Pseudoaneurysms of ICA are rare clinical entities. Therefore they should be considered in the differential diagnosis of neck masses. The treatment of the pseudoaneurysm of ICA is endovascular intervention or ICA ligation.

### REFERENCES

1. Nadig S, Barnwell S, Wax MK. Pseudoaneurysm of the external carotid artery--review of literature. *Head Neck* 2009;31:136-9.
2. Köroglu M, Arat A, Cekirge S, Akpınar E, Eryılmaz A, Akmansu H, et al. Giant cervical internal carotid artery pseudoaneurysm in a child: endovascular treatment. *Neuroradiology* 2002;44:864-7.
3. Zanini MA, Tahara A, Santos GS, Freitas CC, Jory M, Caldas JG, et al. Pseudoaneurysm of the internal carotid artery presenting with massive (recurrent) epistaxes: a life-threatening complication of craniofacial trauma. *Arq Neuropsiquiatr* 2008;66:268-71.
4. Brochu B, Dubois J, Garel L, Quintal MC, Roy D. Complications of ENT infections: pseudoaneurysm of the internal carotid artery. *Pediatr Radiol* 2004;34:417-20.
5. Lim SP, Duddy MJ. Endovascular treatment of a carotid dissecting pseudoaneurysm in a patient with Ehlers-Danlos syndrome type IV with fatal outcome. *Cardiovasc Intervent Radiol* 2008;31:201-4.
6. Masumoto H, Shimamoto M, Yamazaki F, Nakai M, Fujita S, Miura Y. Airway stenosis associated with a mycotic pseudoaneurysm of the common carotid artery. *Gen Thorac Cardiovasc Surg* 2008;56:242-5.
7. Martin ND, Carabasi RA, Bonn J, Lombardi J, DiMuzio P. Endovascular repair of carotid artery aneurysms following carotid endarterectomy. *Ann Vasc Surg* 2005;19:913-6.
8. Ellis PK, Kennedy PT, Barros D'Sa AA. Successful exclusion of a high internal carotid pseudoaneurysm using the Wallgraft endoprosthesis. *Cardiovasc Intervent Radiol* 2002;25:68-9.
9. Yildirim A, Isik A, Sirma N, Gencer V. Subclavian artery pseudoaneurysm in Behcet's disease. *Trakya Univ Tip Fak Derg* 2007;24:60-4.