

Case Report / Olgu Sunumu

Gastric Metastasis of Merkel Cell Carcinoma: Case Report

Midede Merkel Hücreli Karsinom Metastazı: Olgu Sunumu

Peyker TEMİZ, Semin AYHAN, Lerzan ADIGÜZEL,¹ Eray KARA,² Güvenir OKÇU³

Departments of Pathology, ²General Surgery, ³Orthopedics and Traumatology, Medical Faculty of Celal Bayar University;

³Department of Pathology, Akhisar State Hospital, both in Manisa

Submitted / Başvuru tarihi: 28.09.2008 Accepted / Kabul tarihi: 12.11.2008

Merkel cell carcinoma (MCC) of skin is a rare tumor with aggressive behavior. Local recurrences, regional lymph node and distant metastases of MCC are frequent but to date metastasis to upper gastrointestinal tract was reported only a few. We present a 75-year-old man who had primary MCC at his left thigh. The tumor was excised and the patient was directed to local radiotherapy. He had developed abdominal and thoracic subcutaneous metastatic nodules within 5 and 8 months after surgical excision, respectively. In the tenth month, a second operation had to be performed because of a perforated duodenal ulcer and incidentally a submucosal yellow-white nodule measuring 2 cm in diameter was found in the wall of gastric cardia and excised. This lesion was histologically identical to the primary tumor, hence, gastric metastasis of MCC. The patient rejected further therapy and died 17 months after the initial diagnosis. Differential diagnosis of MCC and distinction of gastrointestinal MCC metastasis from primary neuroendocrine tumors may be difficult. Clinical information and histopathological features along with the results of immunohistochemical stainings are very important in this distinction.

Key words: Merkel cell carcinoma; stomach; gastrointestinal; metastasis.

Derinin Merkel hücreli karsinomu (MHK) agresif davranışlı, nadir bir tümördür. Merkel hücreli karsinomun lokal rekürrensleri, bölgesel lenf nodu ve uzak metastazları sık olmakla birlikte bildirilen üst gastrointestinal metastaz oldukça azdır. Yetmiş beş yaşındaki erkek hasta, sol bacağındaki MHK eksize edildikten sonra lokal radyoterapiye yönlendirilmiştir. Tümör eksizyonundan sonraki 5. ayda karında, 8. ayda toraks duvarında subkutan metastatik nodüller gelişmiştir. İlk operasyondan 10 ay sonra perforated duodenal ülser nedeniyle yapılan ikinci operasyon sırasında rastlantısal olarak midede, kardial duvarında farkedilen 2 cm çaplı, sarı-beyaz renkli, submukozal nodül eksize edilmiştir. Bu lezyon MHK'un mide metastazı tanısı almıştır. Hasta daha ileri bir tedaviyi reddetmiş ve başlangıçtaki tanıdan 17 ay sonra yaşamını yitirmiştir. MHK'un ayırıcı tanısı ile gastrointestinal MHK metastazlarının primer nöroendokrin tümörlerden ayrımı zorluk yaratabilir. Bu tür tanı sorunlarının çözümünde klinik bilgi, histopatolojik özellikler ve immunohistokimyasal çalışmalar oldukça önemlidir.

Anahtar sözcükler: Merkel hücreli karsinom; mide; gastrointestinal; metastaz.

Primary neuroendocrine carcinoma of the skin (Merkel cell carcinoma; MCC) is a rare tumor with aggressive behavior which usually localizes on the head and neck region and extremities as a solitary mass.^[1-16] Local

recurrences, as well as regional lymph node and distant metastases of MCC are frequently seen, though, to date upper gastrointestinal metastasis was reported only a few.^[1-35]

Correspondence (İletişim adresi): Dr. Peyker Temiz, Celal Bayar Üniversitesi Tıp Fakültesi Patoloji Anabilim Dalı, 45030 Manisa. Tel: 0236 - 232 58 89 Fax (Faks): 0236 - 237 02 13 e-mail (e-posta): peykerdemireli@gmail.com

© Trakya Üniversitesi Tıp Fakültesi Dergisi. Ekin Tıbbi Yayıncılık tarafından basılmıştır. Her hakkı saklıdır.

© Medical Journal of Trakya University. Published by Ekin Medical Publishing. All rights reserved.

Differential diagnosis of MCC include cutaneous metastasis of small cell carcinoma of the lung, lymphomas, tumors of skin appendages and malignant melanoma. Unusual metastasis to gastrointestinal tract may pose diagnostic problems in that primary neuroendocrine tumors occur more frequently in this region.^[1-32] In order to solve this classical diagnostic problem on small round cell tumors with possible primaries, clinical information and histopathological features are crucial as well as immunohistochemical findings of the tumor.

CASE REPORT

A 75-year-old man complaining of a rapidly growing swelling of 7 cm in diameter at left thigh for about 6 months was admitted to the orthopedics clinic. On small incisional biopsy material, the lesion was diagnosed as "small round cell tumor" with comments stating that a larger biopsy specimen was needed in order to give more specific diagnosis using immunohistochemical studies. On second incisional biopsy which was diagnosed as MCC with the aid of immunohistochemical studies, the patient was undergone total surgical excision.

Excision material was consisted of a pink-purple nodular lesion measuring 7 cm in diameter with an ulcerated center surface (Fig. 1). Microscopic findings revealed a tumoral lesion localized mainly in dermis, extending to the epidermis with solid sheets of cells. Tumor cells was found to have scant eosinophilic cytoplasm, oval or round nucleus without nucleoli (Fig. 2a, b) and a high mitotic rate. Diffuse punctate cytoplasmic staining for CK20, typical for MCC, and diffuse positivity for chromogranin and neuron specific enolase were seen in the tumor cells (Fig. 2c, d). The tumor did not stained with LCA and TTF-1.

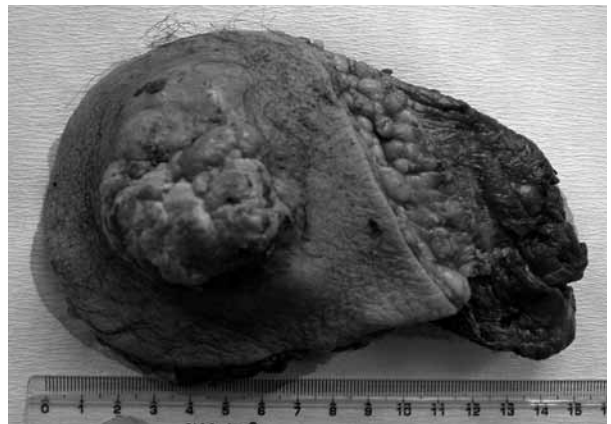

Fig. 1. A pink-purple nodular tumor with ulcerated surface.

With these findings, the diagnosis of MCC was confirmed and patient was directed to local radiotherapy. Unfortunately, he had developed abdominal and thoracic subcutaneous metastatic nodules within 5 and 8 months after surgical excision, respectively. In the 10th month, the patient had had to be operated because of a perforated duodenal ulcer.

During gastrotomy, a submucosal yellow-white nodule measuring 2 cm in diameter was found incidentally in the wall of gastric cardia and excised. No other lesion was observed in the operation site.

Histopathological examination of the nodule had revealed a small round cell tumor consisting of solid sheets and trabeculae continuing in the surgical margins and with a tendency to invade the lamina propria (Fig. 2e, f). Overlying gastric mucosa was otherwise normal.

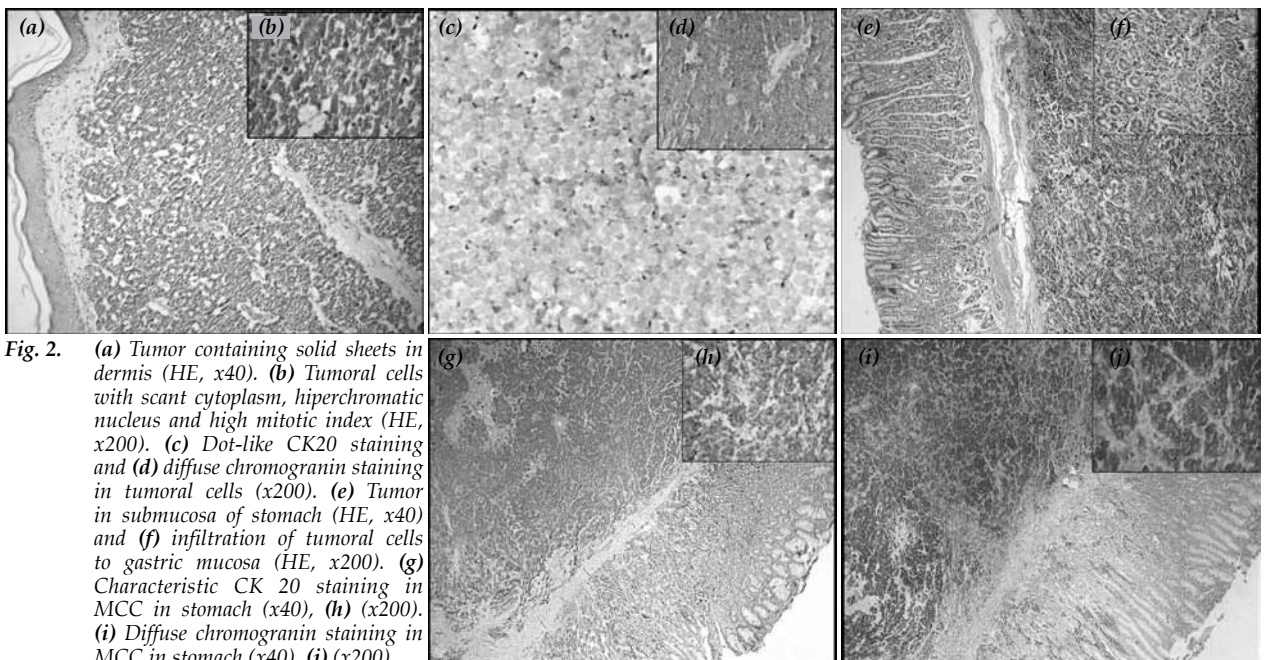


Fig. 2. (a) Tumor containing solid sheets in dermis (HE, x40). (b) Tumoral cells with scant cytoplasm, hyperchromatic nucleus and high mitotic index (HE, x200). (c) Dot-like CK20 staining and (d) diffuse chromogranin staining in tumoral cells (x200). (e) Tumor in submucosa of stomach (HE, x40) and (f) infiltration of tumoral cells to gastric mucosa (HE, x200). (g) Characteristic CK 20 staining in MCC in stomach (x40), (h) (x200). (i) Diffuse chromogranin staining in MCC in stomach (x40), (j) (x200).

As the immuno profile of the tumor cells was found to be identical to those of the excision material (Fig. 2g, h, i, j), the final diagnosis was made as "gastric metastasis of MCC". The patient rejected further therapy and died 17 months after the initial diagnosis.

DISCUSSION

Merkel cell carcinoma (MCC) is a rare primary neuroendocrine tumor of the skin. Its histogenesis is uncertain. It is suggested that this tumor derived from epidermal Merkel cells, dermal neuroendocrine cells or pluripotent epidermal stem cells.^[1,2] Merkel cell carcinoma is thought to be related to sun exposure and UV light irradiation.^[1,2] It was reported that the prevalence of MCC increases in immunosuppressed patients^[1,2,15] and patients with this tumor had increased risk for developing second internal malignancy as well as synchronous or metachronous squamous cell carcinoma.^[1,2]

It mostly occurs mainly in sites exposed to the sun, particularly in head, neck and extremities of fair skinned people in their 6th or 7th decades.^[1-14] Being generally solitary and occasionally multiple, MCC is seen as a pink-purple nodular lesion measuring 0.8-4 cm in diameter.^[1,2] The largest tumor diameter reported is 23 cm.^[16]

Merkel cell carcinoma is an aggressive neoplasm with a high rate of local recurrence (40%), and of regional lymph nodes metastasis (55%), and of distant metastasis (35%).^[1] The most common metastatic sites after regional and retroperitoneal lymph nodes are liver, bone, brain, lungs and skin.^[1,2] Pertaining to gastrointestinal system metastases, it was reported that it involved stomach, duodenum and small intestine and colon.^[17-25]

Intradermal tumor is known to form sheets, trabeculae and pseudorosettes. Tumor cells have scant cytoplasm, round and irregular nuclei tending to form nuclear molding with condensed and uniformly dispersed nuclear chromatin. The nucleoli are usually indistinct. High mitotic activity is considered as a rule.^[1-14] Tumor cells show diffuse cytoplasmic staining with NSE and chromogranin as well as with EMA, Ber-Ep4, CD117 and CD57. Cytoplasmic dot-like staining pattern for CK20 is an characteristic diagnostic feature.^[1,2,9,26-32]

Merkel cell carcinoma may, histopathologically, be confused with metastasis of small cell carcinoma of the lung, lymphomas, tumors of skin appendages and malignant melanoma. Although clinicopathological correlation plays a crucial role in differential diagnosis, immunohistological findings are also valuable.^[1,2,9,26-32] Cytoplasmic dot-like staining pattern for CK20 is said to be very useful in distinguishing metastasis of small cell carcinoma of the lung, non-Hodgkin lymphomas, cutaneous PNET, tumors of skin appendages and malignant melanoma from MCC. In addition, metastatic small cell carcinoma of the lung differs from MCC for being positive with TTF-1^[1,2,17,16,29]; non-Hodgkin lymphomas for

being positive with LCA, L-26 and CD3 and malignant melanoma for being positive for HMB-45 ve S-100^[1,2,9,26-32]

Distinguishing gastrointestinal metastasis of MCC from primary neuroendocrine tumors is said to be difficult. It has been reported that gastrointestinal carcinoid tumors display negative staining for TTF-1 and CK 20. Positivity for CK20 in a tumor with small round cells whose origin is unknown supports the diagnosis of MCC, whereas negativity more specifically rules it out.^[17-25] In our case, as the patient was known to have a primary MCC, CK20 was the first reagent to stain. Therefore, in such cases, the history of patient should carefully be interrogated and CK20 should be added to immunohistochemical panel.

Primary therapy of the MCC is wide resection.^[1,2,33] It is reported that while radiotherapy decreases local recurrence,^[4,6,35] the efficacy of the dissection of regional lymph nodes and chemotherapy is controversial.^[5,34] Since the number of the patients is very few, there is no common approach for the treatment of patients with GIS metastasis. The patients who were reported to have MCC in gastrointestinal system had undergone total gastrectomy, omentectomy, partial intestinal resection with chemotherapy including various drugs such as cytoxan, vincristine, adriamycin, cisplatin, doxorubicin, carboplatin.^[17-25] In our case, only the metastatic nodule at gastric corpus was excised. No further therapy was conducted because of the rejection of the patient.

Metastatic disease at the initial diagnosis, tumor diameter exceeding 2 cm, history of more than three months, the age exceeding 65 years, male gender and trunk localization are suggested to be negative prognostic factors. As for histologic criteria, the depth of the invasion, number of the mitoses, and small size of the tumor cells are regarded to indicate more aggressive behavior.^[1,2,6] In addition to having poor histopathological characteristics, our patient was over 75, and had a 7 cm tumor for six months when he was first diagnosed. As expected, metastatic disease had soon developed and he had not able to survive for more than 17 months.

REFERENCES

1. Brenn T, McKee PH. Tumors of the surface epithelium. In: McKee PH, Calonje E, Granter SR, editors. Pathology of the skin with clinical correlations. 3rd ed. Philadelphia: Elsevier Mosby; 2005. p. 1153-1238.
2. Kohler S, Kerl H. Merkel cell carcinoma. World Health Organization Classification of Tumours. In: LeBoit PE, Burg G, Weedon D, Sarasin A, editors. Pathology and genetics of skin tumours. Lyon: IARC Press; 2006. p. 272-3.
3. Woodworth B, Lacey JP, Amedee RG. Merkel cell carcinoma: an overview and case report. J La State Med Soc 2001;153:522-6.
4. Linjawi A, Jamison WB, Meterissian S. Merkel cell carcinoma: important aspects of diagnosis and management. Am Surg 2001;67:943-7.
5. Coit DG. Merkel cell carcinoma. Ann Surg Oncol 2001;8(9 Suppl):99S-102S.

6. Medina-Franco H, Urist MM, Fiveash J, Heslin MJ, Bland KI, Beenken SW. Multimodality treatment of Merkel cell carcinoma: case series and literature review of 1024 cases. *Ann Surg Oncol* 2001;8:204-8.
7. Tai PT, Yu E, Tonita J, Gilchrist J. Merkel cell carcinoma of the skin. *J Cutan Med Surg* 2000;4:186-95.
8. Snow SN, Larson PO, Hardy S, Bentz M, Madjar D, Landeck A, et al. Merkel cell carcinoma of the skin and mucosa: report of 12 cutaneous cases with 2 cases arising from the nasal mucosa. *Dermatol Surg* 2001;27:165-70.
9. Jensen K, Kohler S, Rouse RV. Cytokeratin staining in Merkel cell carcinoma: an immunohistochemical study of cytokeratins 5/6, 7, 17, and 20. *Appl Immunohistochem Mol Morphol* 2000;8:310-5.
10. Akhtar S, Oza KK, Wright J. Merkel cell carcinoma: report of 10 cases and review of the literature. *J Am Acad Dermatol* 2000;43:755-67.
11. Gollard R, Weber R, Kosty MP, Greenway HT, Massullo V, Humberson C. Merkel cell carcinoma: review of 22 cases with surgical, pathologic, and therapeutic considerations. *Cancer* 2000;88:1842-51.
12. Chang SF, Suh JW, Choi JH, Yoon GS, Huh J, Sung KJ, et al. Diagnostic pitfalls of Merkel cell carcinoma and dramatic response to chemotherapy. *J Dermatol* 1998;25:322-8.
13. Collins BT, Elmberger PG, Tani EM, Bjornhagen V, Ramos RR. Fine-needle aspiration of Merkel cell carcinoma of the skin with cytomorphology and immunocytochemical correlation. *Diagn Cytopathol* 1998;18:251-7.
14. Skelton HG, Smith KJ, Hitchcock CL, McCarthy WF, Lupton GP, Graham JH. Merkel cell carcinoma: analysis of clinical, histologic, and immunohistologic features of 132 cases with relation to survival. *J Am Acad Dermatol* 1997;37:734-9.
15. An KP, Ratner D. Merkel cell carcinoma in the setting of HIV infection. *J Am Acad Dermatol* 2001;45:309-12.
16. Hapcic K, Panchal J, Stewart J, Levine N. Giant Merkel cell carcinoma involving the upper extremity. *Dermatol Surg* 2001;27:493-4.
17. Li M, Liu C. Cytokeratin 20 confirms Merkel cell metastasis to stomach. *Appl Immunohistochem Mol Morphol* 2004;12:346-9.
18. Idowu MO, Contos M, Gill S, Powers C. Merkel cell carcinoma: a report of gastrointestinal metastasis and review of the literature. *Arch Pathol Lab Med* 2003;127:367-9.
19. Canales LI, Parker A, Kadakia S. Upper gastrointestinal bleeding from Merkel cell carcinoma. *Am J Gastroenterol* 1992;87:1464-6.
20. Hizawa K, Kurihara S, Nakamori M, Nakahara T, Matsumoto T, Iida M. An autopsy case of Merkel cell carcinoma presenting aggressive intraabdominal metastasis and duodenal obstruction. *Nippon Shokakibyo Gakkai Zasshi* 2007;104:1383-6.
21. Cubiella J, Salgado M, Riú M, García-Mata J, Sánchez E, Díez MS, et al. Gastric metastasis due to Merkel cell carcinoma: a rare cause of gastric bleeding. *Rev Esp Enferm Dig* 2004;96:150-1. [Abstract]
22. Krasagakis K, Almond-Roesler B, Zouboulis CC, Tebbe B, Wartenberg E, Wolff KD, et al. Merkel cell carcinoma: report of ten cases with emphasis on clinical course, treatment, and in vitro drug sensitivity. *J Am Acad Dermatol* 1997;36:727-32.
23. Naunton Morgan TC, Henderson RG. Small bowel metastases from a Merkel cell tumor. *Br J Radiol* 1985;58:1212-3.
24. Olivero G, Franchello A, Pacchioni D, Enrichens F, Mao P, Benedetto G. A rare case of Merkel's tumor with intestinal metastases. *Ann Ital Chir* 1990;61:277-80. [Abstract]
25. Shalhub S, Clarke L, Morgan MB. Metastatic Merkel cell carcinoma masquerading as colon cancer. *Gastrointest Endosc* 2004;60:856-8.
26. Leech SN, Kolar AJ, Barrett PD, Sinclair SA, Leonard N. Merkel cell carcinoma can be distinguished from metastatic small cell carcinoma using antibodies to cytokeratin 20 and thyroid transcription factor 1. *J Clin Pathol* 2001;54:727-9.
27. Cheuk W, Kwan MY, Suster S, Chan JK. Immunostaining for thyroid transcription factor 1 and cytokeratin 20 aids the distinction of small cell carcinoma from Merkel cell carcinoma, but not pulmonary from extrapulmonary small cell carcinomas. *Arch Pathol Lab Med* 2001;125:228-31.
28. Kontochristopoulos GJ, Stavropoulos PG, Krasagakis K, Goerd S, Zouboulis CC. Differentiation between Merkel cell carcinoma and malignant melanoma: An immunohistochemical study. *Dermatology* 2000;201:123-6.
29. Devoe K, Weidner N. Immunohistochemistry of small round-cell tumors. *Semin Diagn Pathol* 2000;17:216-24.
30. Nicholson SA, McDermott MB, Swanson PE, Wick MR. CD99 and cytokeratin-20 in small-cell and basaloid tumors of the skin. *Appl Immunohistochem Mol Morphol* 2000;8:37-41.
31. Scott MP, Helm KF. Cytokeratin 20: a marker for diagnosing Merkel cell carcinoma. *Am J Dermatopathol* 1999;21:16-20.
32. Schmidt U, Müller U, Metz KA, Leder LD. Cytokeratin and neurofilament protein staining in Merkel cell carcinoma of the small cell type and small cell carcinoma of the lung. *Am J Dermatopathol* 1998;20:346-51.
33. O'Connor WJ, Roenigk RK, Brodland DG. Merkel cell carcinoma. Comparison of Mohs micrographic surgery and wide excision in eighty-six patients. *Dermatol Surg* 1997;23:929-33.
34. Tai PT, Yu E, Winquist E, Hammond A, Stitt L, Tonita J, et al. Chemotherapy in neuroendocrine/Merkel cell carcinoma of the skin: case series and review of 204 cases. *J Clin Oncol* 2000;18:2493-9.
35. Fenig E, Brenner B, Katz A, Rakovsky E, Hana MB, Sulkes A. The role of radiation therapy and chemotherapy in the treatment of Merkel cell carcinoma. *Cancer* 1997;80:881-5.