

Case Report / Olgu Sunumu

Osteoid Osteoma of a Metacarpal Bone: Case Report

Metakarp Yerleşimli Osteoid Osteoma: Olgu Sunumu

Murat BÜLBÜL, Semih AYANOĞLU, Kahraman ÖZTÜRK, Volkan GÜRKAN,¹ Hakan GÜRBÜZ, Bilge BİLGİÇ²

Department of Orthopedics and Traumatology, Vakıf Gureba Training and Research Hospital; ¹Department of Pathology, İstanbul Medical Faculty of İstanbul University; ²Department of Orthopedics and Traumatology, Kartal Training Hospital, all in İstanbul

Submitted / Başvuru tarihi: 16.09.2008 **Accepted / Kabul tarihi:** 20.10.2008

A 16-year-old girl presented to our clinic with a nocturnally aggravating pain on her 5th metacarpal bone for approximately one year, which responded well to salicylate medication. Clinical diagnosis of our case was achieved through anamnesis, physical examination, and imaging studies. In plane X-Ray, increased sclerosis in middle 1/3 of the 5th metacarpal bone extending from cortical area to medulla was observed. MRI revealed an intracortical lesion surrounded by increased sclerotic tissue. History of nocturnally aggravating and salicylate-responding pain made us suspect osteoid osteoma for diagnosis. After curettage of the area we thought as nidus, autografting was performed. After excisional biopsy, histopathological examination confirmed the diagnosis. In our case, we would like to draw attention for the fact that although being a rare localization, osteoid osteoma should be kept in mind in patients with nocturnally aggravating and salicylate-responding pain in metacarpal region, where radiological studies showed an intracortical lesion.

Key words: Osteoid osteoma; metacarpus; hand; benign; bone tumors.

On altı yaşındaki bayan olgumuz beşinci metakarp üzerinde yaklaşık bir senedir geceleri artan, salisilatlara cevap veren ağrı şikayeti ile polikliniğimize başvurdu. Olgumuzda tanıya anamnez, klinik muayene ve görüntüleme yöntemleri ile ulaşıldı. Eksizyonel biyopsi yapılan hastada küretaj sonrasında otoplastik greftleme işlemi yapıldı. Direkt grafide beşinci metakarp 1/3 orta bölümde korteksten medulla içine kadar uzanan skleroz artışı tespit edildi ve sonrasında manyetik rezonans görüntüleme yapıldı. Manyetik rezonans görüntülemeye intrakortikal lezyon varlığı ile etrafındaki sklerotik dokunun artışı ve klinik olarak geceleri artıp, salisilatlara cevap veren ağrının olması ön tanı olarak bizi osteoid osteomaya yöneltti. Nidus olarak tahmin edilen bölgenin küretajı yapıldıktan sonra otoplastik greftleme yapıldı. Eksizyonel biyopsi sonrasında yapılan patolojik değerlendirme sonucu osteoid osteoma olarak tanı kesinleştirildi. Biz bu olgu sunumuzda, metakarpal bölgede intrakortikal bir lezyon varlığında osteoid osteomanın akla getirilmesi gerektiğine dikkat çekmek istedik.

Anahtar sözcükler: Osteoid osteoma; metakarp; el; benign; kemik tümörler.

Osteoid osteoma is a benign bone forming lesion, which was firstly described by Jaffe in 1935.^[1] The lesion is believed to be a localized exaggeration of intramembraneous ossification.^[2,3] They make up approximately 10% of benign bone tumors. Osteoid osteoma, often presenting in second and third decades, was reported to usually

affect long tubular bones.^[4] Osteoid osteoma was reported to be typically a radiolucent lesion developed by intracortical, periosteal, and endosteal bone formation with or without calcification.^[5] Osteoid osteoma is rarely seen at hand and wrist region, which was reported to be 6-13%. The commonly affected bones in the order of

Presented at the 11th Congress of Surgery of the Hand and Upper Extremity, May 16-19, 2008, İzmir, Turkey (11. Ulusal El ve Üst Ekstremitte Cerrahisi Kongresi'nde sunulmuştur, 16-19 Mayıs 2008, İzmir).

Correspondence (İletişim adresi): Dr. Murat Bülbül. Vakıf Gureba Eğitim ve Araştırma Hastanesi Ortopedi ve Travmatoloji Kliniği, 34093 İstanbul. Tel: 0212 - 453 17 00 Fax (Faks): 0212 - 631 75 80 e-mail (e-posta): muratbulbul@yahoo.com

© Trakya Üniversitesi Tıp Fakültesi Dergisi. Ekin Tıbbi Yayıncılık tarafından basılmıştır. Her hakkı saklıdır.

© Medical Journal of Trakya University. Published by Ekin Medical Publishing. All rights reserved.

frequency are phalanges, carpal bones, and metacarpal bones.^[5,6] Establishing the diagnosis affecting this region is very difficult due to lack of any pathognomonic symptoms. Usually, it may be missed or misdiagnosed at initial physical and radiological evaluations. Clinical diagnosis is established via physical examination, direct radiography, and if necessary, computerized tomography, magnetic resonance imaging, and scintigraphy may be utilized. Yet the definitive diagnosis is achieved through histopathological assessment.

In this case presentation, we evaluated osteoid osteoma involving metacarpal.

CASE REPORT

Our 16-year-old case had nocturnally aggravating local tenderness and swelling on her fifth metacarpal bone. In plane X-Ray, increased sclerosis in middle 1/3 of the fifth metacarpal bone extending from cortical area to medulla was observed (Fig. 1). Magnetic resonance imaging showed intracortical lesion with surrounding increased sclerotic tissue (Fig. 2). History of nocturnally aggravating and salicylate-responding pain has made us to suspect osteoid osteoma for diagnosis.

Nidus was completely excised during surgery, but defective area was filled with allograft since the case did not approve for autografting. Histopathological evaluation of the excised material was performed with hematoxylen-eosin staining. Nidus with bone trabeculae surrounded by osteoblastic cells and occasional osteoclasts was observed (Fig. 3). Patient's complaints relieved in the immediate postoperative period and at one-year follow-up, she did not express any complaints.

DISCUSSION

Bilgin et al.^[7] reported rare osteoid osteoma cases involving hand and wrist region to be 0.36% of all bone neoplasia,

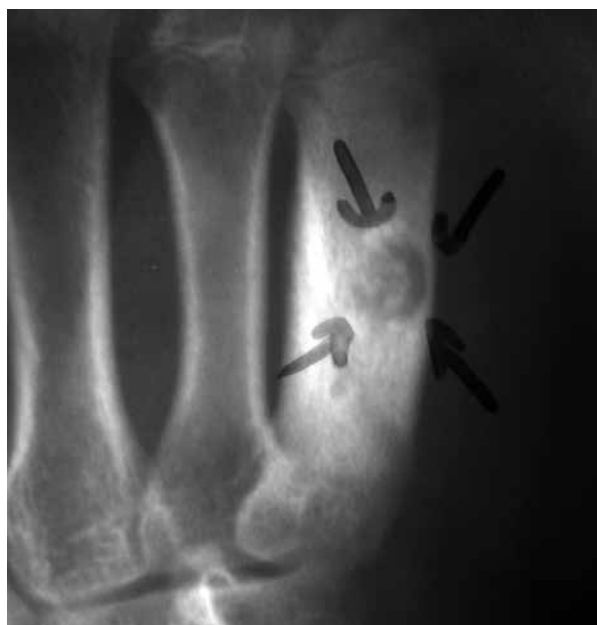

Fig. 1. Plane X-ray of the case.

and 0.49% of all benign bone lesions. Prevalence of osteoid osteoma confined to upper extremity was shown to be 19-31%. Cases involving hand region was reported to be 6-13% and showed following order: phalanges, carpal bones, and metacarpal bones.^[8-10]

Osteoid osteoma in the hand region is very difficult to diagnose, which is mostly characterized by persistent local pain.^[5,11] Diagnosis can generally be established by clinical and radiological findings. Swelling, localized tenderness, and nocturnally aggravating pain contribute to clinical picture. Healey et al.^[12] reported the response rate of salicylates against this pain to be %73. Radiologically described nidus has increased prostaglandin E2 and prostacyclins, which in turn, is

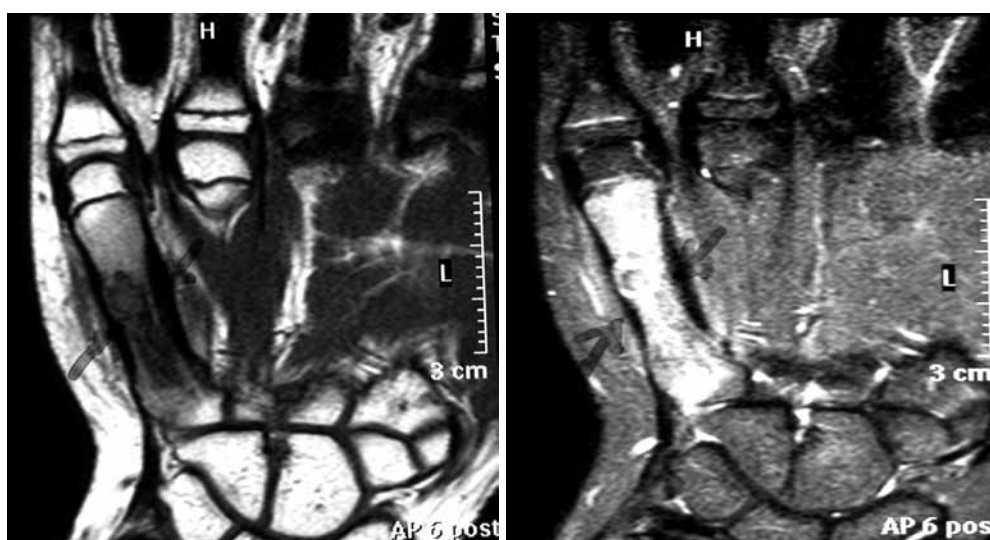


Fig. 2. T1 and T2 sections of magnetic resonance imaging of the case.

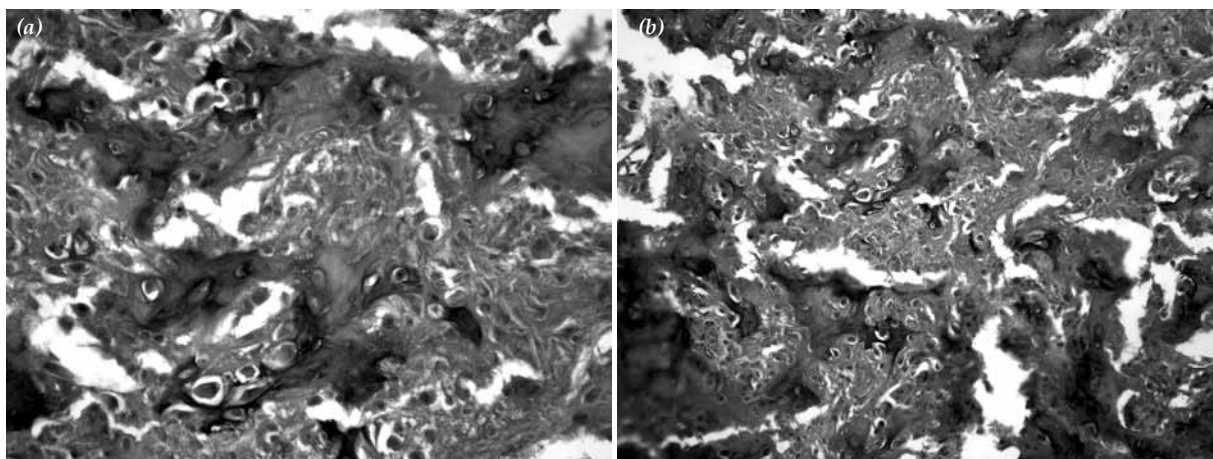


Fig. 3. (a) General appearance of nidus in low magnification – bone trabeculae surrounded by osteoblastic cells with occasional osteoclasts (H-E). (b) A closer appearance of the same area (H-E).

responsible for pain, reactive sclerosis, and inflammatory process. It was revealed that the main metabolites of increased prostacyclins were excreted via urine, which became normal after removal of the nidus.^[13] Although pain is an important symptom in osteoid osteoma cases involving hand and wrist region, it should be remembered that painless cases could also exist.^[16]

Surgical treatment consists of thorough excision of nidus.^[5,11,14,15] We did also observe that complaints immediately disappear after surgical removal of nidus. Follow-up at year 1 exhibited no clinical complaints either.

Anamnesis of soft tissue tenderness, swelling, and pain with radiological findings of increased bone sclerosis and cortical expansion should mainly prompt the diagnosis of stress fracture, Garre's sclerosing osteomyelitis, and intracortical hemangioma.^[8,13,17] In our case, we would like to draw attention for the fact that although being a rare localization, osteoid osteoma should be kept in mind in patients with nocturnally aggravating and salicylate-responding pain in metacarpal region, where radiological evaluation revealed an intracortical lesion.

REFERENCES

- Jaffe HL. Osteoid-Osteoma: a benign osteoblastic tumor composed of osteoid and atypical bone. *Arch Surg* 1935;31:709-28.
- Osteoblastoma-osteoid osteoma. In: Huvos AG. *Bone tumors: diagnosis, treatment and prognosis*. 2nd ed. Philadelphia: Saunders; 1979. p. 67-80.
- Benign tumors and tumorlike conditions. In: Jaffe HL. *Tumors and tumorous conditions of the bones and joints*. Philadelphia: Lea and Febiger; 1958. p. 629.
- Kayser F, Resnick D, Haghighi P, Pereira Edo R, Greenway G, Schweitzer M, et al. Evidence of the subperiosteal origin of osteoid osteomas in tubular bones: analysis by CT and MR imaging. *AJR Am J Roentgenol* 1998;170:609-14.
- Resnick DL, Kyriakos M, Greenway G. Tumors and tumorlike lesions of bone: Imaging and pathology of specific lesions. In: Resnick DL, editor. Philadelphia: Saunders; 1982. p. 144-216.
- Laffosse JM, Tricoire JL, Cantagrel A, Wagner A, Puget J. Osteoid osteoma of the carpal bones. Two case reports. *Joint Bone Spine* 2006;73:560-3.
- Bilgin SS, Yıldız Y, Güçlü B, Sağlık Y. El yerleşimli osteoid osteomlu sekiz olgunun değerlendirilmesi. *Acta Orthop Traumatol Turc* 2004;38:206-11.
- Bednar MS, McCormack RR Jr, Glasser D, Weiland AJ. Osteoid osteoma of the upper extremity. *J Hand Surg [Am]* 1993;18:1019-25.
- Fehring TK, Green NE. Negative radionuclide scan in osteoid osteoma. A case report. *Clin Orthop Relat Res* 1984;(185):245-9.
- Wold LE, McLeod RA, Sim FH, Unni KK, editors. *Atlas of orthopedic pathology*. Philadelphia: Saunders; 1990.
- Carroll RE. Osteoid osteoma in the hand. *J Bone Joint Surg [Am]* 1953;35:888-93.
- Healey JH, Ghelman B. Osteoid osteoma and osteoblastoma. Current concepts and recent advances. *Clin Orthop Relat Res* 1986;(204):76-85.
- Benign osteoblastic tumors. In: Dorfman HD, Czerniak B, editors. *Bone tumors*. 1st ed. St Louis: Mosby; 1998. p. 85-127.
- Norman A. Persistence or recurrence of pain: a sign of surgical failure is osteoid-osteoma. *Clin Orthop Relat Res* 1978;(130):263-6.
- Arazi M, Memik R, Yel M, Oğün TC. Osteoid osteoma of the carpal bones. *Arch Orthop Trauma Surg* 2001;121:119-20.
- Basu S, Basu P, Dowell JK. Painless osteoid osteoma in a metacarpal. *J Hand Surg [Br]* 1999;24:133-4.
- Soler JM, Pizà G, Aliaga F. Special characteristics of osteoid osteoma in the proximal phalanx. *J Hand Surg [Br]* 1997;22:793-7.