



Incidental Glomus Coccygeum in a Surgical Pathology Specimen: A Hidden Clinical Entity

Recep Bedir^{ID}, Nazlıcan Yalçın^{ID}

Department of Pathology, Recep Tayyip Erdogan University Faculty of Medicine, Rize, Turkey

A 38-year-old man exhibiting severe pain in his sacrococcygeal area was admitted to our hospital's general surgery outpatient clinic. He was clinically diagnosed with pilonidal sinus and underwent surgical excision for it. Macroscopic examination of the pathologic specimen revealed no hairy bodies in the sinus tract; however, a 2-mm gray-white lesion was noted in the deeper dermis (Figure 1a). Microscopic examination also revealed a glomus-like tumor consisting of uniform cells with oval-round nuclei around the vessels in a small focus inside a fibrous tissue in the deep dermis (Figure 1b, 1c). Additionally, in immunohistochemical evaluation, these cells were stained negative for desmin and S100 but weak positive for smooth muscle actin (Figure 1d). Considering these findings, the specimen was diagnosed as glomus coccygeum. Written informed consent was obtained from the patient.

Some rare nonpathological structures can be challenging to diagnose visually by surgical pathologists who are unfamiliar with such structures. One of these rare structures is the glomus coccygeum, which is a net of glomus bodies found around the pericoccygeal soft tissues. The glomus coccygeum (also known as glomera coccygea) is a larger normal variant of glomus bodies, which are usually found in the distal extremities.¹

However, whether glomus coccygeum causes coccydinia is debatable. Thus, it should be carefully examined by surgical pathologists because it can be structurally confused with a glomus tumor, which can develop in this region and cause coccydinia.²

The glomus coccygeum is a larger glomus body found at the coccyx. Glomus bodies have three main structures, namely, glomus cells, the vasculature, and smooth muscle cells. Glomus cells are considered modified smooth muscle cells that have centrally located oval-round nucleus with a regular shape. The cytoplasm of these cells may be clear, amphophilic, or eosinophilic. Characteristically, mitosis, necrosis, and atypia do not exist.³

In contrast, a glomus tumor is a mesenchymal neoplasm composed of cells resembling modified smooth muscle cells of the normal glomus body; however, it does not arise from glomus bodies.

Given the bigger size of the glomus coccygeum than a normal glomus body and significant histological resemblance to a glomus tumor, glomus coccygeum may be misdiagnosed as a glomus tumor.³ Therefore, most cases of glomus coccygeum have been reported as glomus tumors.⁴

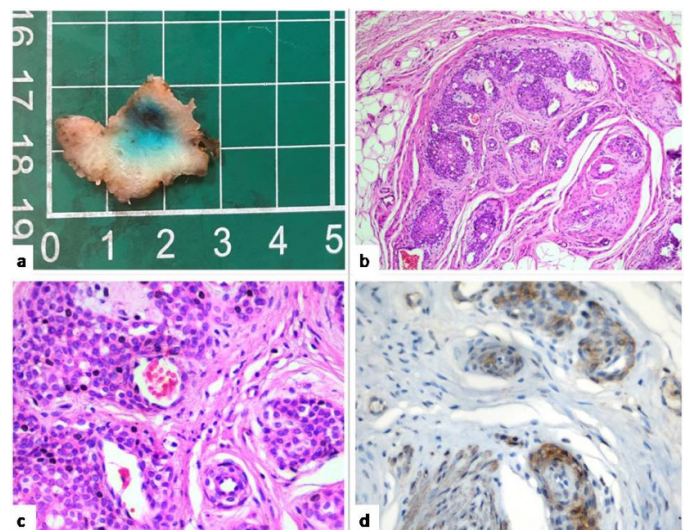


FIG. 1 a) Macroscopic appearance of the lesion, b, c) Monotonous-looking glomus cells with oval-round nuclei that are concentrated around vessels in the deep dermis (hematoxylin and eosin staining x100 and x400), d) Weak positive staining for smooth muscle actin in glomus cells (x400)

Corresponding author: Recep Bedir, Department of Pathology, Recep Tayyip Erdogan University Faculty of Medicine, Rize, Turkey
e-mail: bedirrecep@gmail.com

Received: March 23, 2023 Accepted: May 12, 2023 • DOI: 10.4274/balkanmedj.galenos.2023.2023-3-72

Available at www.balkanmedicaljournal.org

ORCID iDs of the authors: R.B. 0000-0001-8247-3781; N.Y. 0009-0002-3537-614X.

Cite this article as:

Bedir R, Yalçın N. Incidental Glomus Coccygeum in a Surgical Pathology Specimen: A Hidden Clinical Entity. *Balkan Med J.*;

Copyright@Author(s) - Available online at <http://balkanmedicaljournal.org/>

The main significance of glomus coccygeum is that surgical pathologists recognize it as a normal histological finding in this area.³ As a result, pathologists should be aware of this normal structure and avoid diagnosing it as a glomus tumor.

Informed Consent: Written informed consent was obtained from the patient.

Authorship Contributions: Concept- R.B.; Design- R.B.; Data Collection or Processing- N.Y.; Analysis or Interpretation- N.Y.; Writing- R.B.

Conflict of Interest: No conflict of interest was declared by the authors.

Funding: The authors declared that this study received no financial support.

REFERENCES

1. Gatalica Z, Wang L, Lucio ET, Miettinen M. Glomus coccygeum in surgical pathology specimens: small troublemaker. Arch Pathol Lab Med. 1999;123:905-8. [\[CrossRef\]](#)
2. Kim HS, Yang SH, Park HJ, Park HB, Cho HS. Glomus tumor as a cause of coccydynia. Skeletal Radiol. 2013;42:1471-3. [\[CrossRef\]](#)
3. Santos LD, Chow C, Kennerson AR. Glomus coccygeum may mimic glomus tumour. Pathology. 2002;34:339-43. [\[CrossRef\]](#)
4. Albrecht S, Zbieranowski I. Incidental glomus coccygeum. When a normal structure looks like a tumor. Am J Surg Pathol. 1990;14:922-4. [\[CrossRef\]](#)