



Cutaneous Larva Migrans

Paulo Ricardo Martins-Filho¹ , Daniele Machado Reinheimer² , Roberto Fernandes Soares-Neto³ 

¹Federal University of Sergipe, Investigative Pathology Laboratory, Sergipe, Brazil

²Private Practice, Sergipe, Brazil

³Federal University of Sergipe, Residency Program in Dermatology, Sergipe, Brazil

A 42-year-old male patient, resident of Northeast Brazil, presented with a 5-d history of a pruritic eruption on his foot (Figure 1a). Physical examination revealed a 1.5-2-cm long, serpiginous, slightly-elevated, erythematous, raised tract between toes T3 and T4 on the dorsal surface of the left foot (Figure 1b). The patient reported having played volleyball on the beach a few days prior to the onset of the rash. Laboratory tests, including eosinophil count, were within normal limits, indicating no systemic alterations. The patient was clinically diagnosed with cutaneous larva migrans and treated with topical thiabendazole three times a day for 10 days. The lesion healed after 2 weeks.

Cutaneous larva migrans is a prevalent parasitic skin disease, endemic to the tropics and subtropics, and caused by skin contact with soil contaminated with hookworm-containing dog and cat feces.¹ *Ancylostoma caninum*, *Ancylostoma braziliense*, and *Uncinaria stenocephala* are the most common nematodes associated with this zoonotic infection.² The skin manifestations of cutaneous larva migrans include a linear or serpiginous, pruritic larval track, with folliculitis and migratory subcutaneous nodules.³ The distinctive clinical appearance, in addition to a history of exposure to contaminated soil or sand, is sufficient for accurate

diagnosis. Treatment for this condition involves application of topical thiabendazole or administration of oral albendazole.⁴ Prevention efforts for larva migrans focus on avoiding direct contact with contaminated soil⁵ by wearing footwear, in endemic areas, such as Brazil. Additionally, deworming of pets plays a critical role in eradicating the infection. Considering global population mobility, healthcare providers must consider travel history during clinical assessment. Moreover, communities in endemic regions must adopt preventive measures against this zoonosis.

Informed Consent: Written informed consent was obtained from the patient.

Authorship Contributions: Concept- P.R.M.F., D.M.R.; Design- P.R.M.F., D.M.R., R.F.S.N.; Data Collection or Processing- P.R.M.F., R.F.S.N.; Analysis or Interpretation- P.R.M.F., D.M.R., R.F.S.N.; Writing- P.R.M.F., D.M.R.

Conflict of Interest: No conflict of interest was declared by the authors.

Funding: The authors declared that this study received no financial support.

REFERENCES

1. Lesshaft H, Schuster A, Reichert F, Talhari S, Ignatius R, Feldmeier H. Knowledge, attitudes, perceptions, and practices regarding cutaneous larva migrans in deprived communities in Manaus, Brazil. *J Infect Dev Ctries*. 2011;6:422-429. [\[CrossRef\]](#)
2. Hochedez P, Caumes E. Hookworm-Related Cutaneous Larva Migrans. *J Travel Med*. 2007;14:326-333. [\[CrossRef\]](#)
3. Sakai H, Otsubo S, Nakao M, Yamasaki H, Kagei N, Iizuka H. Multiple papules and nodules on the face and neck caused by the larvae of an unknown nematode: A noncreeping type eruption. *J Am Acad Dermatol*. 2008;58:668-670. [\[CrossRef\]](#)
4. Davies HD. Creeping Eruption. *Arch Dermatol*. 1993;129:588. [\[CrossRef\]](#)
5. Tianyi F-L, Agbor VN, Kadia BM, Dimala CA. An unusual case of extensive truncal cutaneous larva migrans in a Cameroonian baby: a case report. *J Med Case Rep*. 2018;12:270. [\[CrossRef\]](#)

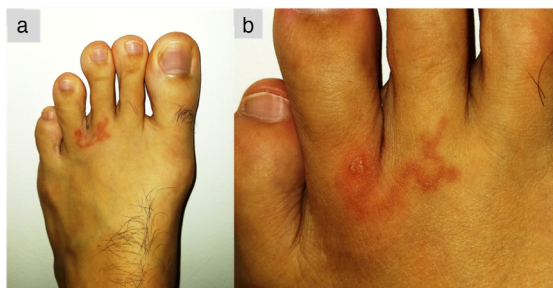


FIG. 1 (a, b). A 1.5-2-cm long, serpiginous, slightly-elevated, erythematous, raised tract between toes T3 and T4 on the dorsal surface of the left foot.

Corresponding author: Paulo Ricardo Martins-Filho, Federal University of Sergipe, Investigative Pathology Laboratory, Sergipe, Brazil
e-mail: prmartinsfh@gmail.com

Received: October 24, 2023 Accepted: December 07, 2023 Available Online Date: xxxxxx • DOI: 10.4274/balkanmedj.galenos.2023.2023-10-47

Available at www.balkanmedicaljournal.org

ORCID iDs of the authors: P.R.M-F. 0000-0001-8779-0727; R.F.S-N. 0000-0003-4500-5705..

Cite this article as:

Martins-Filho PR, Reinheimer DM, Soares-Neto RF. Cutaneous Larva Migrans. *Balkan Med J*;

Copyright@Author(s) - Available online at <http://balkanmedicaljournal.org/>