



Spot Diagnosis for Suspected COVID-19 Cases: is there a Place for a Traditional Weapon in Modern Combat?

Petros V. Vlastarakos¹, Alexandros Delides¹, Giorgos Sideris¹, Sotirios Tsiodras²

¹2nd University ENT Department, University General Hospital Attikon, Chaidari, Greece

²4th Department of Internal Medicine, University General Hospital Attikon, Chaidari, Greece

Severe acute respiratory syndrome-coronavirus-2 (SARS-CoV-2) is the causative factor of coronavirus disease 2019 (COVID-19) infection, and since 2020, it has developed into a public health emergency of international concern, displaying the characteristics of a pandemic. The mutagenic evolution of the virus has led the World Health Organization (WHO) to identify several variants of interest and a smaller, albeit significant, number of variants of concern (VOC). The Omicron variant is the fifth VOC announced by the WHO. It forms the genetic basis for the emergence of new SARS-CoV-2 variants because of its dominant presence since February 2022, coupled with its high antigenic and functional plasticity.¹

Neurogenic loss of taste and smell appears to be uncommon in Omicron compared with previous variants. The most commonly reported symptoms include nasal congestion or rhinorrhea, cough, sneezing, sore throat, headache, and fatigue.² Referring to the clinical appearance of COVID-19 infections in recent times, we have increasingly encountered a clinical manifestation characterized by a solid whitish exudate, resembling asbestos. This exudate extended caudally from the nasopharynx to the lateral pharyngeal bands

and aryepiglottic folds, sparing the faucial tonsils. The exudate was detached with minimal resistance, and the respective cultures were negative. The main patient complaints were significant dysphagia and fever. However, despite the supraglottic extension of the exudates, no significant respiratory distress was experienced (Figure 1a). Laboratory testing showed positive infection markers. Furthermore, the SARS-CoV-2 nasal swab was also positive. Hospital admission could be considered the preferred course of action because of the inability of oral intake and concerns regarding potential airway compromise. However, symptoms rapidly diminished following hydration and analgesia, thereby eliminating the need for supplementary oxygen. Nevertheless, exudative elements persisted within the aryepiglottic folds until at least the first weekly follow-up (Figure 1b).

SARS-CoV-2 continues to evolve. Newer VOCs demonstrate heightened transmissibility and immune evasion, as evidenced by a reduction in neutralization by antibodies generated against the current variants.³ Therefore, an elevated susceptibility to breakthrough infections remains a risk to older individuals and those with comorbidities, particularly for individuals who are immunosuppressed,

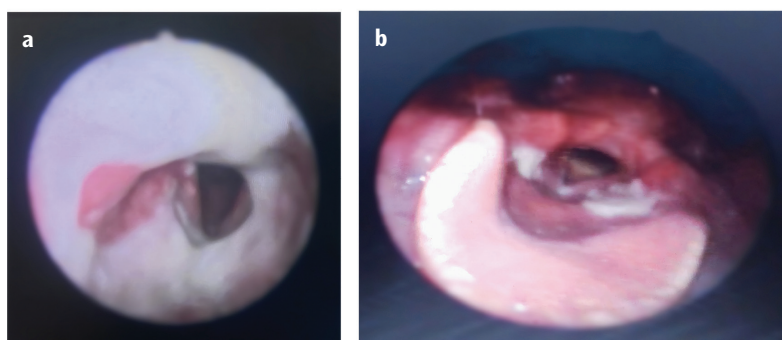


FIG. 1. a) Supraglottic exudate extension in a SARS-CoV-2 patient on admission, b) Endoscopic image of a SARS-CoV-2 patient seven days post-discharge

Corresponding author: Petros V. Vlastarakos, 2nd University ENT Department, University General Hospital Attikon, Chaidari, Greece

e-mail: pevlast@hotmail.com

Received: November 30, 2023 **Accepted:** January 15, 2024 **Available Online Date:** xxxxxx • **DOI:** 10.4274/balkanmedj.galenos.2024.2023-11-133

Available at www.balkanmedicaljournal.org

ORCID iDs of the authors: P.V.V. 0000-0002-2803-1971; A.D. 0000-0002-2349-2111; G.S. 0000-0002-5748-091X; S.T. 0000-0002-0463-4321.

Cite this article as: Vlastarakos PV, Delides A, Sideris G, Tsiodras S. Spot Diagnosis for Suspected COVID-19 Cases: is there a Place for a Traditional Weapon in Modern Combat?. *Balkan Med J.*

Copyright@Author(s) - Available online at <http://balkanmedicaljournal.org/>

unvaccinated, or under-vaccinated.^{1,4} Moreover, the clinical manifestations of COVID-19 infection have changed, with symptoms now resembling those of the common cold instead of pneumonia and respiratory distress.

In contrast, diagnostic reasoning is dictated by a three-stage model.⁵ The initiation of a diagnostic hypothesis (stage 1) may rely on spot diagnosis and should, therefore, be determined by clinical experience with a specific condition.⁶ Viral infections affecting the oropharynx, such as infectious mononucleosis, are recognized for demonstrating bilateral exudate in the faucial tonsils. However, an exudate extending caudally from the nasopharynx to the aryepiglottic folds, while sparing the faucial tonsils, may not be anticipated as a clinical sign of a viral infection, such as COVID-19. The related provisional spot diagnosis, although not previously described, may prove to be a helpful additional tool for quickly suspecting, diagnosing, and treating the disease with available antivirals. This is particularly relevant in an epidemic context, characterized by increased transmissibility of the virus and nonspecific symptomatology associated with the ensuing infection. However, confirmation of this diagnosis awaits further investigation and reporting.

Informed Consent: The patients consented to the use of medical images for educational purposes upon hospital admission.

Authorship Contributions: Concept- P.V.V.; Design- P.V.V.; Data Collection or Processing- G.S.; Analysis or Interpretation- P.V.V., A.D., G.S., S.T.; Literature Search- P.V.V., A.D., S.T.; Writing- P.V.V.

Conflict of Interest: No conflict of interest was declared by the authors.

Funding: The authors declared that this study received no financial support.

REFERENCES

1. Willett BJ, Grove J, MacLean OA, et al. SARS-CoV-2 Omicron is an immune escape variant with an altered cell entry pathway. *Nat Microbiol.* 2022;7:1161-1179. [\[CrossRef\]](#)
2. Iacobucci G. Covid-19: Runny nose, headache, and fatigue are commonest symptoms of omicron, early data show. *BMJ.* 2021;375:n3103. [\[CrossRef\]](#)
3. Willett BJ, Logan N, Scott S, et al. Omicron BA.2.86 cross-neutralising activity in community sera from the UK. *Lancet.* 2023;402:2075-2076. [\[CrossRef\]](#)
4. Fernandes Q, Inchakalody VP, Merhi M, et al. Emerging COVID-19 variants and their impact on SARS-CoV-2 diagnosis, therapeutics and vaccines. *Ann Med.* 2022;54:524-540. [\[CrossRef\]](#)
5. Heneghan C, Glasziou P, Thompson M, et al. Diagnostic strategies used in primary care. *BMJ.* 2009;338:b946. [\[CrossRef\]](#)
6. Balint GP, Buchanan WW, Dequeker J. A brief history of medical taxonomy and diagnosis. *Clin Rheumatol.* 2006;25:132-135. [\[CrossRef\]](#)