



Human Monkeypox Proctitis

Yu Miyazaki¹, Takuya Adachi¹, Noriyuki Kuniyoshi², Yasuhiro Noda², Mami Nagashima³

¹Department of Infectious Diseases, Tokyo Metropolitan Toshima Hospital, Tokyo, Japan

²Department of Gastroenterology, Tokyo Metropolitan Toshima Hospital, Tokyo, Japan

³Department of Microbiology, Tokyo Metropolitan Institute of Public Health, Tokyo, Japan

A 30-year-old man was admitted to the hospital with a 4-day fever and a 2-day anorectal pain. He reported having anal intercourse with a new male partner 5 days before the onset of his symptoms. The patient had no recollection of any skin lesions on his partner and was confused about whether the partner had signs of human monkeypox (mpox). Vesicles were observed in his throat, face, trunk, and limbs following a physical examination. Anorectal examination indicated perianal erosion (Figure 1a). Two samples were collected from the

face and wrist using the protocol recommended by the World Health Organization.¹ Real-time polymerase chain reaction was performed at the Tokyo Metropolitan Institute of Public Health using the same procedure described in the reference.² The mpox viral gene was found in both skin lesions. Human immunodeficiency virus, syphilis, *Chlamydia trachomatis*, *Neisseria gonorrhoea*, and herpes simplex virus 1 and 2 were not detected during sexually transmitted disease screening. Stool tests revealed no ova, parasites, or bacteria.

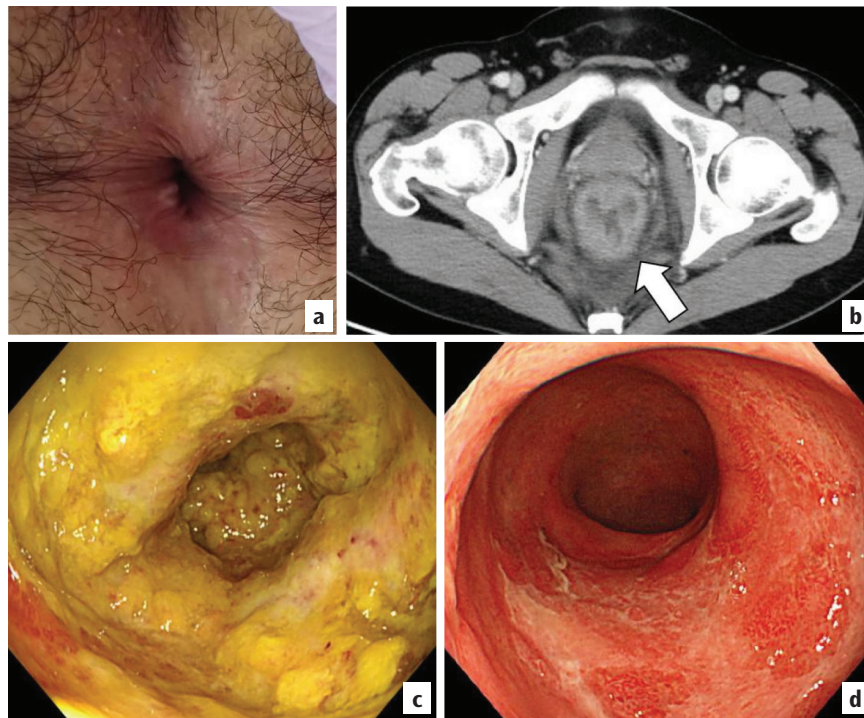


FIG. 1. Evaluation of perianal lesions and the rectum. (a) Erosion in a perianal lesion on day 5. (b) Computed tomography of the abdomen and pelvis showed circumferential wall thickening of the rectum and sigmoid, as well as reactive lymphadenopathy on day 6. (c) Colonoscopy revealed severe proctitis with circumferential erosion on day 7. (d) Colonoscopy revealed reduction in inflammation during the outpatient follow-up on day 34.



Corresponding author: Yu Miyazaki, Department of Infectious Diseases, Tokyo Metropolitan Toshima Hospital, Tokyo, Japan

e-mail: yu_miyazaki@tmhp.jp

Received: February 06, 2024 **Accepted:** March 30, 2024 **Available Online Date:** 04.07.2024 • **DOI:** 10.4274/balkanmedj.galenos.2024.2024-1-94

Available at www.balkanmedicaljournal.org

ORCID iDs of the authors: Y.M. 0009-0004-6245-7230; T.A. 0000-0002-7517-238X; N.K. 0000-0003-4328-3816; Y.N. 0009-0003-0889-4977; M.N. 0000-0001-8069-9250.

Cite this article as: Miyazaki Y, Adachi T, Kuniyoshi N, Noda Y, Nagashima M. Human Monkeypox Proctitis. *Balkan Med J.*; 2024; 41(4):310-1.

Copyright@Author(s) - Available online at <http://balkanmedicaljournal.org/>

Computed tomography of the abdomen and pelvis revealed circumferential wall thickening of the rectum and sigmoid with reactive lymphadenopathy (Figure 1b). A colonoscopy revealed severe proctitis and circumferential erosion (Figure 1c). Rectal biopsies revealed inflammation but were negative for malignancy. The patient was diagnosed with human mpox proctitis and treated with analgesics. His symptoms gradually improved during hospitalization, and he was discharged on day 24. At the 34-day follow-up, his symptoms disappeared, and colonoscopy revealed mucosal inflammation in some areas; however, inflammation was significantly alleviated in most colonoscopic observations (Figure 1d).

Since the human mpox outbreak in May 2022, majority of the cases have been among men who have sex with men, and several patients have presented atypical symptoms with manifestations in the anogenital area.^{3,4} A study revealed that approximately 30% of individuals may have concomitant proctitis;⁵ however, the clinical course and endoscopic findings of human mpox proctitis are unknown. Our endoscopic findings imply that rectal inflammation improved along with the remission of rectal discomfort.

Informed Consent: The patient provided written informed consent for the publication of this report.

Authorship Contributions: Concept- Y.M., T.A., N.K., Y.N., M.N.; Design- Y.M., T.A., N.K., Y.N., M.N.; Supervision- T.A., N.K., M.N.; Data Collection or Processing- Y.M., T.A., N.K., Y.N., M.N.; Analysis or Interpretation- Y.M., T.A., N.K., Y.N., M.N.; Literature Search- Y.M., T.A., N.K., Y.N., M.N.; Writing- Y.M., Y.N.; Critical review- T.A., N.K., M.N.

Conflict of Interest: No conflict of interest was declared by the authors.

REFERENCES

1. World Health Organization. Mpox: epidemiology, preparedness and response for African outbreak contexts. Accessed March 18, 2024. [\[CrossRef\]](#)
2. Kasuya F, Negishi A, Kumagai, R, et al. Genetic characteristics of the virus detected in the first mpox imported case in Tokyo, Japan. *Jpn J Infect Dis.* 2023;76:259-262. [\[CrossRef\]](#)
3. Thornhill JP, Barkati S, Walmsley S, et al. Monkeypox Virus Infection in Humans across 16 Countries - April-June 2022. *N Engl J Med.* 2022;387:679-691. [\[CrossRef\]](#)
4. Català A, Clavo-Escribano P, Riera-Monroig J, et al. Monkeypox outbreak in Spain: clinical and epidemiological findings in a prospective cross-sectional study of 185 cases. *Br J Dermatol.* 2022;187:765-772. [\[CrossRef\]](#)
5. Guevara-Martínez J, La-Noire FP, Arteaga-Asensio P, et al. Proctitis in patients with monkeypox infection: a single-center analysis of 42 consecutive cases from a multidisciplinary observational study on monkeypox proctitis. *Tech Coloproctol.* 2023;27:1211-1218. [\[CrossRef\]](#)