



Trachelectomy After Supracervical Hysterectomy: A 7-Year Single-Center Experience

✉ Tihomir Pankov Totev^{1,2}, ✉ Georgi Danielov Prandzhev^{1,2}, ✉ Slavcho Tomov Tomov^{1,2}, ✉ Nadezhda Hristova Hinkova^{1,2}, ✉ Grigor Angelov Gortchev^{1,2}

¹Department of Obstetrics and Gynecology, Medical University - Pleven, Pleven, Bulgaria

²Department of Obstetrics and Gynecology, University Hospital Saint Marina - Pleven, Pleven, Bulgaria

Trachelectomy involves the surgical excision of the cervical stump, which may be employed to remove the residual portion of the cervix from a prior supracervical hysterectomy (SCH) or as a fertility-sparing standalone procedure. Subtotal hysterectomy is an alternative treatment option for benign gynecological conditions as well as life-threatening obstetric situations like peri- or postpartum hemorrhage and the placenta accreta spectrum. This surgical intervention is frequently preferred for its technical simplicity, shorter duration, and decreased perioperative complications.¹

This single-center, retrospective study reviewed sixteen cases of simple and radical trachelectomies that were performed for benign and malignant conditions following subtotal uterus removal over a 7-year period.

We assessed the SCH indications, trachelectomy types, timing, and surgical approaches. The demographic data included age, age group distribution, and medical and surgical histories. The intraoperative complications and postoperative course were recorded. We compared histopathological findings, operative times, duration of hospital stay, hemoglobin level alterations, and intraoperative blood loss.

The Wilcoxon and Kruskal-Wallis tests evaluated paired samples and independent groups. The data were summarized employing frequencies and medians, and post hoc tests identified significant differences.

The median age of the participants was 52.67 years (range, 27-77 years). Our results demonstrate a significantly longer interval between the SCH and the emergence of new symptoms necessitating surgical intervention-11 years on average (range, 6-528 months). In our study, benign neoplasms, specifically ovarian cysts (2/16) and uterine fibroids (8/16), were the most prevalent indications for SCH. These indications were followed by abnormal uterine bleeding (1/16), dysmenorrhea (1/16), and perforation after an instrumental procedure (1/16). No information was available regarding the

remaining three patients. Notably, in 50.0% of the group participants, the indication for trachelectomy was invasive cervical carcinoma, and 6.3% experienced persistent severe dysplasia (Figure 1). In 25.0% of the cases, the patients were operated on for genital prolapse. The other group (12.5%) consisted of ovarian neoplasms, including benign cysts in menopausal women and ovarian carcinoma in FIGO IA stage. Persistent cervical stump bleeding was observed in 6.2% of the participants.

Nine patients (56.3%) underwent open surgery, five underwent laparoscopic surgery (31.3%), and the remaining two women underwent vaginal trachelectomy (12.5%). Regardless of the operative approach selected, the surgical resection volume is reduced to either a simple trachelectomy or a radical trachelectomy, which involves the removal of the parametrium and the use of a vaginal cuff. In seven patients, a radical open abdominal technique was implemented, which included pelvic lymph node dissection. Two patients underwent vaginal trachelectomy, and two from the laparoscopic group underwent additional vaginoplasty due to

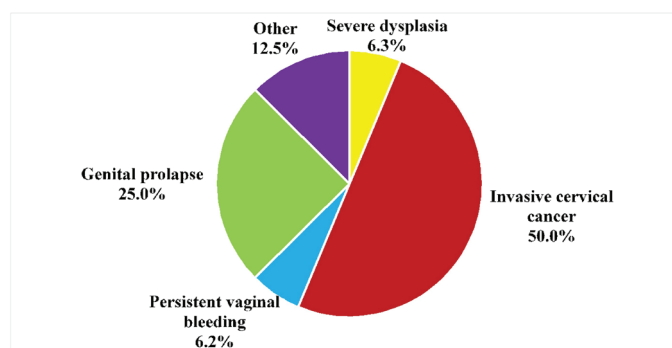


FIG. 1. Trachelectomy indications post supracervical hysterectomy.

Corresponding author: Georgi Danielov Prandzhev, Department of Obstetrics and Gynecology, Medical University - Pleven; University Hospital Saint Marina - Pleven, Pleven, Bulgaria

e-mail: georgi.prandzhev@gmail.com

Received: July 01, 2024 **Accepted:** August 15, 2024 **Available Online Date:** xxxxx • **DOI:** 10.4274/balkanmedj.galenos.2024.2024-6-30

Available at www.balkanmedicaljournal.org

ORCID iDs of the authors: T.P.T. 0000-0002-4381-3082; G.D.P. 0000-0001-9612-3838; S.T.T. 0000-0001-7919-946X; N.H.H. 0000-0001-8969-507X; G.A.G. ORCID 0000-0002-4710-9340.

Cite this article as: Totev TP, Prandzhev GD, Tomov Tomov S, Hinkova NH, Gortchev GA. Trachelectomy After Supracervical Hysterectomy: A 7-Year Single-Center Experience. *Balkan Med J*;

Copyright@Author(s) - Available online at <http://balkanmedicaljournal.org/>

genital prolapse. Squamous cell carcinoma was the most commonly diagnosed histological subtype in our study (5/8), followed by adenocarcinoma (2/8), and one case of carcinosarcoma. Two patients were diagnosed with ovarian pathology (persisting benign tumors during menopause and ovarian cancer, FIGO IA stage). One patient in the laparoscopic group underwent surgery for persistent, severe cervical dysplasia.

In our study, a statistically significant difference was identified in the hemoglobin levels of participants who underwent laparoscopic trachelectomy ($z = -2.023$, $p = 0.043$). Additionally, the individual groups differed significantly in operative time ($H = 12,609$, $df = 3$, $p = 0.006$) and in postoperative hospital stay ($H = 10,836$, $df = 3$, $p = 0.013$). The median operative duration was 120 minutes (range, 50-195 minutes). Vaginal trachelectomy was performed with a median duration of 97.5 minutes (range, 90-105 minutes), while radical abdominal trachelectomy was performed with a median operative duration of 120 minutes (range, 120-195 minutes).

Two intraoperative complications were observed in one patient: an intestinal loop lesion and a bladder injury, accounting for a cumulative low complication frequency of 6.25%. This patient underwent laparoscopic trachelectomy and vaginal plastic surgery due to genital prolapse. After radical abdominal trachelectomy with pelvic lymphadenectomy, blood transfusion was necessary in two cases (12.5%) during the intraoperative and early postoperative periods. The postoperative period was uneventful for the entire group.

We were unable to monitor the condition of five patients who underwent cervical carcinoma treatment following their discharge from the hospital. The remaining patients were monitored for periods of 77 days, 33 days, and 1 month, respectively. They reported a satisfactory overall condition with no indication of recurrence. The patient who received trachelectomy for ovarian cancer was observed for 70 months and reported no further disease progression.

Our study findings differed from those of most publications regarding trachelectomy indications. A multicenter study observed an average duration of 4.40 years between SCH and novel clinical manifestations.² Neis et al.³ identified prolapse (31.4%), bloody spotting (19%), and intraepithelial neoplasia (18.2%) as the predominant causes necessitating cervical excision. Additional investigations noted concordance between the indications for primary subtotal hysterectomy and subsequent trachelectomy, including pelvic pain, abnormal bleeding, and dysmenorrhea.^{4,5} No correlation was observed between the initial indication for surgery and the subsequent surgical procedure performed in our series. The most common causes of antecedent subtotal hysterectomy in our study were benign uterine and ovarian tumors (62.5%). Cervical cancer was diagnosed in 50.0% of the patients in our study

who underwent trachelectomies, compared to 2.92%³ and 5.3%⁶ reported in other cohorts. Several concerns regarding surveillance protocols or inadequate management were raised because of the high proportion of invasive malignancies. The psychological relief provided by SCH does not diminish the need for careful, long-term surveillance. It highlights a critical issue: the lack of postoperative follow-up to identify precancerous or invasive disease early. The significance of preoperative cervical examination in elective operations, as well as continuous cervical screening following SCH, is underscored by these conclusions and the results of our series. Patients who have undergone this procedure should be informed about the potential risk of cervical stump cancer and the significance of regular follow-up and screening.

Suboptimal decisions regarding the initial surgery frequently necessitate trachelectomies following SCH. Patients should be thoroughly informed about potential postoperative complications, as retaining the cervix does not guarantee pelvic floor integrity. Cervical cancer, the leading surgical indication in our study, underscores the need for cervical screening. Radical trachelectomy should be performed in specialized oncology centers due to its complexity and associated risks. Additional studies are warranted to optimize patient selection and surgical techniques for achieving superior outcomes.

Informed Consent: Written informed consent was obtained from the patients for the publication of this case report and accompanying images.

Authorship Contributions: Concept- S.T., G.A.G.; Design- T.P.T., S.T.; Supervision- S.T., G.A.G.; Materials- G.D.P., N.H.H.; Data Collection or Processing- G.D.P.; Analysis or Interpretation- T.P.T., G.D.P., N.H.H.; Literature Search- T.P.T., G.D.P.; Writing- T.P.T., G.D.P.; Critical Review- T.P.T., S.T., N.H.H., G.A.G.

Conflict of Interest: No conflict of interest was declared by the author.

REFERENCES

1. Mueller MG, Kenton KS. Trachelectomy: removal of cervical stump following supracervical hysterectomy. In: Alkatout I, Mettler L, editors. *Hysterectomy*. Springer, Cham.; 2018:1473-1476. [\[CrossRef\]](#)
2. Dawood AS, Harras HF, Moussa HR, Soliman AS. Surgical outcomes of laparoscopic trachelectomy following supracervical hysterectomy: a multicenter study. *Obstet Gynecol Sci*. 2022;65:542-551. [\[CrossRef\]](#)
3. Neis F, Reisenauer C, Kraemer B, Wagner P, Brucker S. Retrospective analysis of secondary resection of the cervical stump after subtotal hysterectomy: why and when? *Arch Gynecol Obstet*. 2021;304:1519-1526. [\[CrossRef\]](#)
4. Tsafirir Z, Aoun J, Hanna R, Papalekas E, Schiff L, Theoharis E, Eisenstein D. Robotic Trachelectomy After Supracervical Hysterectomy for Benign Gynecologic Disease. *JSL*. 2016;20:e2016.00027. [\[CrossRef\]](#)
5. Ayaty M, Khalifa H, Aboleka S, Wahab H. Vaginal trachelectomy for retained cervical stump after supracervical hysterectomy: technical tips and outcomes. *Open J Obstet Gynecol*. 2022;12:624-632. [\[CrossRef\]](#)
6. McHale MP, Smith AJB, Fader AN, Wethington SL. Outcomes of women undergoing excision of the retained cervix after supracervical hysterectomy. *Obstet Gynecol*. 2021;137:831-836. [\[CrossRef\]](#)