



# Orbital Myositis as a Paradoxical Reaction to Anti-Tuberculosis Treatment

Koichi Yano<sup>1</sup>, Kyoko Yokosuka<sup>1</sup>, Kiyomi Amemiya<sup>2</sup>, Kentaro Sakashita<sup>1,3</sup>, Takuto Ishida<sup>1</sup>

<sup>1</sup>Department of Internal Medicine, Tokyo Metropolitan Matsuzawa Hospital, Setagaya, Tokyo, Japan

<sup>2</sup>Department of Radiology, Tokyo Metropolitan Matsuzawa Hospital, Setagaya, Tokyo, Japan.

<sup>3</sup>Department of Pulmonary Medicine, Takayama Red Cross Hospital, Takayama, Gifu, Japan

A 66-year-old female with pulmonary tuberculosis presented with ocular pain and blurred vision eight weeks after commencing anti-tuberculosis treatment, which consisted of isoniazid 200 mg, rifampicin 450 mg, ethambutol 750 mg, and pyrazinamide 1000 mg. The physical examination revealed bilateral eyelid edema, chemosis, and conjunctival congestion (Figure 1a, b). Diplopia and proptosis were not observed. A contrast-enhanced computed tomography (CT) of the head demonstrated contrast enhancement of the eyelid and extraocular muscles (lateral rectus muscle and medial rectus muscle; Figure 1c). Improvement of a pre-existing pulmonary infiltrative shadow and the development of new enlarged mediastinal lymph nodes were apparent on a chest CT. The results of acid-fast bacillus cultures of the sputum collected at the onset of ocular symptoms were negative.

The clinical findings were consistent with orbital myositis (OM), which is considered a paradoxical reaction (PR) to anti-tuberculosis treatment. The patient's symptoms were alleviated within two days following the administration of prednisolone at a 1 mg/kg dose.

OM is a rare inflammatory disease. Its symptoms include ocular pain, ocular motility disorder, eyelid swelling, conjunctival edema, and hyperemia, as well as enlargement of the external ocular muscles. Its etiological factors include autoimmune diseases (e.g., immunoglobulin G4-related diseases, inflammatory bowel disease, sarcoidosis, systemic lupus erythematosus), and infective conditions (e.g., *Mycobacterium tuberculosis*, group-A *Streptococci*, herpes zoster virus, Lyme disease).<sup>1,2</sup> Corticosteroids are the preferred treatment option, as they frequently induce rapid symptomatic alleviation within a few days.<sup>3</sup>

Nakamura et al.<sup>2</sup> identified pulmonary tuberculosis as the cause of OM. In this case, OM was diagnosed prior to treatment for pulmonary tuberculosis. Furthermore, the patient's ocular symptoms did not resolve following steroid therapy. The administration of anti-tuberculosis medications resulted in a resolution of pulmonary tuberculosis lesions and an improvement in her ocular symptoms. Hence, it was concluded that *Mycobacterium tuberculosis* was the cause of OM.

The patient's mediastinal lymph nodes were found to be enlarged on CT at the onset of the ocular symptoms, despite the negative results of acid-fast bacillus cultures of the sputum and lacrimal fluid. While previous pulmonary tuberculosis lesions resolved, the patient developed emergent OM, which was accompanied by the appearance of the new thoracic lesions. Consequently, it is reasonable to infer that OM was precipitated by a PR to the anti-tuberculosis treatment in this patient. PR is defined as the exacerbation or recurrence of pre-existing lesions, or the development of new lesions despite an effective anti-tuberculosis treatment. It is hypothesized that its pathogenesis involves the release of significant amounts of tuberculosis antigens following anti-tuberculosis drug treatment, which triggers an inflammatory response.<sup>4</sup> The lymph nodes are the primary site of PR; however, it can manifest in any location, such as the central nervous system and musculoskeletal system.<sup>5</sup>

Despite its rarity, OM can cause ocular ischemia and optic neuritis. If untreated, these conditions can lead to blindness.<sup>1,6</sup> Hence, early diagnosis and treatment are crucial. Clinicians should therefore proactively evaluate for ocular manifestations during anti-tuberculosis treatment.

**Corresponding author:** Koichi Yano, Department of Internal Medicine, Tokyo Metropolitan Matsuzawa Hospital, Setagaya, Tokyo, Japan

**e-mail:** [correspondence2023@yahoo.co.jp](mailto:correspondence2023@yahoo.co.jp)

**Received:** July 18, 2024 **Accepted:** August 22, 2024 **Available Online Date:** xxxxxx • **DOI:** 10.4274/balkanmedj.galenos.2024.2024-7-10

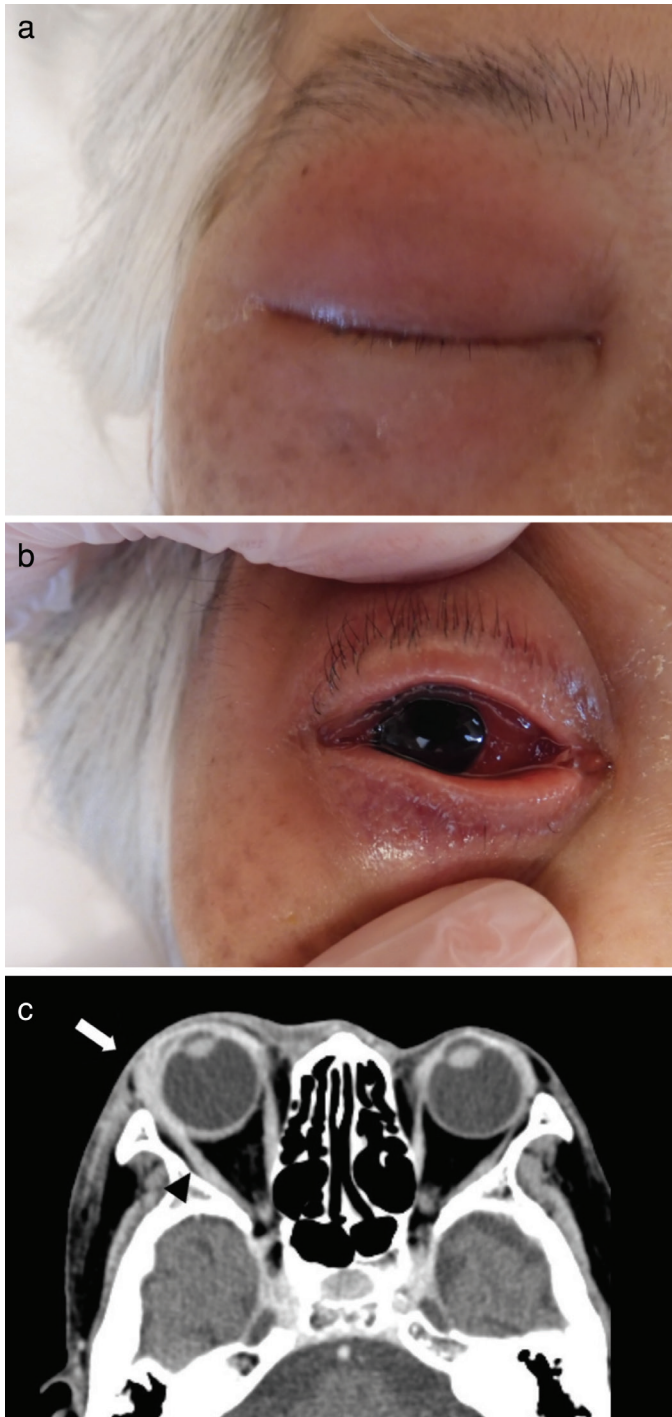
Available at [www.balkanmedicaljournal.org](http://www.balkanmedicaljournal.org)

**ORCID iDs of the authors:** K.Y. 0009-0002-4572-7513; K.Y. 0009-0000-4645-8752; K.A. 0009-0008-2502-2915; K.S. 0000-0002-3948-5557; T.I. 0000-0001-7038-8459.

**Cite this article as:** Yano K, Yokosuka K, Amemiya K, Sakashita K, Ishida T. Orbital Myositis as a Paradoxical Reaction to Anti-Tuberculosis Treatment. *Balkan Med J*;

**\*The manuscript was presented orally in 183<sup>rd</sup> Kanto branch conference of the Japanese Society for Tuberculosis and Non-tuberculous Mycobacterial Infection, February 25, 2023, Tokyo, Japan.**

Copyright@Author(s) - Available online at <http://balkanmedicaljournal.org/>



**FIG. 1.** (a) Eyelid edema; (b) chemosis and conjunctival congestion; (c) computed tomography revealed contrast-enhanced eyelids (white arrow) and extraocular muscles (black arrow).

**Informed Consent:** Written informed consent was obtained from the patient.

**Authorship Contributions:** Supervision- T.I.; Writing- Ko.Y.; Critical Review- Ky.Y., K.A., K.S., T.I.

**Conflict of Interest:** No conflict of interest was declared by the authors.

## REFERENCES

1. McNab AA. Orbital Myositis: A Comprehensive Review and Reclassification. *Ophthalmic Plast Reconstr Surg.* 2020;36:109-117. [\[CrossRef\]](#)
2. Nakamura K, Horio Y, Yamanaka T. A case of pulmonary tuberculosis associated with orbital myositis. *Kekkaku.* 2012;87:501-505 (Japanese). [\[CrossRef\]](#)
3. Fang Y, Shen B, Dai Q, Xie Q, Wu W, Wang M. Orbital inflammatory pseudotumor: new advances in diagnosis, pathogenesis, and treatment. *Eur J Med Res.* 2023;28:395. [\[CrossRef\]](#)
4. Lanzafame M, Vento S. Tuberculosis-immune reconstitution inflammatory syndrome. *J Clin Tuberc Other Mycobact Dis.* 2016;3:6-9. [\[CrossRef\]](#)
5. Bell LC, Breen R, Miller RF, Noursadeghi M, Lipman M. Paradoxical reactions and immune reconstitution inflammatory syndrome in tuberculosis. *Int J Infect Dis.* 2015;32:39-45. [\[CrossRef\]](#)
6. Davis G, Li K, Fuchs S, Pan A. Rapid Loss and Recovery of Vision Following Steroid Treatment in Orbital Myositis: A Case Report. *J Investig Med High Impact Case Rep.* 2023;11:23247096221148261. [\[CrossRef\]](#)