



# Perineal Approach for Female Epispadias Repair and Providing Continence

Dinçer Avlan<sup>1</sup>, Sadettin Yıldız<sup>2</sup>, İrem İnang<sup>2</sup>

<sup>1</sup>Department of Pediatric Surgery, Division of Pediatric Urology, Trakya University Faculty of Medicine, Edirne, Turkey

<sup>2</sup>Department of Pediatric Surgery, Trakya University Faculty of Medicine, Edirne, Turkey

Female epispadias is a rare congenital urogenital anomaly occurring in one out of every 484,000 female patients. It is anatomically characterized by a short and wide epispadic urethra, an open bladder neck, a bifid clitoris, and typically a small bladder capacity.<sup>1</sup> The primary issue for patients is urinary incontinence, resulting from a widely open and incompetent bladder neck, a short and non-resistant urethra, and generally poor bladder capacity.<sup>2,3</sup>

The main goals of surgical treatment in female children with epispadias are to achieve satisfactory urinary continence and functionally and cosmetically acceptable external genitalia. Historically, female epispadias was managed through staged repairs involving initial urethral and vulvar reconstruction, followed by bladder neck reconstruction using the Young-Dees-Leadbetter (YDL) technique at a later stage.<sup>3</sup> Recently, single-stage perineal urethrocervicoplasty and its modifications have been preferred for female epispadias repair.<sup>4-6</sup>

This letter presents the technique details of female epispadias repair, including bladder neck plication guided by cystoscopy, bladder neck suspension to the pubic bone, urethral lengthening, and vulvoplasty, all performed through a single-stage perineal approach to achieve urinary continence and acceptable cosmetic results.

A 6-year-old female patient presented with a history of constant diurnal and nocturnal urinary incontinence, relying on diapers. Examination of the external genitalia revealed a short and wide epispadic urethra and a bifid clitoris (Figure 1a). Urinalysis, urinary ultrasound, and voiding cystourethrography were normal.

In the lithotomy position, cystourethroscopy was performed prior to corrective surgery, revealing a short and wide urethra, a wide bladder neck, and a normal bladder (Figure 1b). A diamond-shaped incision was made along the urethral plate and skin border, extending inferiorly just lateral to the urethral plate at the 9 and 3 o'clock positions to form a flap for creating the neourethra (Figure 1c). Dissection proceeded into the subsymphyseal region. The bladder

neck was fully released by incising through the endopelvic fascia into the Retzius space with sharp dissection. Extramucosal bladder neck plication was then performed with non-absorbable sutures (2-0 Prolene) under cystoscopic guidance (Figure 1d). Adequate bladder neck outlet resistance was confirmed by intraoperative cystoscopic evaluation (Figure 1e). After plication, the bladder neck was bilaterally suspended to the pubic bone using 3-0 non-absorbable sutures to enhance outlet resistance (Figure 1f). To further contribute to the continence mechanisms, the urethral plate was tubularized using 4-0 polyglactin over a 10 Fr silicone Foley catheter, forming a neourethra (Figure 1g). The procedure concluded with cosmetic reconstruction of the external genitalia (Figure 1h).

On the postoperative day 10, the patient's Foley catheter was removed, spontaneous voiding was noted, and she was discharged. During follow-up consultations at 1, 3, 6, and 12 months, there was no urinary incontinence. Additionally, during an examination performed under general anesthesia, the urethral meatus was observed to be in the normal anatomical position and caliber.

The treatment goal in female epispadias is to achieve complete urinary continence and a cosmetically acceptable appearance of the external genitalia. The classic surgical approach for urinary incontinence is YDL bladder neck reconstruction.<sup>1</sup> In female patients with epispadias, Hendren demonstrated successful application of this procedure via a one-stage combined perineal transvesical approach.<sup>2</sup> Kramer and Kelalis<sup>7</sup> described 12 patients who underwent YDL bladder neck reconstruction with a one-stage perineal approach. Conversely, Gearhart et al.<sup>3</sup> described a staged reconstruction with genitourethral repair performed at 1-1.5 years, followed by suprapubic YDL bladder neck reconstruction at 4-5 years. Although the overall continence rate of these procedures, including YDL bladder neck reconstruction was 83-90%, they were associated with higher morbidity.

A closed and resistant bladder neck, a urethra of normal caliber and length, and correct anatomical positioning are crucial for urinary

**Corresponding author:** Sadettin Yıldız, Department of Pediatric Surgery, Trakya University Faculty of Medicine, Edirne, Turkey

**e-mail:** sadettin.yildiz1@gmail.com

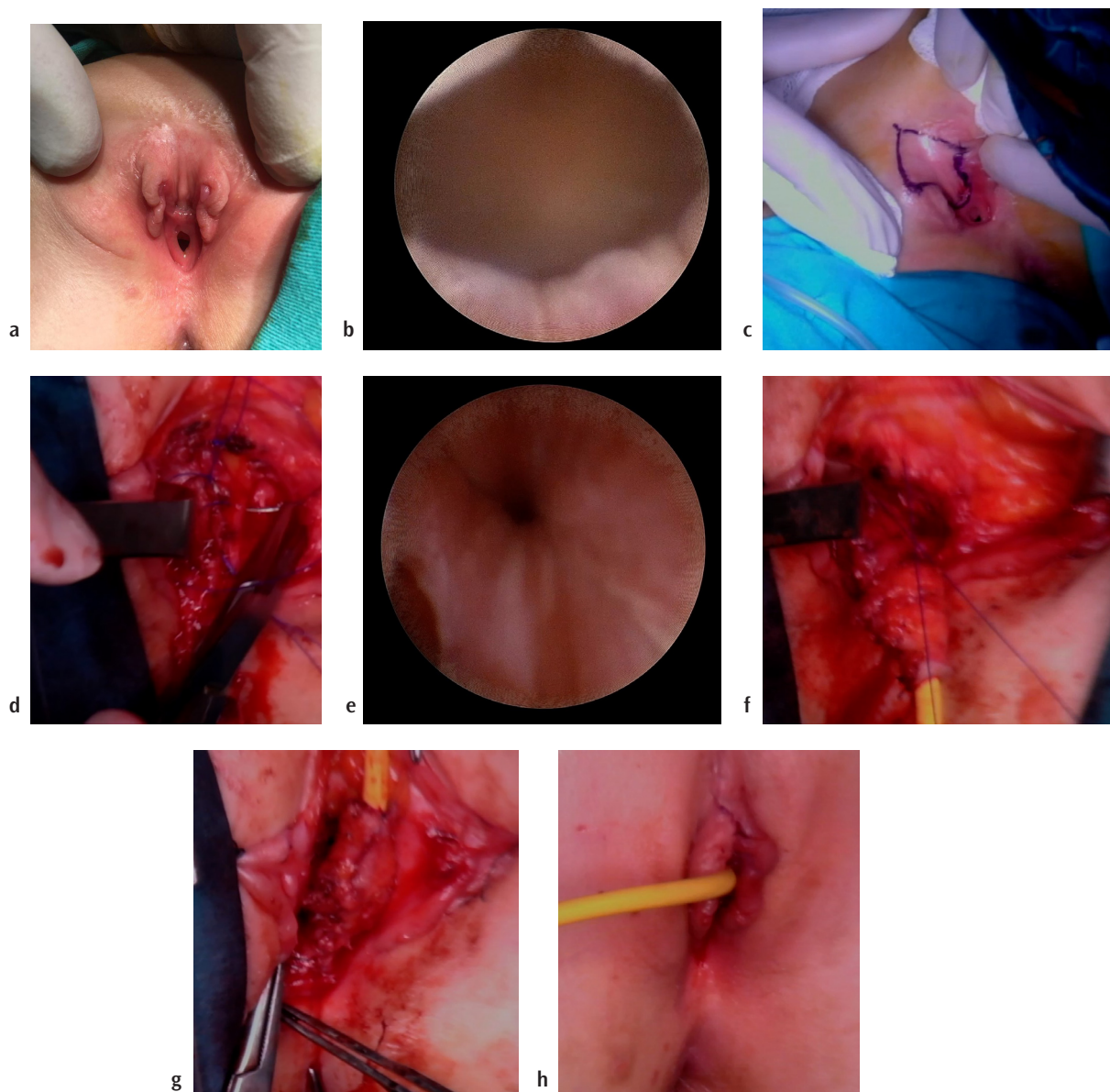
**Received:** September 09, 2024 **Accepted:** October 10, 2024 **Available Online Date:** xxxxxx • **DOI:** 10.4274/balkanmedj.galenos.2024.2024-8-138

Available at [www.balkanmedicaljournal.org](http://www.balkanmedicaljournal.org)

**ORCID iDs of the authors:** D.A. 0000-0002-1118-3792; S.Y. 0000-0002-7812-3081; İ.I. 0000-0003-1162-8613.

**Cite this article as:** Avlan D, Yıldız S, İnang İ. Perineal Approach for Female Epispadias Repair and Providing Continence. *Balkan Med J*;

Copyright@Author(s) - Available online at <http://balkanmedicaljournal.org/>



**FIG. 1.** (a) Wide episodic urethra and a bifid clitoris. (b) Endoscopic view of a wide bladder neck. (c) Diamond-shaped incision on the urethral plate. (d) Bladder neck plication. (e) Endoscopic view of the bladder neck after plication. (f) Suspension of the bladder neck to the pubic bone. (g) Tubularization of the urethral plate to create the neourethra. (h) The surgery was completed with cosmetic reconstruction of the external genitalia.

continence. In recent years, surgical approaches have aimed to restore these anatomical features essential for continence while minimizing the time, achieving a single-session surgery with minimal dissection.

de Jong et al.<sup>4</sup> described urethral and pelvic reconstruction with bladder neck suspension through a single-stage perineal approach, successfully treating 3 of 4 patients by repositioning the bladder neck and urethra into an intra-abdominal position. Subsequently, Bhat et al.<sup>8</sup> outlined a single-stage perineal urethroplasty for continence in female patients with epispadias, creating a new continence zone by constructing a neourethra, double-breasting the urethral wall, and coapting the lax pelvic floor muscles around the reconstructed

urethra. In another study, Cheikhelard et al.<sup>5</sup> compared traditional YDL bladder neck reconstruction with perineal urethrocervicoplasty, and suggested that perineal urethrocervicoplasty is promising, yielding similar results with less postoperative morbidity and fewer additional surgeries.

Recently, Kajbafzadeh et al.<sup>9</sup> were the first to describe cystoscopy-guided bladder neck plication for continence in female epispadias using a perineal approach and published their long-term follow-up results. They reported complete continence in 6 out of 10 patients during long-term follow-up.<sup>9</sup> Concurrently, Lazarus et al.<sup>10</sup> used the same technique for continence in two patients. In 2017, Yadav et al.<sup>11</sup> reported plicated and suspended bladder neck reconstruction

using a single-stage perineal approach. Unlike others, they did not use cystoscopy during bladder neck plication, instead bilaterally suspended the bladder neck from the pubic bone after plication.<sup>11</sup> This approach helped maintain anatomical urethrovesical angulation, thereby enhancing outflow resistance and maintaining continence.

We present the case of a 6-year-old girl with epispadias who underwent a single-stage surgical repair involving infrasympyseal bladder neck plication, bladder neck suspension, urethral lengthening, and genitoplasty. This surgical procedure successfully resulted in full continence. We propose that bladder neck plication and suspension are essential in restoring urethrovesical angulation and enhancing outflow resistance. Additionally, urethral lengthening is highlighted as vital for continence, as normal urethral length is necessary for achieving continence. Therefore, we constructed a neourethra with normal caliber and length through urethral plate tubularization. We recommend ensuring sufficient urethral lengthening during surgery, along with bladder neck plication and suspension, to achieve full continence.

**Informed Consent:** Informed consent was obtained from the patient's legal guardians.

**Authorship Contributions:** Concept- D.A.; Design- D.A.; Supervision- D.A.; Data Collection or Processing- S.Y., I.I.; Analysis or Interpretation- D.A., S.Y., I.I.; Literature Search- S.Y., I.I.; Writing- D.A.; Critical Review- S.Y., I.I.

**Conflict of Interest:** No conflict of interest was declared by the authors.

## REFERENCES

1. Gearhart JP, DiCarlo HN. Exstrophy-epispadias complex. In: Partin AW, Dmochowski RR, Kavoussi LR, Peters CA (eds). *Campbell-Walsh-Wein Urology* (12th edition). Chapter 31. Philadelphia. Elsevier Co.; 2021; p. 528-580. [\[CrossRef\]](#)
2. Hendren WH. Congenital female epispadias with incontinence. *J Urol*. 1981;125:558-564. [\[CrossRef\]](#)
3. Gearhart JP, Peppas DS, Jeffs RD. Complete genitourinary reconstruction in female epispadias. *J Urol*. 1993;149:1110-1113. [\[CrossRef\]](#)
4. de Jong TP, Dik P, Klijn AJ. Female epispadias repair: a new 1-stage technique. *J Urol*. 2000;164:492-494. [\[CrossRef\]](#)
5. Cheikhelard A, Aigrain Y, Lottmann H, Lortat-Jacob S. Female epispadias management: perineal urethrocervicoplasty versus classical Young-Dees procedure. *J Urol*. 2009;182(Suppl 4):1807-1811. [\[CrossRef\]](#)
6. Leclair MD, Faraj S, Villemagne T, Carrouget J, Arnaud A, Heloury Y. Primary female epispadias: perineal approach or Kelly repair? *J Pediatr Urol*. 2018;14:33-39. [\[CrossRef\]](#)
7. Kramer SA, Kelalis PP. Surgical correction of female epispadias. *Eur Urol*. 1982;8:321-324. [\[CrossRef\]](#)
8. Bhat AL, Bhat M, Sharma R, Saxena G. Single-stage perineal urethroplasty for continence in female epispadias: a preliminary report. *Urology*. 2008;72:300-304. [\[CrossRef\]](#)
9. Kajbafzadeh AM, Talab SS, Elmi A, Tourchi A. Single-stage subsymphyseal cystoscopic-guided bladder neck plication and urethrogenitoplasty in female epispadias: presentation of long-term follow-up. *BJU Int*. 2011;108:1200-1207. [\[CrossRef\]](#)
10. Lazarus J, van den Heever A, Kortekaas B, Alexander A. Female epispadias managed by bladder neck plication via a perineal approach. *J Pediatr Urol*. 2012;8:244-248. [\[CrossRef\]](#)
11. Yadav SS, Agarwal N, Kumar S, Tomar V, Vyas N, Teli R, et al. Single-stage female epispadias repair by combined infrasympyseal bladder neck plication and urethrogenitoplasty: a novel technique. *Urology*. 2017;100:240-245. [\[CrossRef\]](#)