



Multimodality Imaging Assessment of a Multi-Organ Hydatid Cyst

Leizhi Ku¹, Xiaojing Ma²

¹Department of Radiology, Wuhan Asia Heart Hospital, Wuhan University of Science and Technology, Wuhan, China

²Department of Echocardiography, Wuhan Asia Heart Hospital, Wuhan University of Science and Technology, Wuhan, China

A 63-year-old woman presented with complaints of chest tightness and shortness of breath for one month following physical activity. The physical examination and routine laboratory test results were unremarkable. Electrocardiogram demonstrated negative T waves in the II, III, and aVF leads and intraventricular conduction delay with QRS duration of 160 ms. Left heart border enlargement with eggshell-like calcification was observed on chest X-ray (Figure 1a). Transthoracic echocardiography indicated a round, heterogeneous mass with patchy calcification in the left ventricle (LV) (Figure 1b). A contrast-enhanced computed tomography (CT) scan demonstrated a 59 × 62 × 85 mm cystic mass with ring-like calcifications, primarily affecting the LV inferior lateral wall and interventricular septum (Figure 1c); 3D volume-rendered CT images revealed the mass to be protruding from the lower wall of the LV with multiple calcifications (Figure 1d). Non-enhanced abdominal CT indicated multiple cystic lesions with eggshell-like calcification within the liver and spleen. (Figure 1e, f). The patient underwent resection of the cardiac cystic mass. The postoperative histopathological examination confirmed the diagnosis of hydatid cyst disease.

Hydatid cysts, also referred to as cystic echinococcosis, hydatidosis, or hydatid disease, can occur almost anywhere in the body and can manifest complications of diverse clinical characteristics that vary based on growth stages, associated complications, and affected organization.¹ The most frequently involved organs are the liver (75%) and lungs (15%). Cardiac involvement is very rare but potentially fatal and occurs in 0.5-2% of patients.² The incidence of multiorgan involvement is 19%.³ The presentation of hydatid cysts may vary from asymptomatic to atypical chest pain, dyspnea, asthenia, and palpitations. Some patients with hydatid cysts can experience life-threatening complications, including rupture, anaphylaxis, systemic or pulmonary embolization, pericardial tamponade, and cardiogenic shock.⁴ Timely diagnosis and intervention are crucial for minimizing fatal complications. Multimodality imaging techniques are crucial for performing accurate diagnosis and preoperative evaluation. Knowledge of the imaging spectrum in hydatid cysts is significantly valuable in assisting physicians in making an accurate, timely diagnosis and providing appropriate care. Surgical resection combined with concurrent albendazole therapy is the treatment of choice with favorable outcomes.⁵

Corresponding author: Xiaojing Ma, Department of Echocardiography, Wuhan Asia Heart Hospital, Wuhan University of Science and Technology, Wuhan, China

e-mail: klz1534292102@163.com

Received: November 28, 2024 **Accepted:** December 16, 2024 **Available Online Date:** xxxxx • **DOI:** 10.4274/balkanmedj.galenos.2024.2024-11-137

Available at www.balkanmedicaljournal.org

ORCID iDs of the authors: L.K. 0000-0002-0627-2088; X.M. 0000-0002-6749-0898.

Cite this article as: Ku L, Ma X. Multimodality Imaging Assessment of a Multi-Organ Hydatid Cyst. *Balkan Med J*;

Copyright@Author(s) - Available online at <http://balkanmedicaljournal.org/>

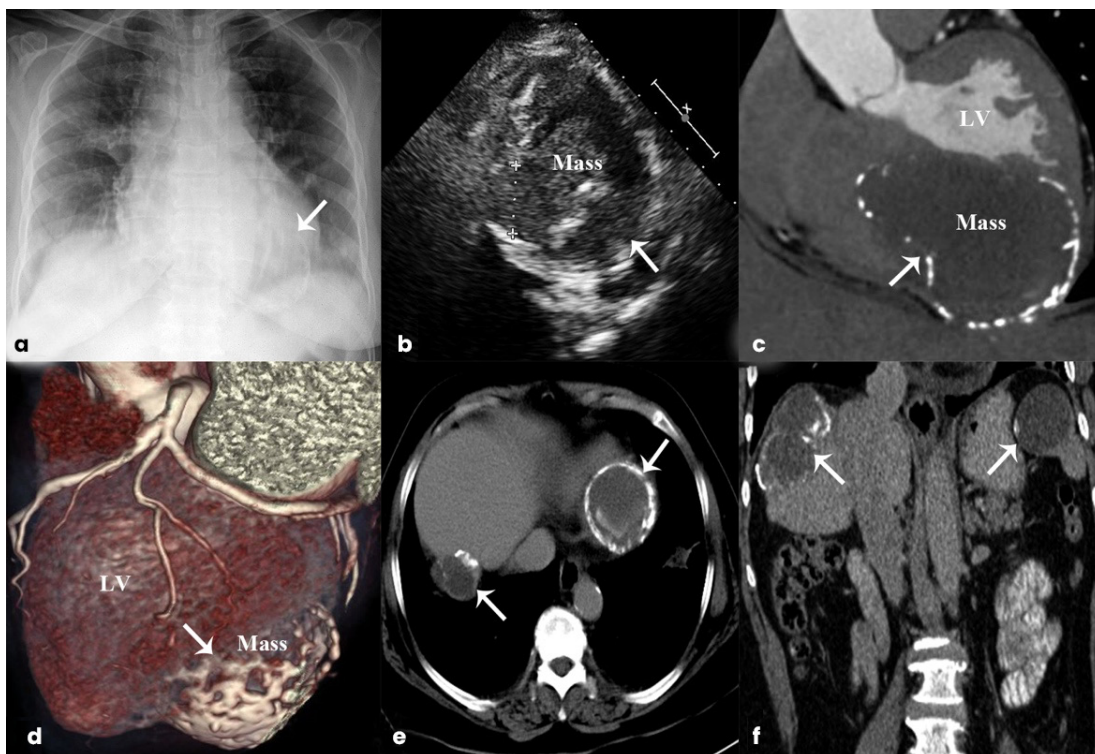


FIG. 1. (a) Left heart border enlargement with eggshell-like calcification on chest X-ray. (b) Transthoracic echocardiography reveals a round, heterogeneous mass with patchy calcification in the left ventricle. (c, d) Contrast-enhanced CT reveals a 59 × 62 × 85 mm cystic mass with ring-like calcifications, primarily affecting the left ventricular inferior lateral wall and interventricular septum. (e, f) Non-enhanced abdominal CT demonstrates numerous cystic lesions with eggshell-like calcification within the liver and spleen.

CT, computed tomography.

Informed Consent: Informed consent was obtained from the patient for the publication of this report.

Authorship Contributions: Concept- L.K., Supervision- X.M.; Writing- L.K.; Critical Review- X.M.

Conflict of Interest: No conflict of interest was declared by the authors.

Funding: This work is funded by the Wuhan Clinical Medical Research Center for Cardiovascular Imaging (CMRC202307).

REFERENCES

1. Polat P, Kantarci M, Alper F, Suma S, Koruyucu MB, Okur A. Hydatid disease from head to toe. *Radiographics*. 2003;23:475-494, quiz 536-537. [\[CrossRef\]](#)
2. Carità P, Verdecchia M, Ferro G, et al. Multimodality imaging in cardiac echinococcosis for diagnosis and follow-up of an untreatable cyst. *Int J Cardiol*. 2016;221:468-470. [\[CrossRef\]](#)
3. Klug M, Vijan A, Khoshpouri P, Kirshenboim Z. Intracardiac echinococcosis. *Radiographics*. 2023;43:e230041. [\[CrossRef\]](#)
4. Díaz-Menéndez M, Pérez-Molina JA, Norman FF, et al. Management and outcome of cardiac and endovascular cystic echinococcosis. *PLoS Negl Trop Dis*. 2012;6:e1437. [\[CrossRef\]](#)
5. Shams-Ul-Bari; Arif SH, Malik AA, Khaja AR, Dass TA, Naikoo ZA. Role of albendazole in the management of hydatid cyst liver. *Saudi J Gastroenterol*. 2011;17:343-347. [\[CrossRef\]](#)