



Trans-visceral Migration of Retained Gauze: A Rare Cause of Intestinal Obstruction

✉ Slobodan Todorovic^{1,2}, ✉ Nikola Tesic¹, ✉ Filip Lukic³, ✉ Jasna Gacic^{2,4}, ✉ Borislav Toskovic^{1,2}

¹Department of General and Abdominal Surgery, University Hospital Medical Center Bezanijska Kosa, Belgrade, Serbia

²Department of General Surgery, Medical Faculty, University of Belgrade, Belgrade, Serbia

³Department of Radiology, University Hospital Medical Center Bezanijska Kosa, Belgrade, Serbia

⁴Department of Emergency Surgery, University Hospital Medical Center Bezanijska Kosa, Belgrade, Serbia

A 67-year-old man was admitted to our surgical department with a clinical image of intestinal subocclusion. He complained of abdominal pain in association with episodes of nausea and vomiting for the past 2 days. The patient underwent surgery for an abdominal aortic aneurysm 2 years ago.

On clinical examination, abdominal distension and left-sided abdominal tenderness without abdominal guarding were detected. Laboratory tests revealed slightly elevated indicators of inflammation (C-reactive protein: 16.1 mg/l; white blood cells: $22.96 \times 10^9/l$). Plain abdominal radiographs (Figure 1a), ultrasound images, and multidetector computed tomography findings (Figure 1b, c) suggested intestinal obstruction, indicating the need for surgery.

Laparotomic examination revealed that the small intestine was distended to the level of the proximal ileum, where a relatively firm mass was palpated in the intestinal lumen (Figure 1d). A longitudinal enterotomy was performed, and the foreign body was extracted (Figure 1e), which turned out to be a 20×20 cm gauze (Figure 1f). The small intestine was practically unaltered along its entire length, except for a discreet scar observed on its wall near the Treitz ligament. The postoperative course was without any complications, and the patient was discharged on postoperative day 7. Considering the lack of any history suggesting ingestion, a possible explanation for the obstruction was the trans-visceral migration of the retained surgical body. A written informed consent was obtained from the patient for the publication of this study.

A retained surgical body, such as a surgical instrument, sponge, or any other material used during surgery, is an object that is unintentionally left inside the patient's body during a surgical procedure. According to Gawande et al.,¹ surgical sponges are the most commonly retained surgical bodies, accounting for approximately 69% of all such cases,

and 54% of the foreign bodies are reportedly left in the abdomen or pelvis. Several factors that require a reduction in operating time, such as an emergency surgical procedure, unplanned change in the performed procedure, and a high body mass index of the patient, have been identified as contributors to an increased risk of such occurrences, with risk ratios of 1.1, 4.1, and 8.8, respectively.¹

The clinical presentation of retained foreign bodies is variable. In some cases, these retained objects may remain unnoticed for years or even decades before becoming symptomatic.^{2,3} Two types of foreign body reactions are known: acute and chronic. The acute form is characterized by the formation of abscesses, internal fistulas (such as gastric, intestinal, vesical, colonic, and vaginal), or external, cutaneous fistulas (draining through the abdominal wall). In contrast, the chronic form presents as an encapsulated mass often accompanied by non-specific symptoms.⁴

Trans-visceral migration of a retained surgical object is a rare but potentially serious surgical complication. Previous studies have suggested various hypotheses to explain how a foreign body may migrate to the intestinal lumen without inducing any visible damage to the intestinal wall. A foreign body, such as a surgical gauze, induces an inflammatory reaction that leads to the formation of an abscess, which erodes the intestinal wall, leading to perforation and facilitating the migration of the foreign body.⁵ Furthermore, the gauze trapped within the intestine can cause malabsorption, gastrointestinal bleeding, or even intestinal obstruction.⁴

It may be said that the body exhibits a form of "intelligence," striving to eliminate a foreign object by taking the shortest route to the external environment. This may occur through the abdominal wall if it is nearby or through the intestinal lumen if it represents the shortest pathway.

Corresponding author: Slobodan Todorovic, Department of General and Abdominal Surgery, University Hospital Medical Center Bezanijska Kosa; Department of General Surgery, Medical Faculty, University of Belgrade, Belgrade, Serbia

e-mail: bobtod2003@yahoo.com

Received: December 06, 2024 **Accepted:** December 27, 2024 **Available Online Date:** xxxxx • **DOI:** 10.4274/balkanmedj.galenos.2024.2024-12-20

Available at www.balkanmedicaljournal.org

ORCID iDs of the authors: S.T. 0000-0001-5857-227X; N.T. 0009-0002-6623-6262; FL. 0000-0003-1044-8557; J.G. 0000-0002-6219-5881; B.T. 0000-0002-7054-3778.

Cite this article as: Todorovic S, Tesic N, Lukic F, Gacic J, Toskovic B. Trans-visceral Migration of Retained Gauze: A Rare Cause of Intestinal Obstruction. *Balkan Med J*;

Copyright@Author(s) - Available online at <http://balkanmedicaljournal.org/>

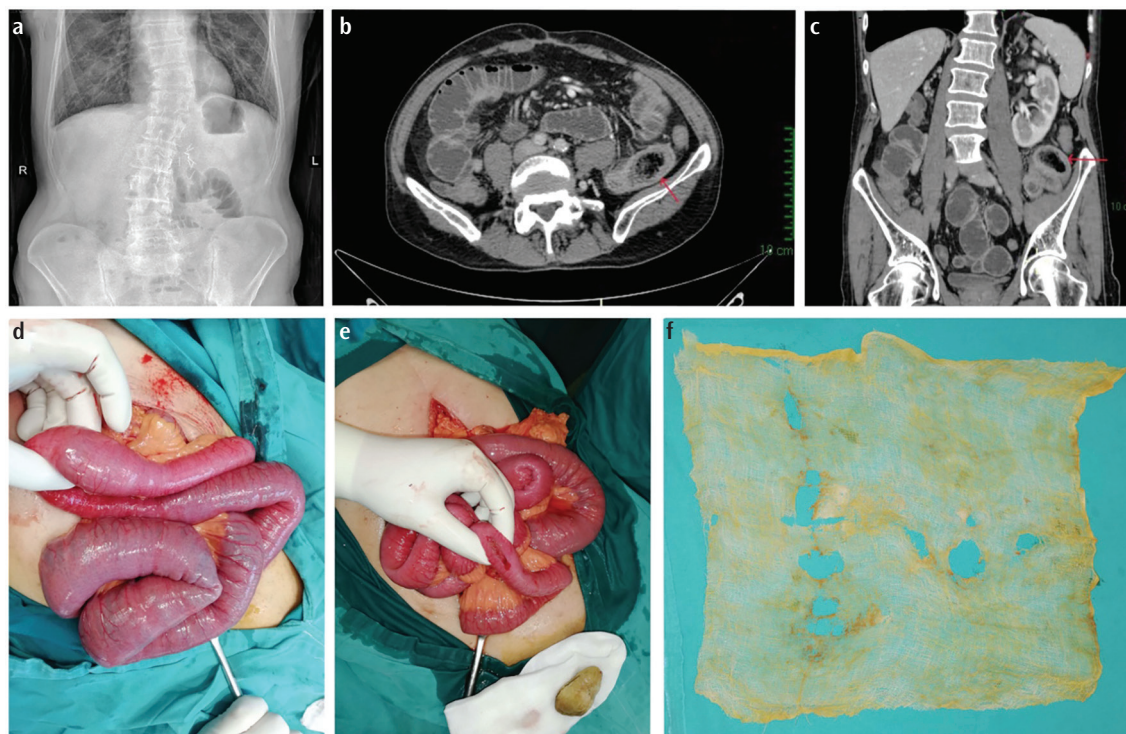


FIG. 1. (a) Plain abdominal radiograph. (b) Abdominal CT findings, transverse view. (c) Abdominal CT findings, sagittal view. (d) Intraoperative finding. (e) Longitudinal enterotomy. (f) Surgical gauze 20 × 20 cm. CT, computed tomography.

Despite being theoretically preventable, the incidence of retained surgical foreign bodies remains approximately 0.3-1.0 per 1,000 abdominal operations. Reports of retained surgical objects are important to discuss as they can potentially lead to medico-legal consequences for healthcare professionals, hospitals, and health systems, which is likely the reason for the lower number of reported cases in the literature.^{6,7} Standardized counting protocols are widely used to minimize the risks associated with retained surgical bodies. However, the identification and prevention of retained surgical items remains challenging because of various factors.^{8,9} Nonetheless, it remains essential to be aware of the possibility of trans-visceral migration of a foreign body as a potential cause of complications in patients who have undergone surgical procedures.

Informed Consent: A written informed consent was obtained from the patient for the publication of this study.

Authorship Contributions: Concept- S.T.; Design- S.T., B.T.; Supervision- J.G., B.T.; Data Collection and/or Processing- N.T., F.L.; Literature Search- N.T.; Writing- S.T., N.T.; Critical Review- F.L., J.G., B.T.

Conflict of Interest: No conflict of interest was declared by the authors.

REFERENCES

- Gawande AA, Studdert DM, Orav EJ, Brennan TA, Zinner MJ. Risk factors for retained instruments and sponges after surgery. *N Engl J Med.* 2003;348:229-235. [\[CrossRef\]](#)
- D'Amico A, Perillo T, Ugga L, Cuocolo R, Brunetti A. Intruding implements: a pictorial review of retained surgical foreign objects in neuroradiology. *Insights Imaging.* 2019;10:124. [\[CrossRef\]](#)
- Birolini DV, Rasslan S, Utiyama EM. Unintentionally retained foreign bodies after surgical procedures. Analysis of 4547 cases. *Rev Col Bras Cir.* 2016;43:12-17. [\[CrossRef\]](#)
- de Sousa JB, Alves Martins BA, Rocha Ferreira IA, E Silva SM, de Oliveira PG. Transmural Migration of gossypiboma with intraluminal small-bowel obstruction: a case report. *Am J Case Rep.* 2020;21:e924506-1. [\[CrossRef\]](#)
- Grassi N, Cipolla C, Torcivia A, et al. Trans-visceral migration of retained surgical gauze as a cause of intestinal obstruction: a case report. *J Med Case Rep.* 2008;2:17. [\[CrossRef\]](#)
- Stawicki SP, Evans DC, Cipolla J, et al. Retained surgical foreign bodies: a comprehensive review of risks and preventive strategies. *Scand J Surg.* 2009;98:8-17. [\[CrossRef\]](#)
- Weprin S, Crocerozza F, Meyer D, et al. Risk factors and preventive strategies for unintentionally retained surgical sharps: a systematic review. *Patient Saf Surg.* 2021;15:24. [\[CrossRef\]](#)
- Cobb TG. Iatrogenic retention of surgical objects: risk factors and prevention strategies. *JAAPA.* 2010;23:33-34, 39-40. [\[CrossRef\]](#)
- Institute of Medicine (US) Committee on Quality of Health Care in America. To err is human: building a safer health system. Kohn LT, Corrigan JM, Donaldson MS, editors. Washington (DC): *National Academies Press (US)*; 2000. [\[CrossRef\]](#)