



# Effective Management of Buried Bumper Syndrome with the Balloon Dilatation Pull Technique

✉ Sónia Barros, ✉ Margarida Portugal, ✉ Luís Miguel Relvas, ✉ Ana Margarida Vaz, ✉ Bruno Peixe

Department of Gastroenterology, Unidade de Saúde Local do Algarve - Unidade de Faro, Faro, Portugal

Buried bumper syndrome (BBS) refers to the internal migration of the bumper into the gastric or abdominal wall, a potential complication of percutaneous endoscopic gastrostomy (PEG) placement. Management typically requires endoscopic intervention, with various techniques reported, including dissection methods and the use of innovative devices.<sup>1-3</sup>

This report describes a case where the balloon dilatation pull (BDP) technique was employed to resolve BBS, emphasizing the practical use and potential benefits of balloon-assisted management in treating this condition.

A 73-year-old female with a history of meningioma surgery in 2023 developed left laryngopharyngeal paralysis and dysphagia as postoperative complications. To address her nutritional needs, a PEG tube was inserted. With follow-up physiotherapy, her dysphagia improved significantly, enabling the reintroduction of oral nutrition. Six months post-PEG placement, the multidisciplinary team opted to remove the PEG tube due to her progress. However, the removal procedure was challenging due to difficulty in mobilizing the tube. Upper endoscopy revealed the absence of the internal bumper in the gastric lumen, raising suspicion of BBS, which was confirmed by abdominal computed tomography (Figure 1a).

The patient was admitted to the gastroenterology ward for planning the removal of the PEG tube. An endoscopic approach using the BDP technique was selected. During endoscopy, a protrusion on the anterior wall of the antrum was observed, consistent with BBS (Figure 1b). The PEG tube was cut 2 cm above the skin and clamped. A guidewire was inserted into the gastric lumen (Figure 1c) and retrieved through the mouth using a polypectomy snare.

A through-the-scope balloon was then advanced over the guidewire and inflated to 18 mm inside the PEG tube (Figure 1d). Continuous traction successfully mobilized the internal bumper into the gastric lumen and subsequently out through the mouth.

The patient was monitored during hospitalization. On the second day, a soft diet was initiated without complications, and she was discharged on the third day.

The BDP technique is a safe and effective method for managing BBS, employing commonly available endoscopic accessories.<sup>2,4</sup> Compared with alternative approaches, such as dissection-based methods or surgical removal, the BDP technique is less invasive, more cost-effective, and faster to perform.<sup>4</sup> Unlike needle-knife dissection, which carries risks such as bleeding or perforation,<sup>1</sup> and surgical removal, which is associated with increased morbidity,<sup>3</sup> the BDP technique reduces complications and promotes faster recovery.

In this case, the BDP technique successfully removed the buried bumper without complications, enabling the patient to resume oral intake within 2 days and be discharged on the third day. These results underscore its practicality, especially for patients with significant comorbidities where more invasive approaches may not be appropriate.<sup>2,4</sup>

However, the BDP technique may have limitations in cases involving significant fibrosis or deeply embedded bumpers, where surgical or dissection-based methods might be necessary.<sup>1</sup> Further research comparing the long-term efficacy and safety of the BDP technique with alternative approaches is essential to establish its role in a standardized management strategy for BBS.

**Corresponding author:** Sónia Barros, Department of Gastroenterology, Unidade de Saúde Local do Algarve - Unidade de Faro, Faro, Portugal

**e-mail:** soniaisb@hotmail.com

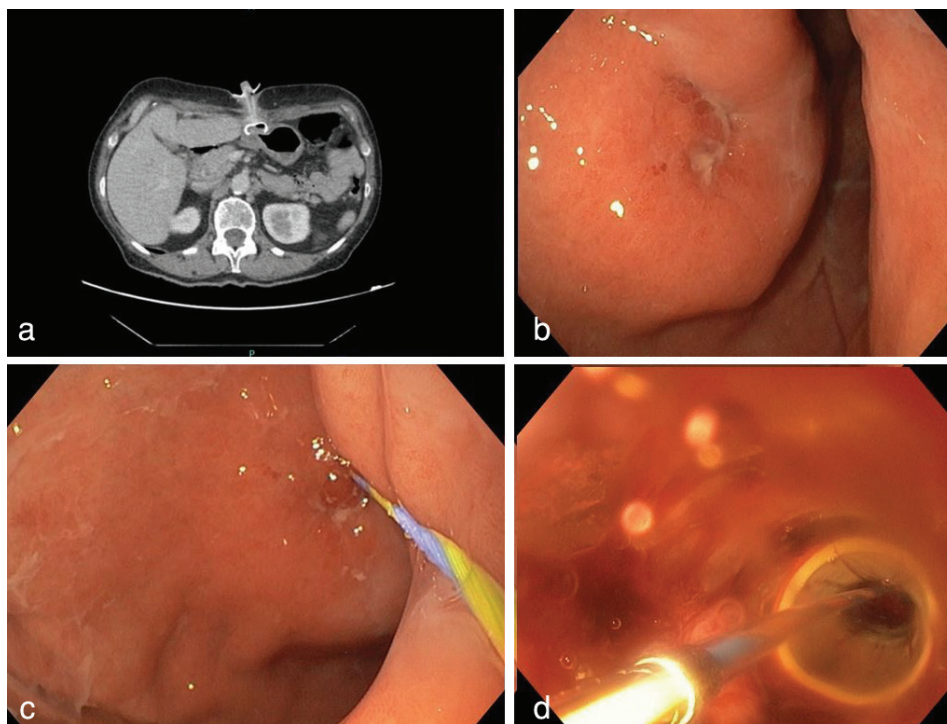
**Received:** October 25, 2024 **Accepted:** December 27, 2024 **Available Online Date:** xxxxxx • **DOI:** 10.4274/balkanmedj.galenos.2024.2024-9-53

Available at [www.balkanmedicaljournal.org](http://www.balkanmedicaljournal.org)

**ORCID iDs of the authors:** S.B. 0009-0003-1688-3354; M.P. 0000-0001-8212-1727; L.M.R. 0000-0002-0231-5837; A.M.V. 0009-0008-7091-7478; B.P. 0000-0002-6881-0216.

**Cite this article as:** Barros S, Portugal M, Relvas LM, na Vaz AM, Peixe B. Effective Management of Buried Bumper Syndrome with the Balloon Dilatation Pull Technique. *Balkan Med J*;

Copyright@Author(s) - Available online at <http://balkanmedicaljournal.org/>



**FIG. 1.** (a) Axial computed tomography scan showing the internal bumper of the PEG tube embedded in the anterior wall of the gastric antrum, with no evidence of an intraluminal component. (b) Endoscopic view revealing a protrusion on the anterior wall of the antrum, indicative of BBS. (c) Endoscopic image showing the insertion of a guidewire into the gastric lumen, which was subsequently retrieved through the mouth using a polypectomy snare. (d) Endoscopic image depicting the TTS balloon advanced over the guidewire and inflated to 18 mm inside the PEG tube.

PEG, percutaneous endoscopic gastrostomy; BBS, buried bumper syndrome; TTS, through-the-scope.

**Informed Consent:** Written informed consent was obtained from the patient for the publication of this clinical image and accompanying details.

**Authorship Contributions:** Literature Search- S.B.; Writing- S.B., M.P., L.M.R.; Critical Review- A.M.V., B.P.

**Conflict of Interest:** No conflict of interest was declared by the authors.

## REFERENCES

1. Satiya J, Marcus A. The Buried bumper syndrome: a catastrophic complication of percutaneous endoscopic gastrostomy. *Cureus*. 2019;11:e4330. [\[CrossRef\]](#)
2. Kitchin A, Matull WR, Pearl D. Buried bumper syndrome: improving patient outcomes using a structured multidisciplinary team (MDT) approach to management. *Frontline Gastroenterol*. 2022;13:503-508. [\[CrossRef\]](#)
3. Carter-Stephens R. Buried bumper syndrome: prevention and management in the community. *Br J Community Nurs*. 2021;26:428-432. [\[CrossRef\]](#)
4. Maly M, Bronswijk M, Christiaens P, Snauwaert C. Endoscopic management of buried bumper syndrome using the Balloon Dilation Pull (BDP) technique: a multicenter analysis. *Acta Gastroenterol Belg*. 2023;86:5-9. [\[CrossRef\]](#)